

**DIRUI**

FUS Series

# ATLAS

of Urine Formed Elements

**Great thanks to RNDr. Miroslava Beňovská, Ph.D., Mgr. Ondřej Wiewior  
ka, MUDr. Jana Tůmová and the technician team in Department of Clinical  
Biochemistry, University Hospital Brno, Czech Republic, who contrib  
uted their professional knowledge, support and hardwork in the accom  
plishment of the FUS Series Atlas of Urine Formed Elements.**

# Contents

<b>Introduction</b>	<b>3</b>		
<b>Erythrocytes</b>	<b>4</b>		
Normal RBCs			
Big RBCs			
Acanthocytes			
Tear Drop RBCs (Dacryocytes)			
Codocytes			
Crescent RBCs			
Nucleated RBCs			
Crenated RBCs			
<b>Leucocytes</b>	<b>27</b>		
Neutrophils			
WBCCs			
Lymphocytes			
Monocytes			
Other WBCs			
<i>WBC with spilled cytoplasm</i>			
<i>Pseudopodium WBCs</i>			
Rod-shaped WBCs			
Phagocytes			
WBC including fat			
<b>Epithelial cells</b>	<b>44</b>		
Squamous Epithelial cells			
Transitional Epithelial cells			
<i>Big round epithelial cells</i>			
<i>Caudate epithelial cells</i>			
<i>Small round epithelial cells</i>			
<i>Transitional epithelial cells with two nuclei</i>			
Renal epithelial cells			
<i>Renal tubular epithelial cells</i>			
<i>Oval fat bodies</i>			
<b>Casts</b>	<b>62</b>		
Hyaline casts			
Cell casts			
<i>RBC casts</i>			
<i>WBC casts</i>			
<i>RBC+WBC casts</i>			
<i>Renal epithelial cell casts</i>			
<i>Mixed cells casts</i>			
Waxy casts			
		Granular casts	
		Fatty casts	
		Renal failure casts (Broad casts)	
		Bacterial casts	
		Nested casts	
		<b>Crystals</b>	<b>93</b>
		Calcium oxalates crystals	
		Uric acid crystals	
		Amorphous urates crystals	
		Phosphate crystals	
		Calcium phosphate crystals	
		<i>Triple phosphate crystals</i>	
		<i>Amorphous phosphate crystals</i>	
		Ammonium urates crystals	
		Bilirubin crystals	
		Cystine crystals	
		Leucine crystals	
		Tyrosine crystals	
		Cholesterol crystals	
		<b>Bacteria</b>	<b>132</b>
		<b>Yeasts</b>	<b>137</b>
		<b>Trichomonads</b>	<b>143</b>
		<b>Mucus</b>	<b>145</b>
		<b>Sperms</b>	<b>148</b>
		<b>Fat droplets</b>	<b>151</b>
		<b>Starch bodies</b>	<b>154</b>
		<b>Artifacts</b>	<b>156</b>
		Artificial oil	
		Pollen	
		<b>Case Studies</b>	<b>161</b>
		The finding of fat particles in patients with nephritic syndrome	
		The gradual transformation of pathological casts	
		<b>Company profile</b>	<b>166</b>
		<b>Urinalysis products</b>	<b>167</b>

# Introduction

Urine formed elements analysis is one of the basic and traditional examinations. It is an indispensable part of routine urine analysis and an important one in clinical testing, especially for the diagnosis, treatment and prognosis of renal system diseases.

Due to the large number of formed elements that have features of various shapes and which are easy to destroy or to change morphology, rich experience is required to do the analysis. For quite a long time, microscopic examination is the main method. In recent years, due to the continuous and rapid development of computer technology, digital image technology and intelligent identification technology, the automation and standardization of automatic formed elements analyzers have been continuously improved and promoted. Nowadays in most developed countries and more and more developing countries, the analysis of urine is mostly automated. Manual microscopy is used only for determination of ambiguous or discrepant results.

This manual is intended to help the end users to get familiar with pictures captured by DIRUI FUS series analyzers and their differences compared with microscopic pictures. It can be used as a dictionary to assist customers to become an expert in FUS series analyzers and reduce the microscopic review rate. This manual could also be practical as a reference book in clinical examination of urine formed elements.

In this database, we have described the significances of various formed elements and sorted 4 variants of pictures for each formed element.

1. Isolated pictures from automatic FUS-2000 analyzer (DIRUI)
2. Microscopic findings of native sediment (10× concentrated urine sample in 400×magnification)
3. Big pictures from automatic FUS-2000 analyzer (DIRUI)
4. Microscopic findings of stained sediment (10×concentratedurine sample with 400×magnification, Sternheimer staining)

The urine sediment for manual microscopy is prepared as follows: native urine sample is centrifuged in 2000 rpm and the supernatant is removed and the sediment re-suspended to create a tenfold concentrated sample solution.

We use standardized staining (e.g. supravital staining) by Sternheimer for better recognition of elements. Staining reagent consists of 2 dyes (alcian blue and red pyronin B in 1:1 ratio). The staining reagent is added to the concentrated urine sample in 1:10 ratio.

Major samples of this manual are outpatient and inpatient samples from University Hospital Brno and a minority from internet. In order to guarantee the consistency of the pictures, mostly each type of formed elements come from the same sample.

Thanks for all the supports and helps from friends in University Hospital Brno RNDr. Miroslava Benovska, PhD,Mgr. Ondrej Wiewiorka and Mgr. Jana Pinkavová. Thanks for all the hard work from DIRUI colleagues of Marketing Dept and R&D Dept.



# Erythrocytes

Erythrocytes are red blood cells (RBC) without nucleus, with size of about 6-7 $\mu$ m, biconcave shape and of light yellow color appearance in the microscopic field. The morphology of RBCs in urine is affected by multiple factors including osmotic pressure, pH, time in vitro, etc.

Abnormal forms	Features
Big RBCs	Diameter >7 $\mu$ m
Small RBCs	Diameter <6 $\mu$ m with various sizes
Acanthocytes	Cytoplasm often reaches out to one or more sides so that membrane protrudes like budding.
Crenated RBCs	The cells are shrunk in hypertonic urine and form many protrusions on the surface and have similar size.
Shadow RBCs	Loss of hemoglobin from cells or cytoplasm condensing to the membrane to form a ring (hypotonic urine).
Crescent RBCs	Cells are shaped like a half-moon or a sickle.
Granular RBCs	Granular formation in the cytoplasm and loss of hemoglobin.
RBC fragments	Broken and incomplete RBCs.

RBC morphology in fresh urine signals glomerular and non-glomerular origin of hematuria. RBCs concentration should be paid attention as well. For example, when no red color is visible by naked eye and centrifuged urine contains more than 3/HP RBCs under microscope, it is called microscopic hematuria. Hematuria can be divided into three types.

1, Uniform RBCs hematuria: it is mostly non-glomerular hematuria. Most of the RBCs (more than 70%) are normal, or in single form, meaning they have concave disk-shape and cell membrane with integrity. Shadow RBCs or acanthocytes are seen occasionally, but not more than 2 kinds of aberrant forms are present. It is mainly seen in case of bleeding in the lower part of the glomerular and urinary tract due to capillary rupture. RBCs are not compressed by the glomerular basement membrane, so they have normal morphology. RBCs from kidney tubules are affected by pH and osmotic pressure changes but only for a short time so slight changes are made. The RBCs are also in uniformity.

Based on the cause of the hemorrhage, RBC uniformity hematuria can be classified into four types:

- a) Transient microscopic hematuria: found in healthy people, especially in the youth with vigorous exercise, rapid march, and cold water bath or after long standing or hard physical

labor. For female patients, menstrual blood pollution should be ruled out by dynamic observation.

- b) Urinary system diseases: urinary tract inflammation, cancer, tuberculosis, calculi, trauma, kidney transplant rejection, and congenital deformities. Hematuria is sometimes the only clinical manifestation of malignant tumors of the urinary system.
- c) Reproductive system diseases: prostatitis, vesiculitis, etc.
- d) Hemorrhagic disease caused by various reasons.

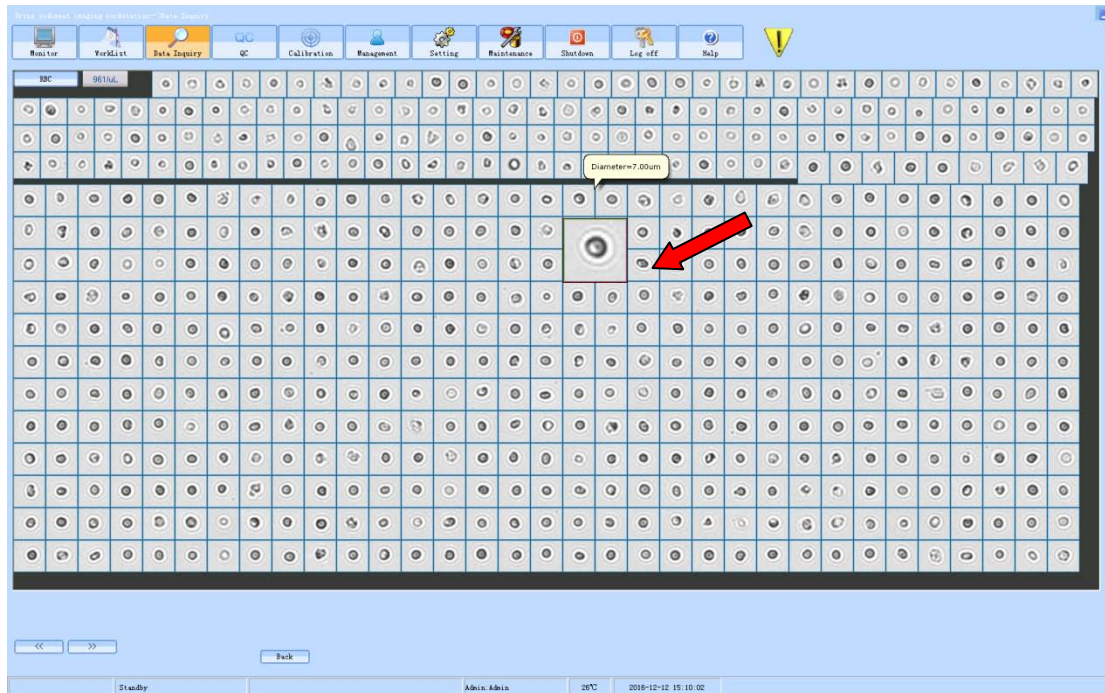
2, Non-uniform RBCs hematuria: it is mostly glomerular hematuria (deformation RBCs hematuria). Abnormal RBCs in urine (more than 70%) are of 2 or more types. There are changes in sizes, shape and hemoglobin distribution and content in RBCs. RBC sizes can differ 3-,4-fold, with big RBCs, small RBCs, acanthocytes (most pathological), crenated RBCs, shadow RBCs, half moon-shaped RBCs, granular RBCs. They have different hemoglobin content.

Non-uniform RBC hematuria is caused by following factors:


- a) Pathological changes in glomerular basement membrane (cause crushed RBCs).
- b) Different parts of the renal tubules have changed pH, osmotic pressure, media pressure, metabolites (such as fatty acids, phosphatidylcholine, bile acid, etc) affecting RBCs. It is often accompanied by increase in urinary protein, granular casts, RBC casts, renal tubular epithelial cells and so on. It is seen in acute or chronic renal tubular nephritis, lupus nephritis, chronic pyelonephritis, nephrotic syndrome, etc.

3. Mixed hematuria: both uniform and non-uniform RBCs are present in urine. Either type of RBCs is 30 to 70%. It suggests that bleeding may not originate from single location; both glomerular and non-glomerular originated RBCs can be present. Not many diseases can cause mixed hematuria. IgA nephrotic tops the list.

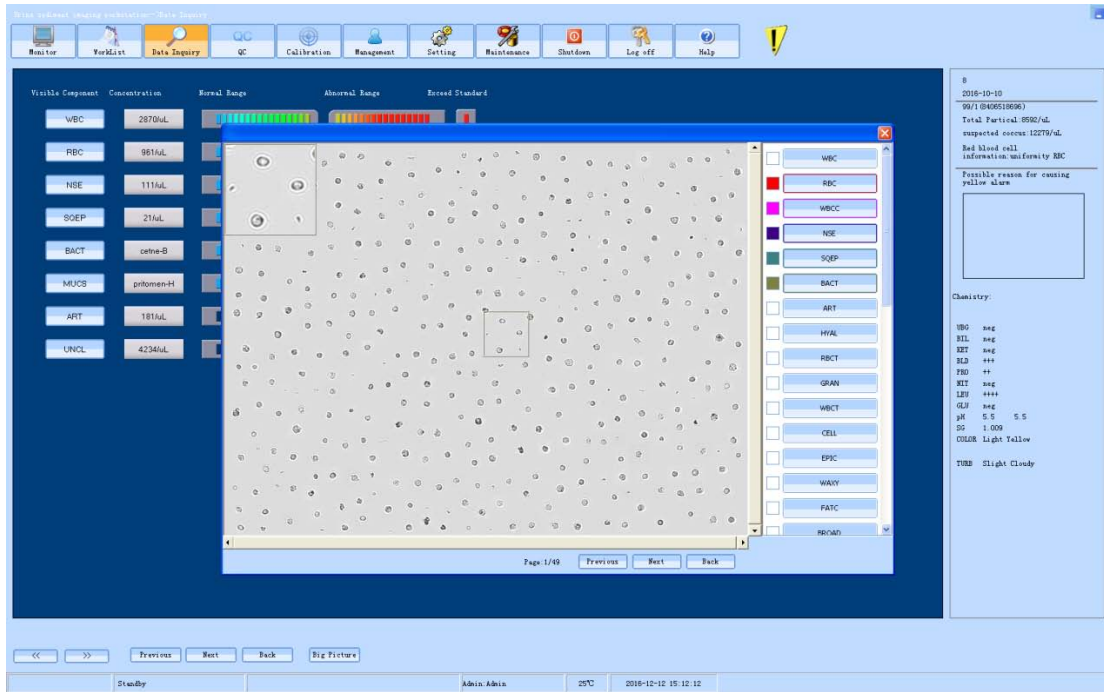
## Normal RBCs



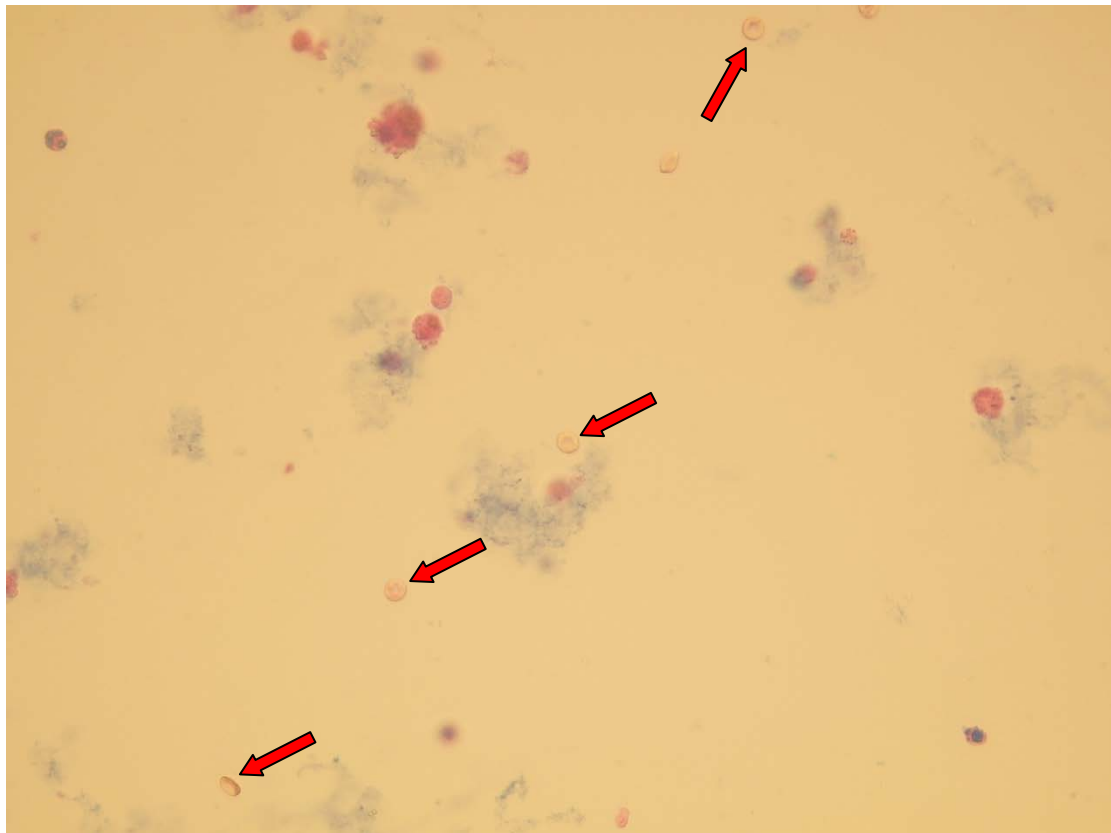
**Normal RBCs-FUS-2000 isolated picture**



**Normal RBCs-Microscopic picture of native sediment**

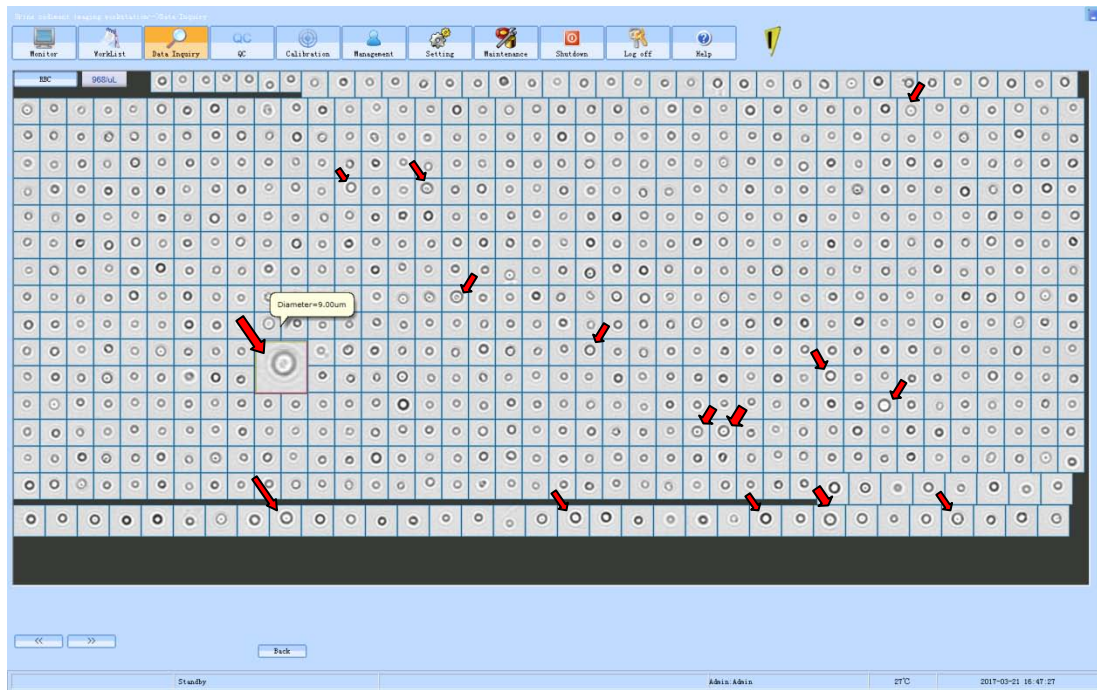


**Normal RBCs-FUS-2000 big picture**

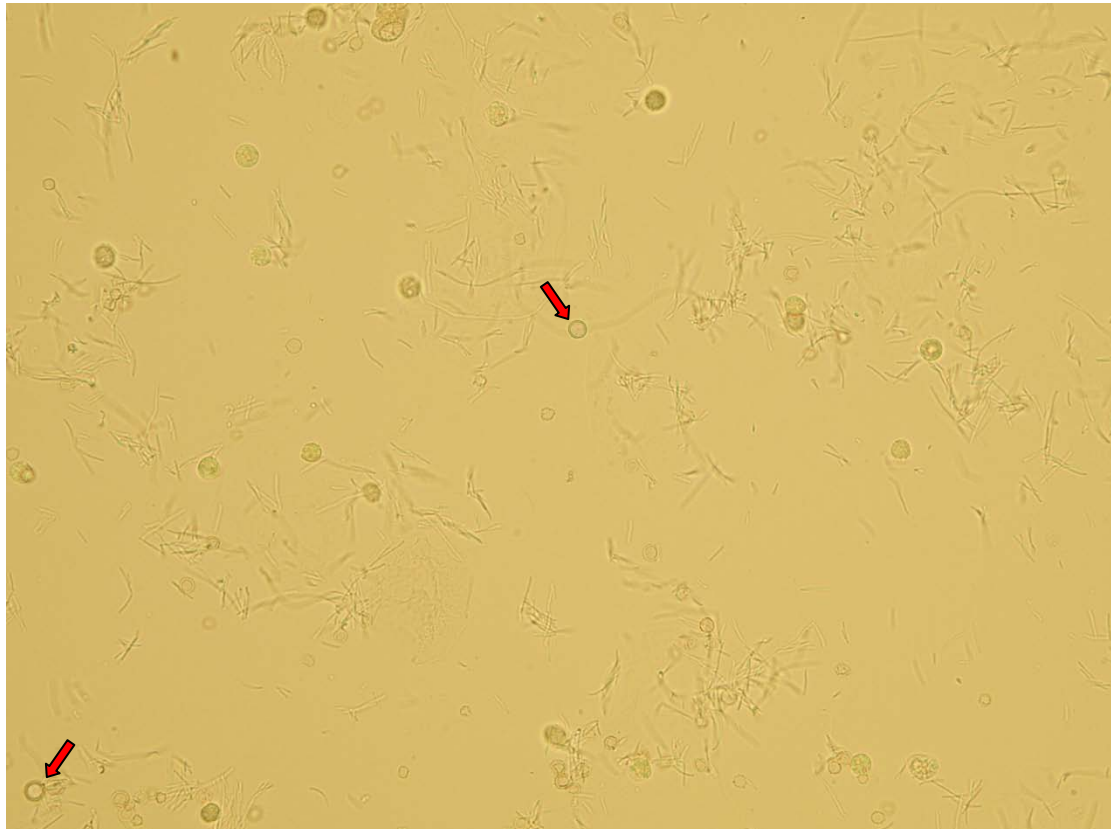


**Normal RBCs-Microscopic picture of stained sediment**

## Big RBCs

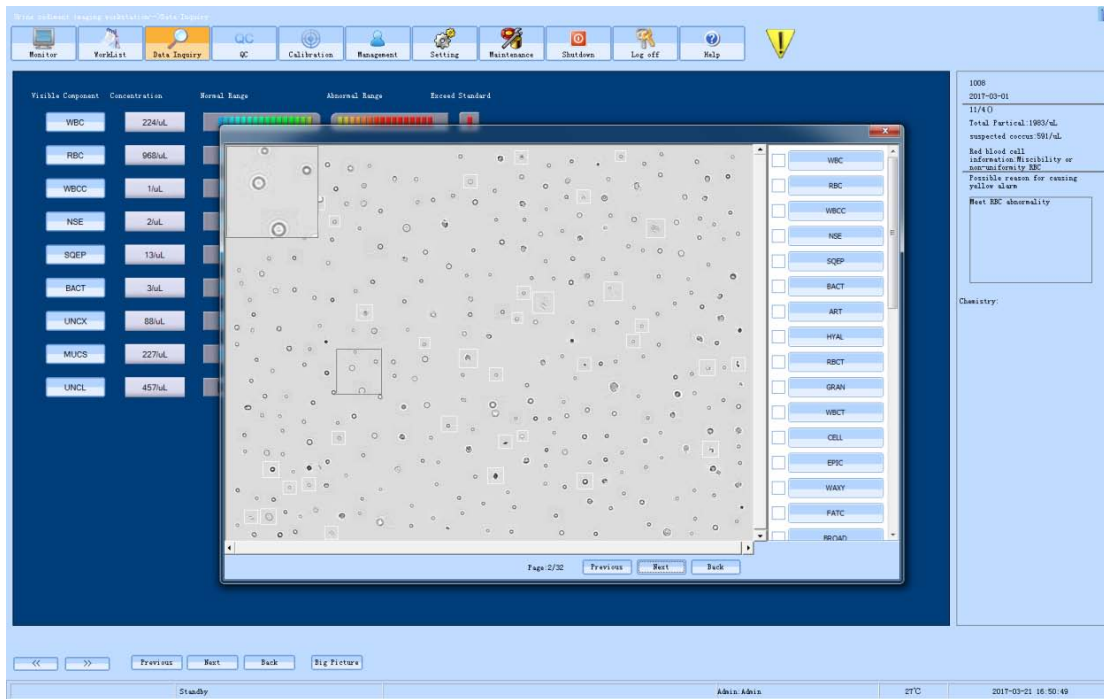


**Big RBCs-FUS-2000 isolated picture**

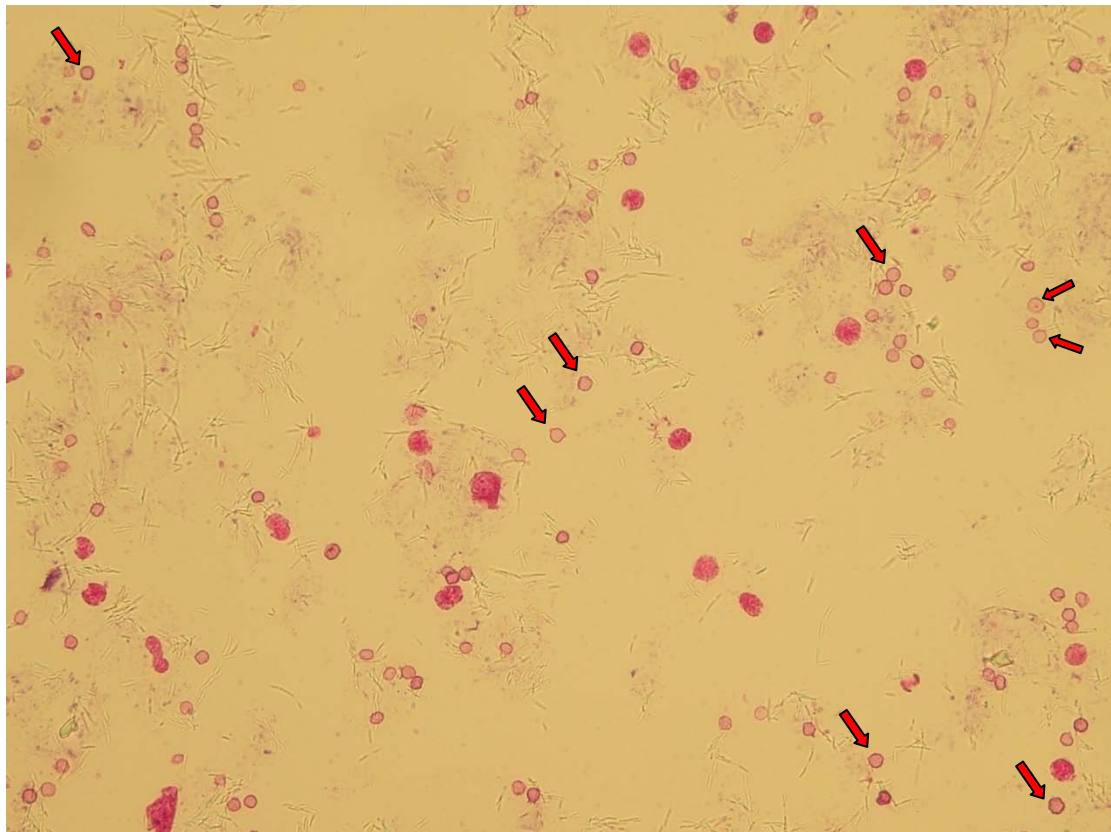


**Big RBCs-Microscopic picture of native sediment**



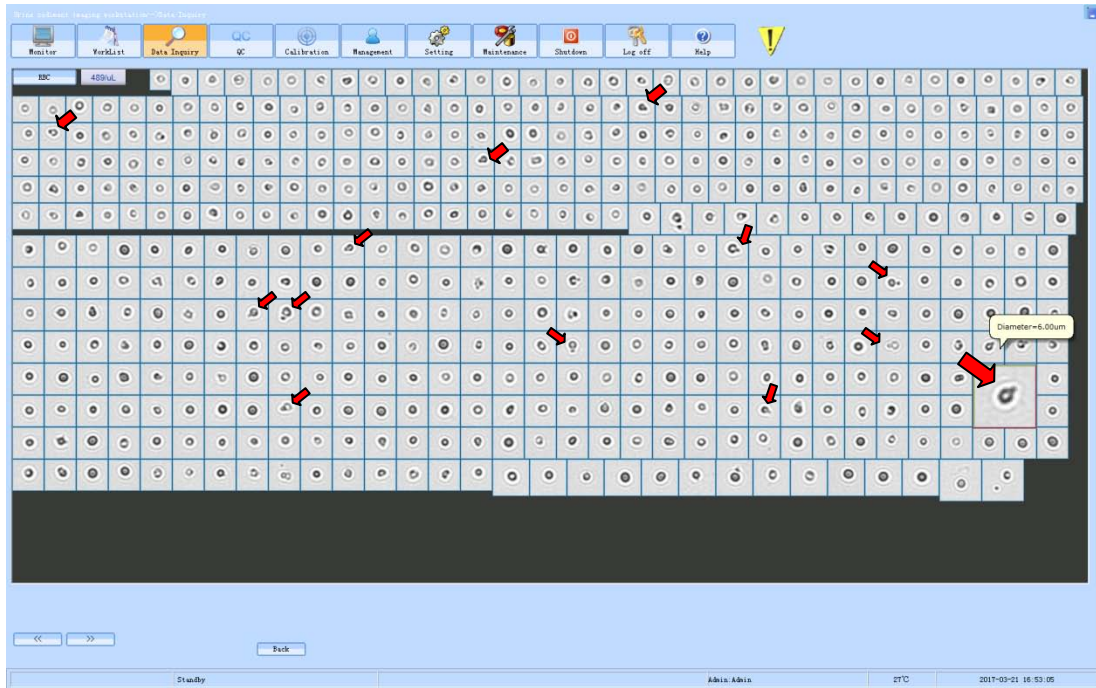


**Big RBCs-FUS-2000 big picture**




**Big RBCs-Microscopic picture of stained sediment**

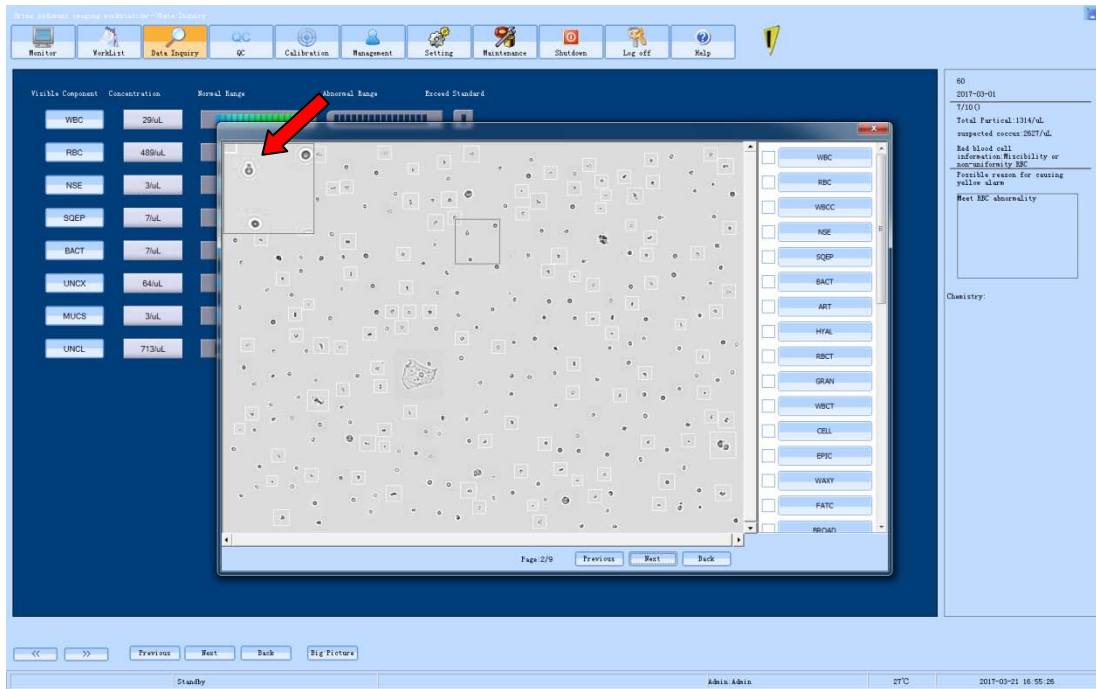
# Acanthocytes



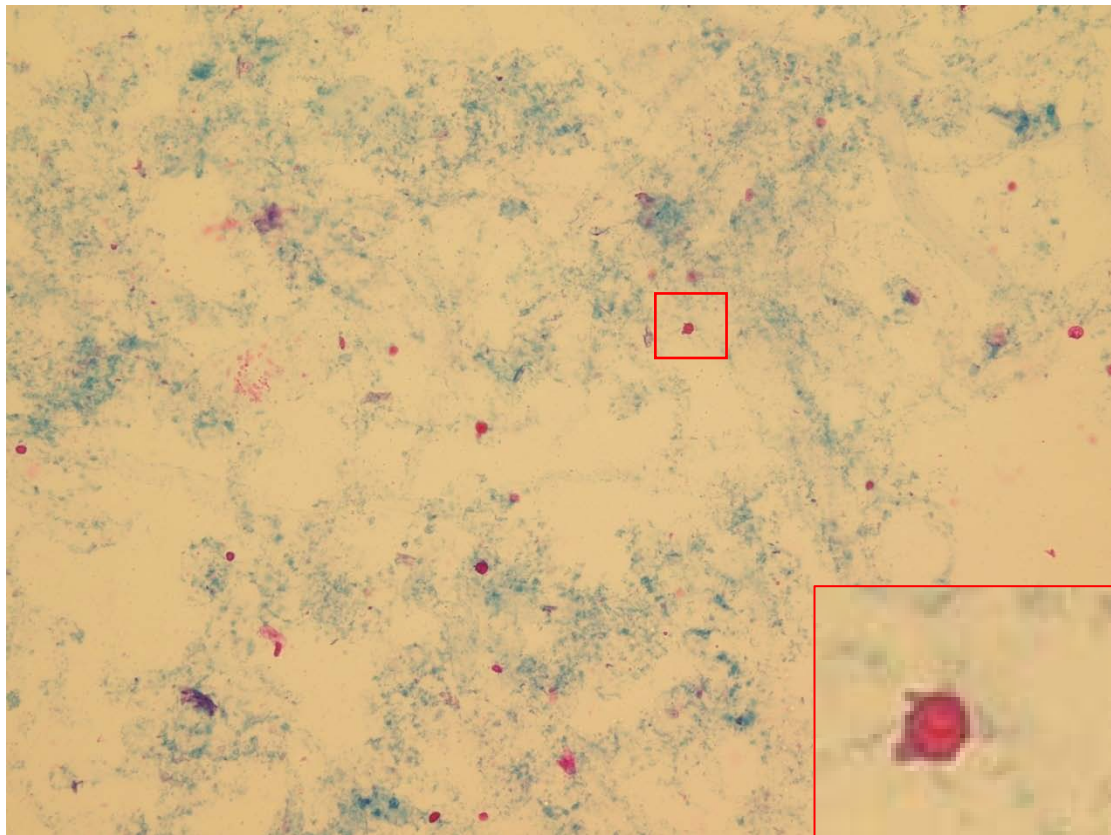
**Acanthocytes-FUS-2000 isolated picture**



**Acanthocytes-Microscopic picture of native sediment**



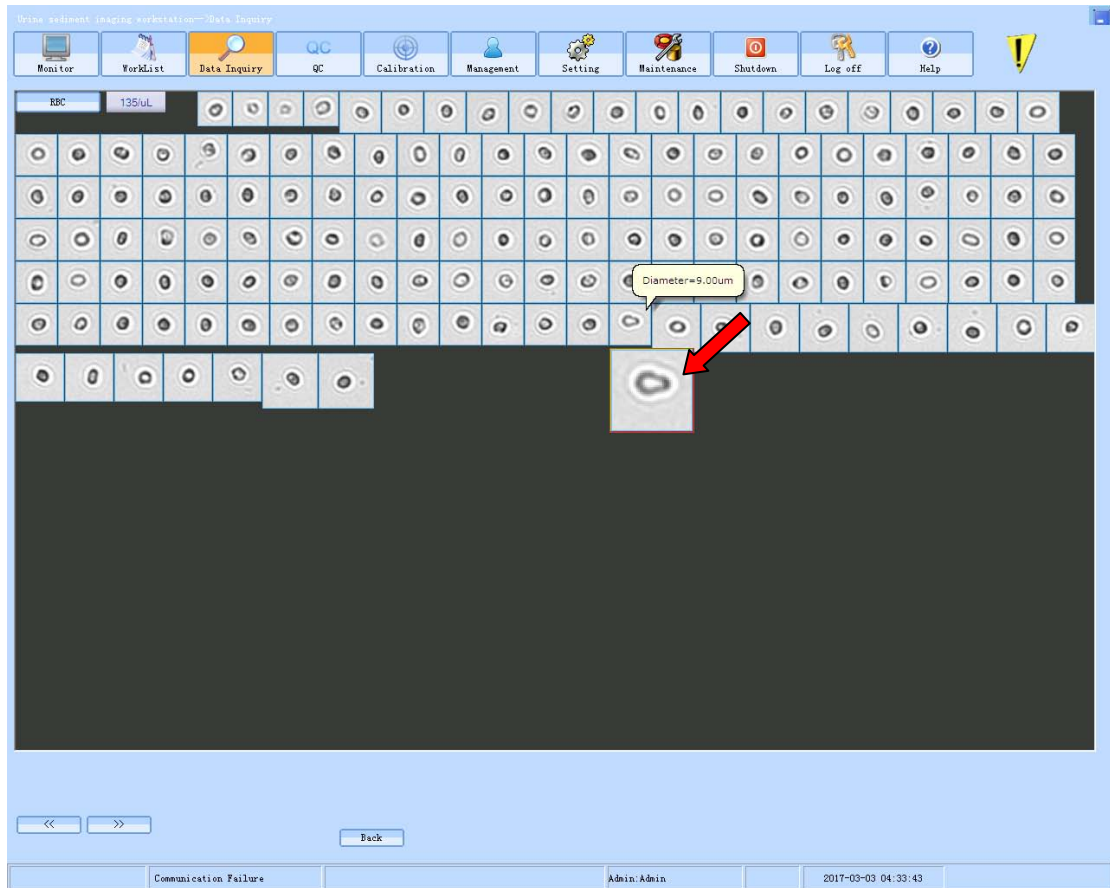
**Acanthocytes-FUS-2000 big picture**



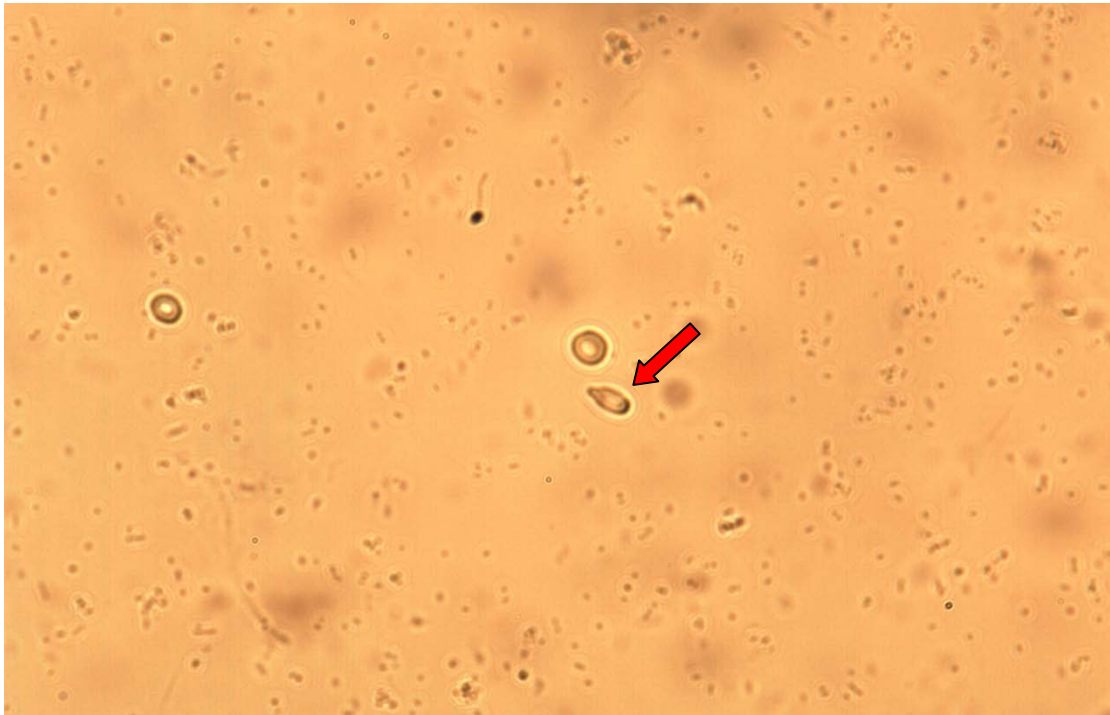
**Acanthocytes-Microscopic picture of stained sediment**



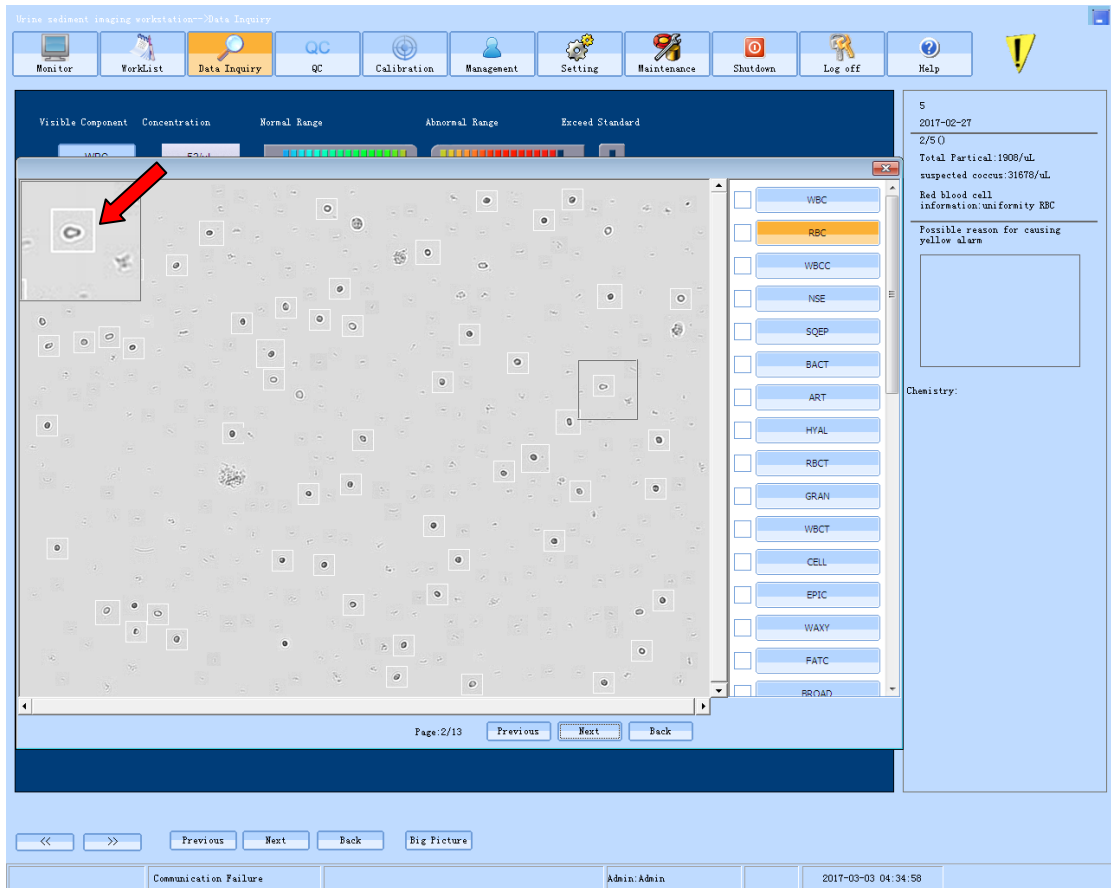
## Tear Drop RBCs = Dacryocytes



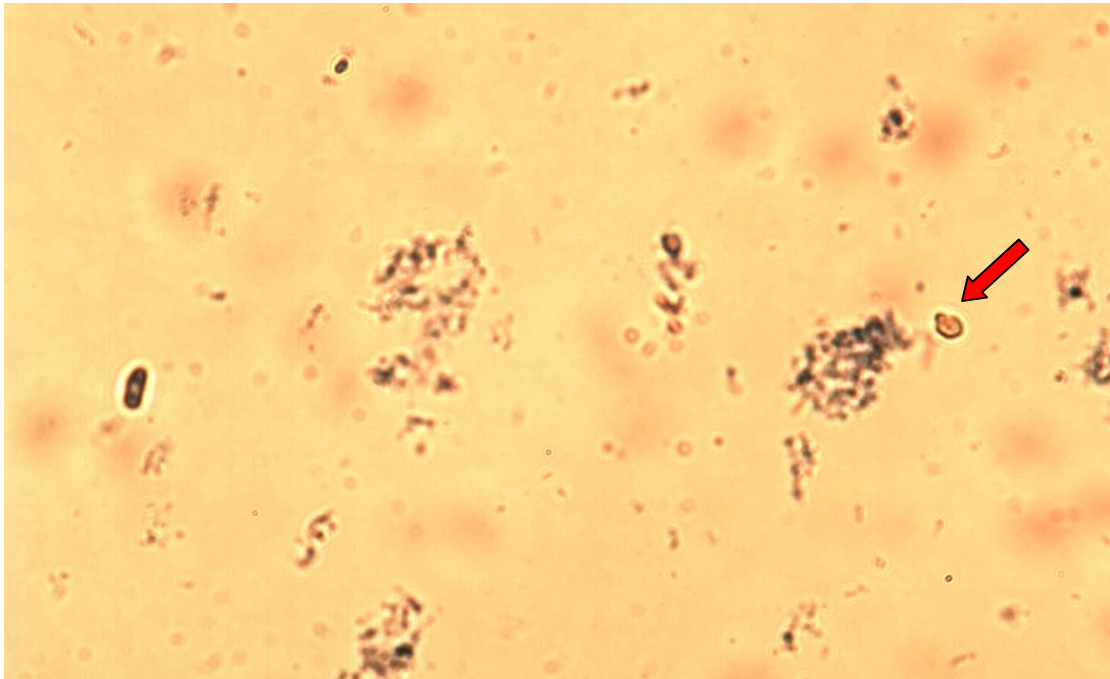
**Dacryocytes-FUS-2000 isolated picture**



**Dacryocytes-Microscopic picture of native sediment**

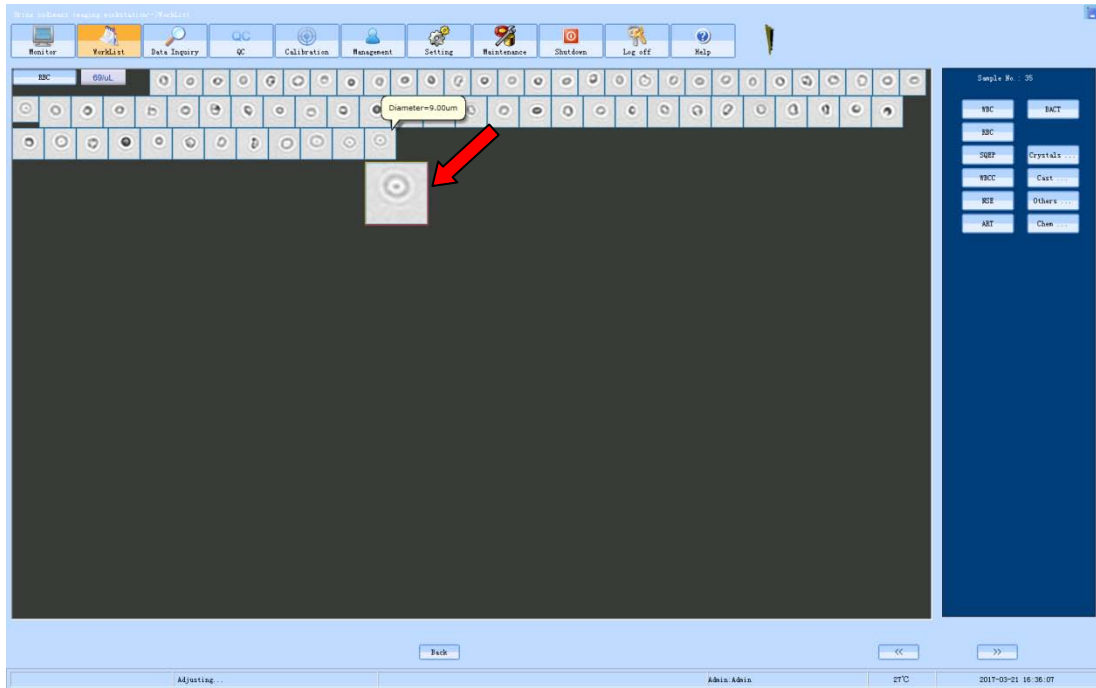


**Dacryocytes-FUS-2000 big picture**

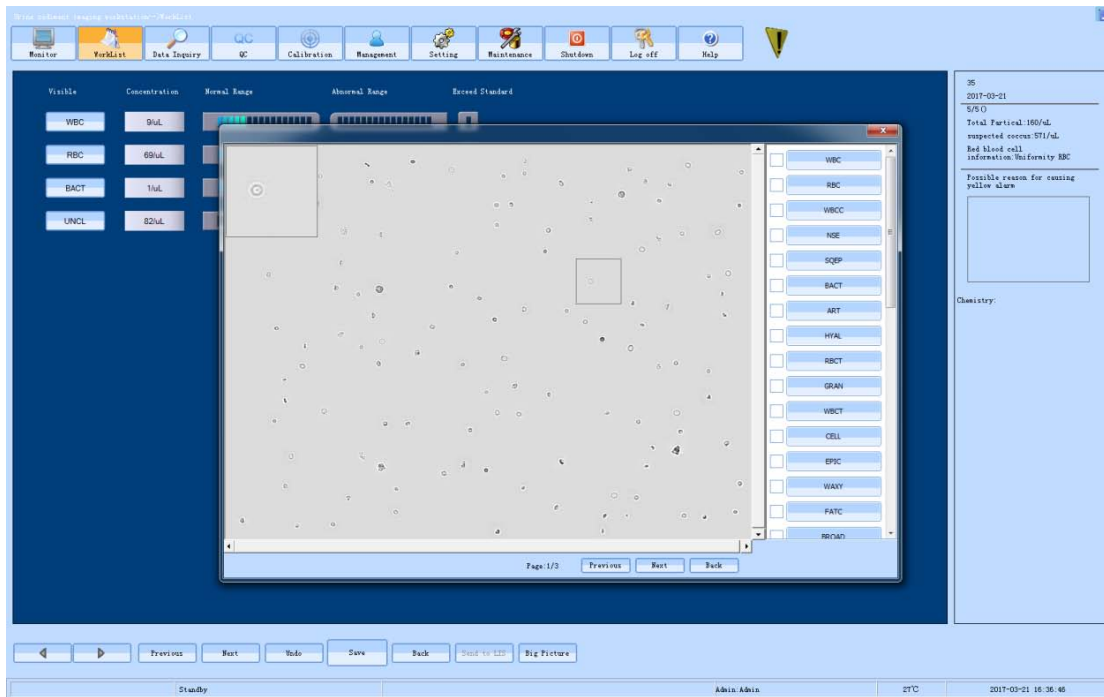


**Dacryocytes-Microscopic picture of stained sediment**

# Codocytes

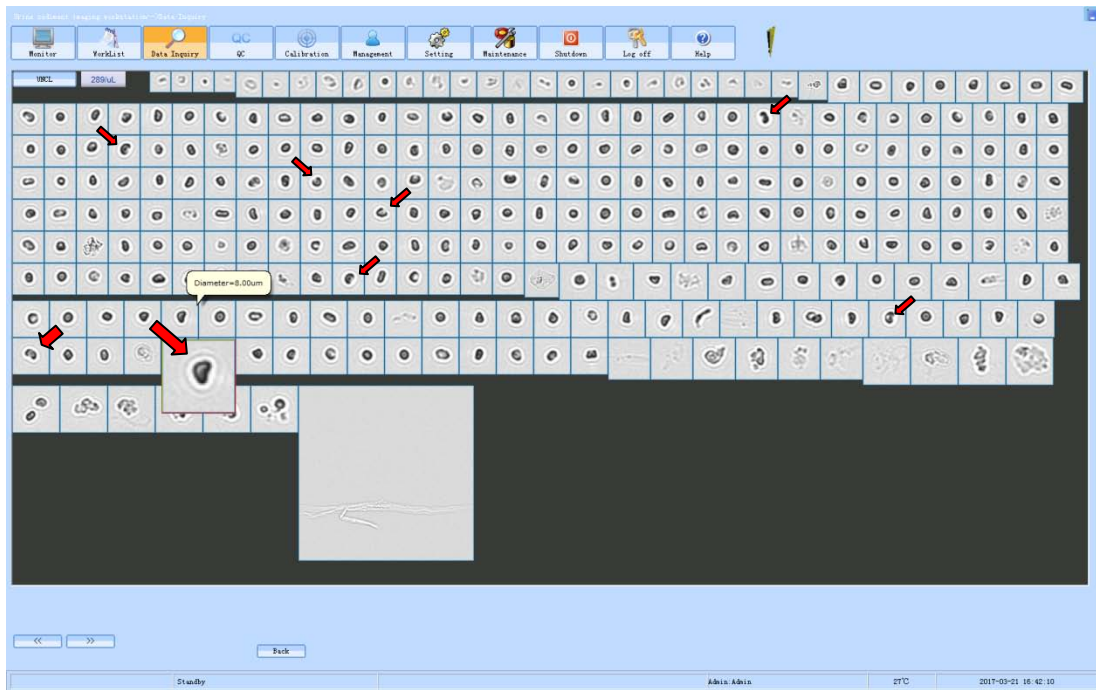


**Codocytes-FUS-2000 isolated picture**

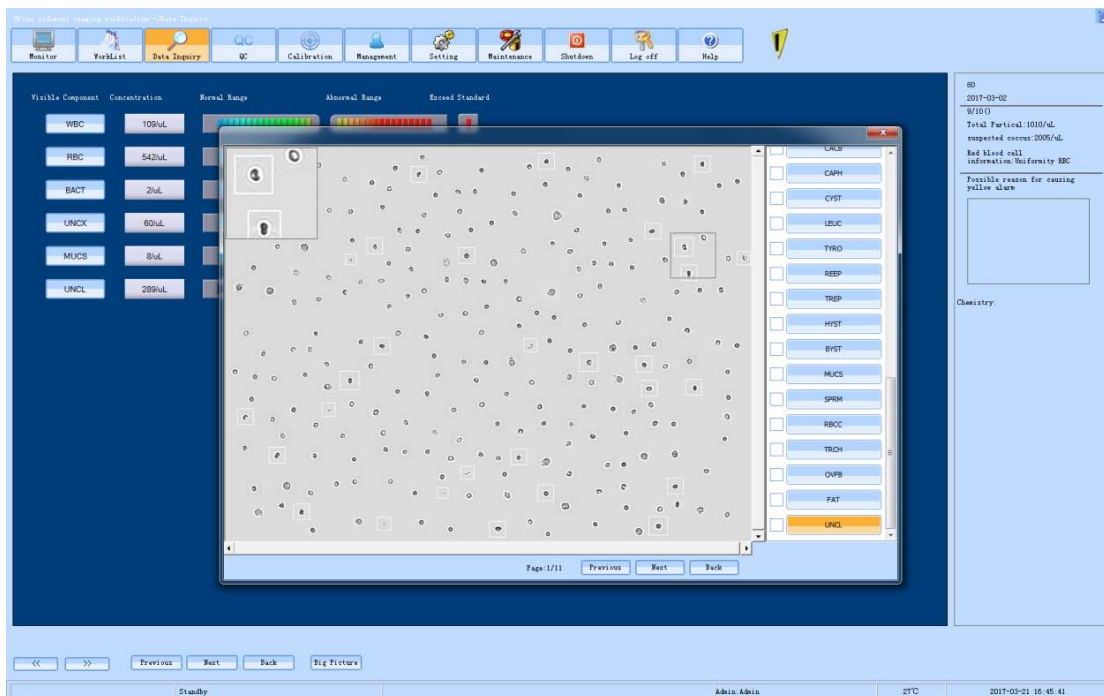


**Codocytes-FUS-2000 big picture**

## Crescent RBCs



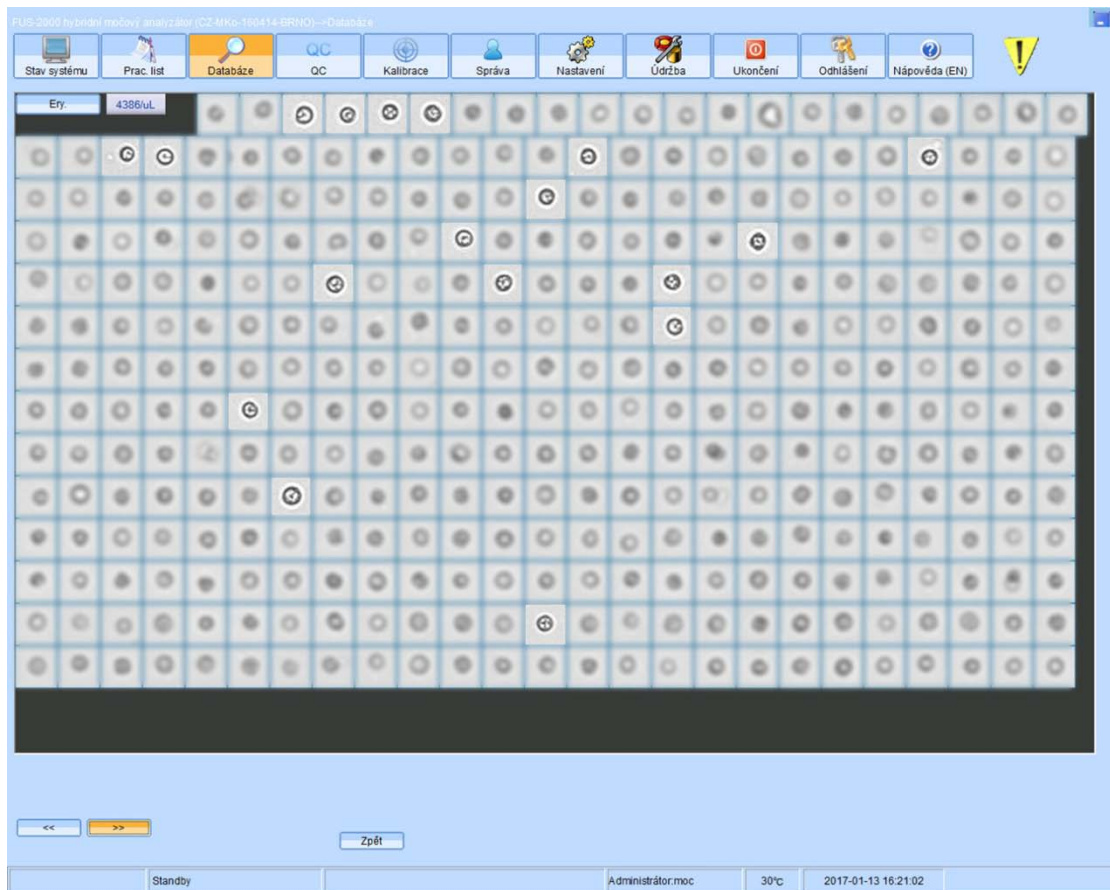
**Crescent RBCs-FUS-2000 isolated picture**



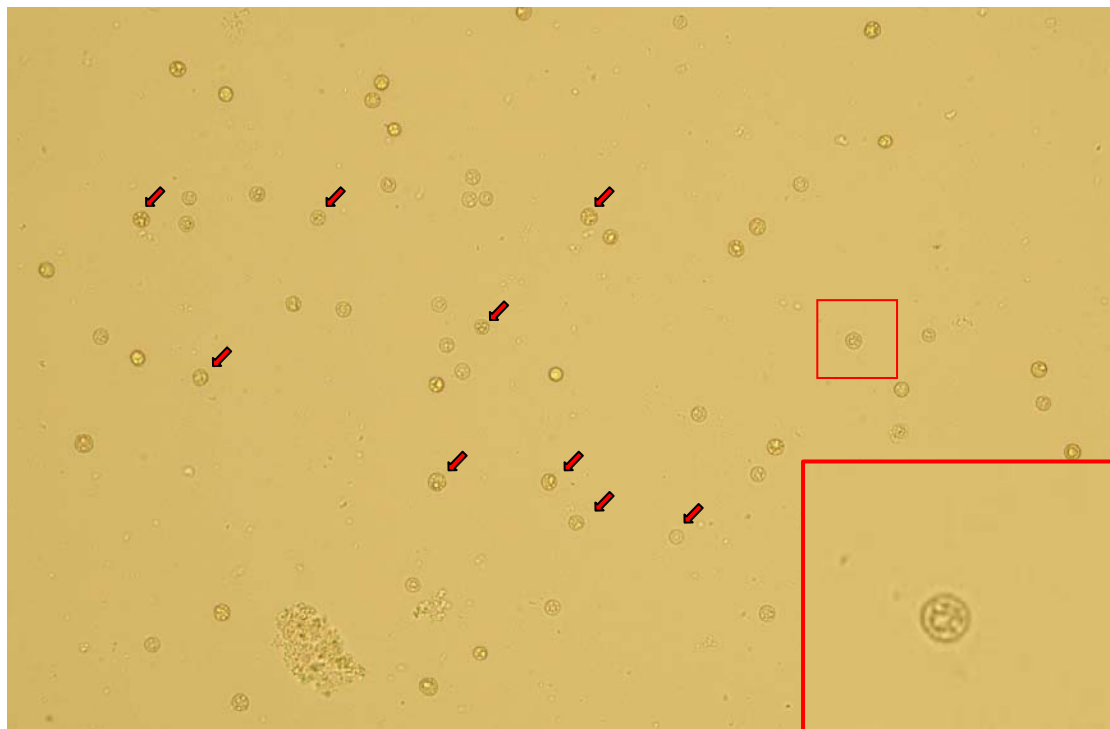
**Crescent RBCs-FUS-2000 big picture**



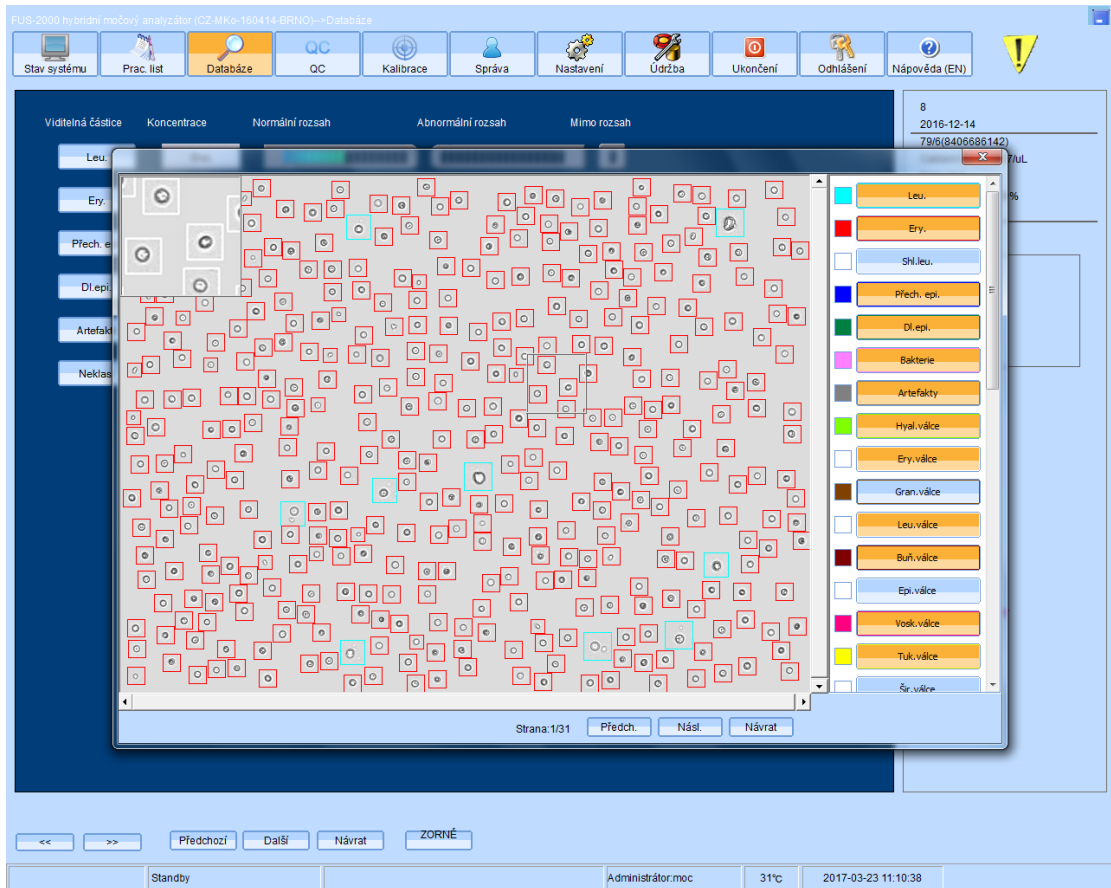
## Nucleated RBCs




Nucleated RBCs- FUS-2000 isolated picture



Nucleated RBCs-Microscopic picture of native sediment

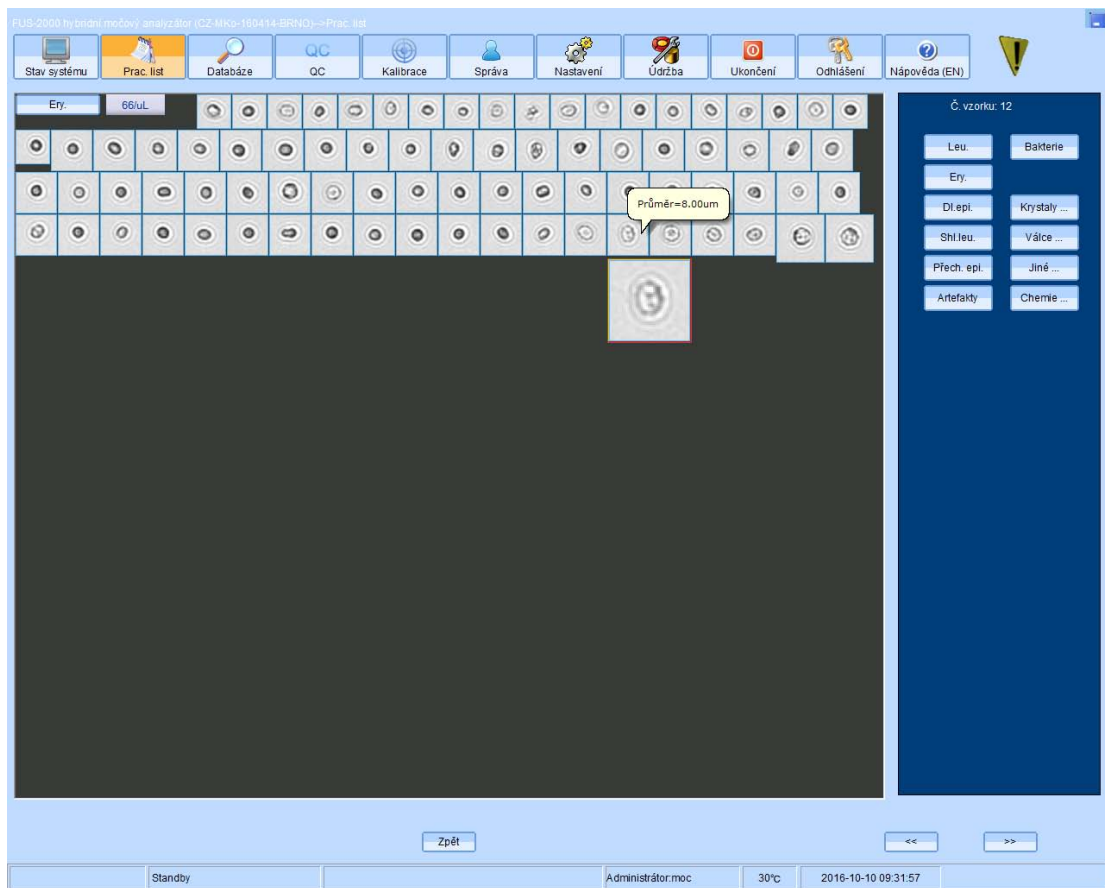


**Nucleated RBCs- FUS-2000 big picture**

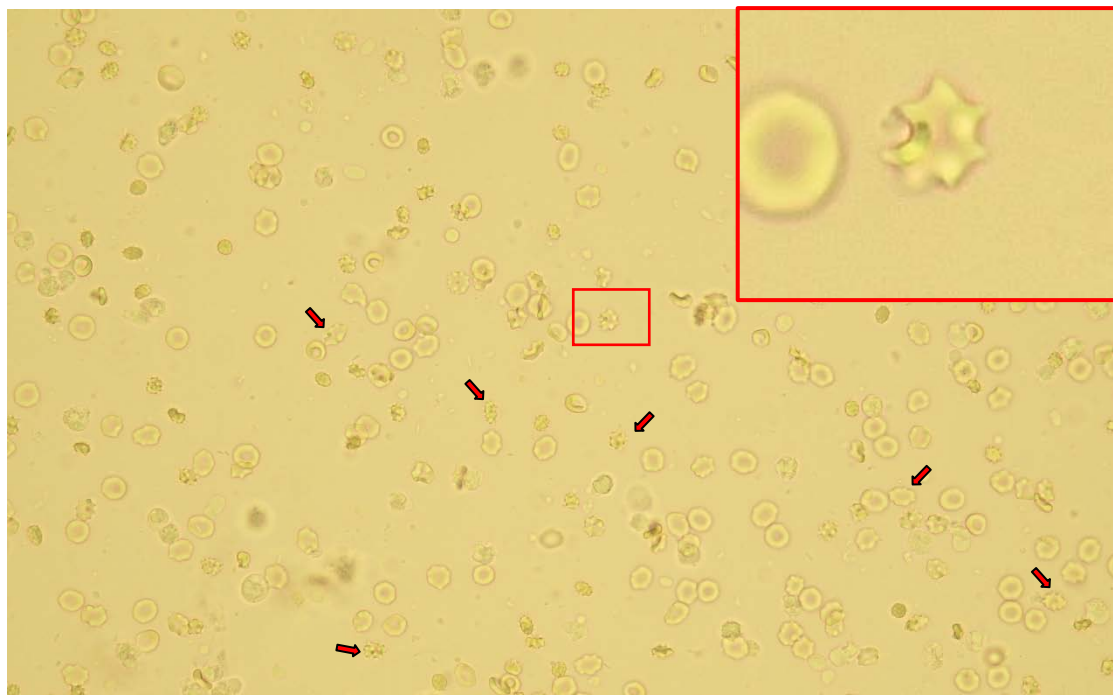


**Nucleated RBCs-Microscopic picture of stained sediment**

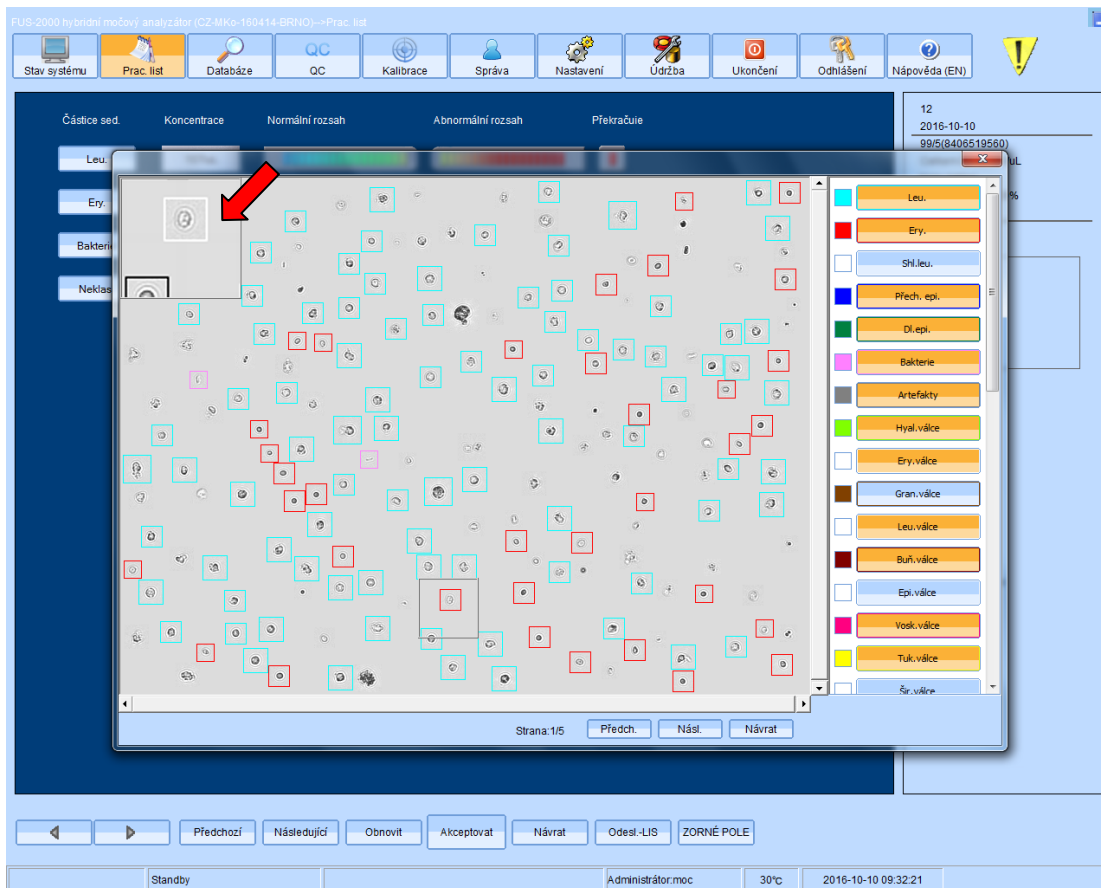
## Crenated RBCs



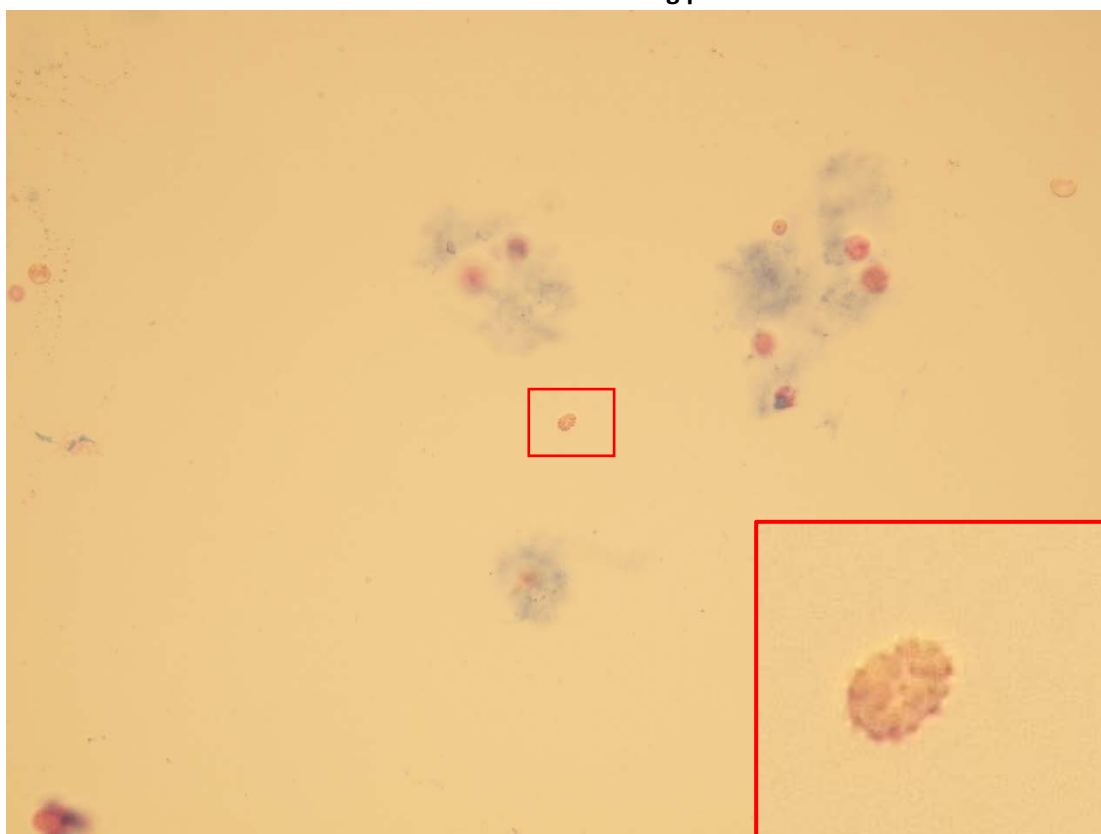
Crenated RBCs- FUS-2000 isolated picture



Crenated RBCs-Microscopic picture of native sediment



**Crenated RBCs- FUS-2000 big picture**



**Crenated RBCs-Microscopic picture of stained sediment**



# Leukocytes

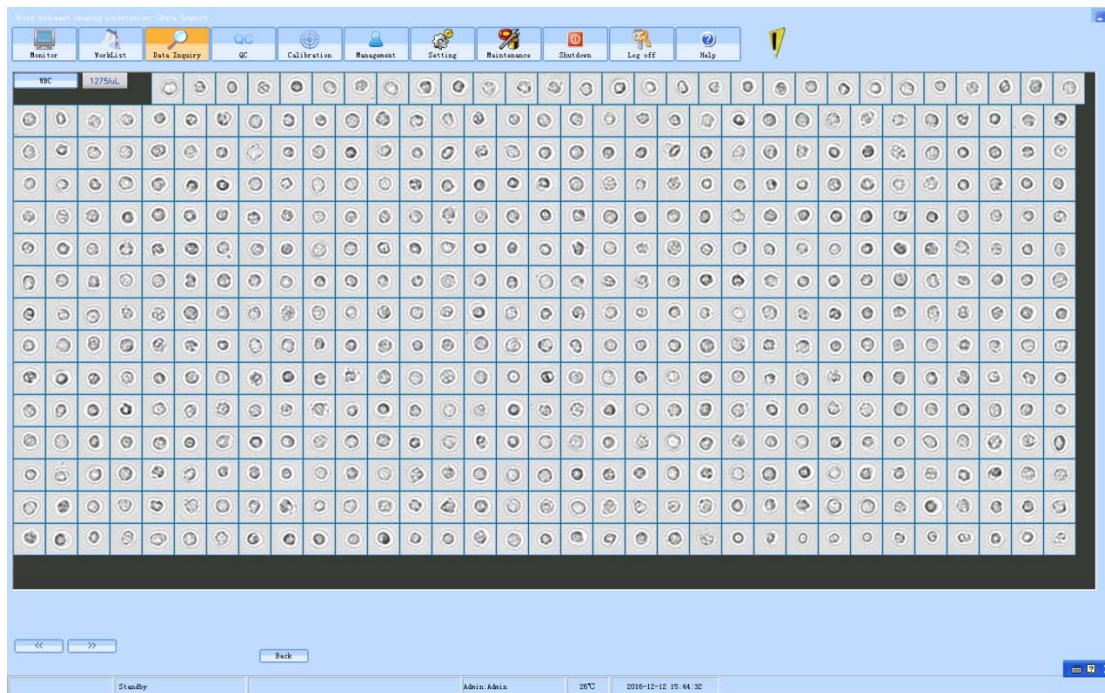
Leukocytes (white blood cells, WBCs) in the urine are mainly neutrophils, and possible small amount of lymphocytes, monocytes and eosinophils. Only small number of neutrophils is considered normal. WBCs are common in urinary tract inflammation such as pyelonephritis, cystitis, prostatitis, vesiculitis, urethritis, kidney tuberculosis, etc. and also in tumors. But it shall be beware of contamination of secretions from female reproductive system inflammation.

1. Neutrophils in urine are in spherical shape with diameter of 6-20  $\mu\text{m}$ , bigger than RBCs. Without staining, the nuclei are indistinct; particles in the cytoplasm are visible without significant degeneration and are often dispersed in intact shape. They have phagocytosis function and athletic ability to phagocytose bacteria, fungus, RBCs, bilirubin crystals and so on.

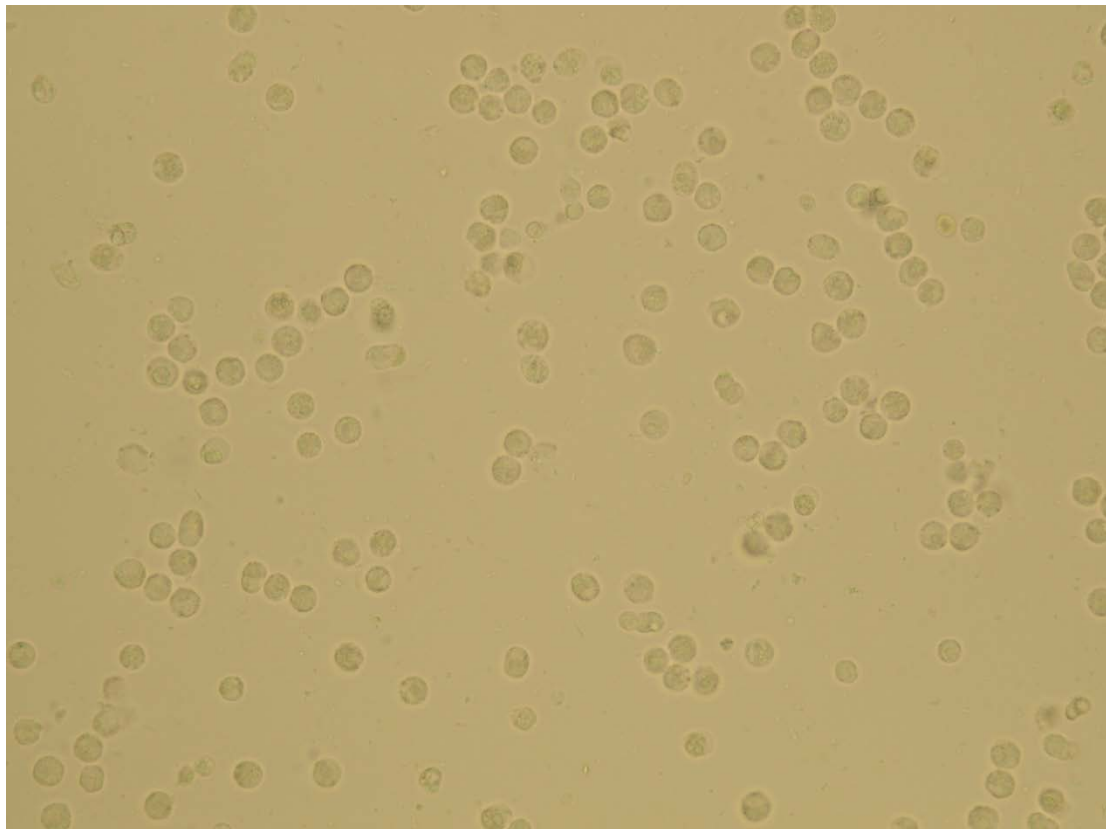
- a) Vital neutrophils are in spherical shape with diameter of 8-12  $\mu\text{m}$ . In the urine, sometimes they can become 40  $\mu\text{m}$  long rod, or oval shaped. There could be changes around the cells of filamentous, wrinkles, curved or uneven shape. The nuclei are segmented into commonly 2 to 4 lobes.
- b) Dead neutrophils (also known as pus cells) are the neutrophils destroyed, degenerated and necrotized in the inflammatory process. They are irregular with various shapes and sizes (diameter 6-20  $\mu\text{m}$ ). The cytoplasm is full of granules inside and the nuclei are ambiguous and often gathered into groups with obscure boundary. Pus cells and WBCs do not differ substantially in microscopy or imaging tests. They often increase together and their numbers are more important.

Semi-quantitative detection with diagnostic strip is based on reaction with granulocyte esterase which exists in neutrophils only. The content of granulocyte esterase is associated with the freshness of the neutrophils. Degenerated or necrotic pus cells may have reduced or even no esterase. So the test results of leukocyte esterase could be inconsistent with the formed elements results of WBCs.

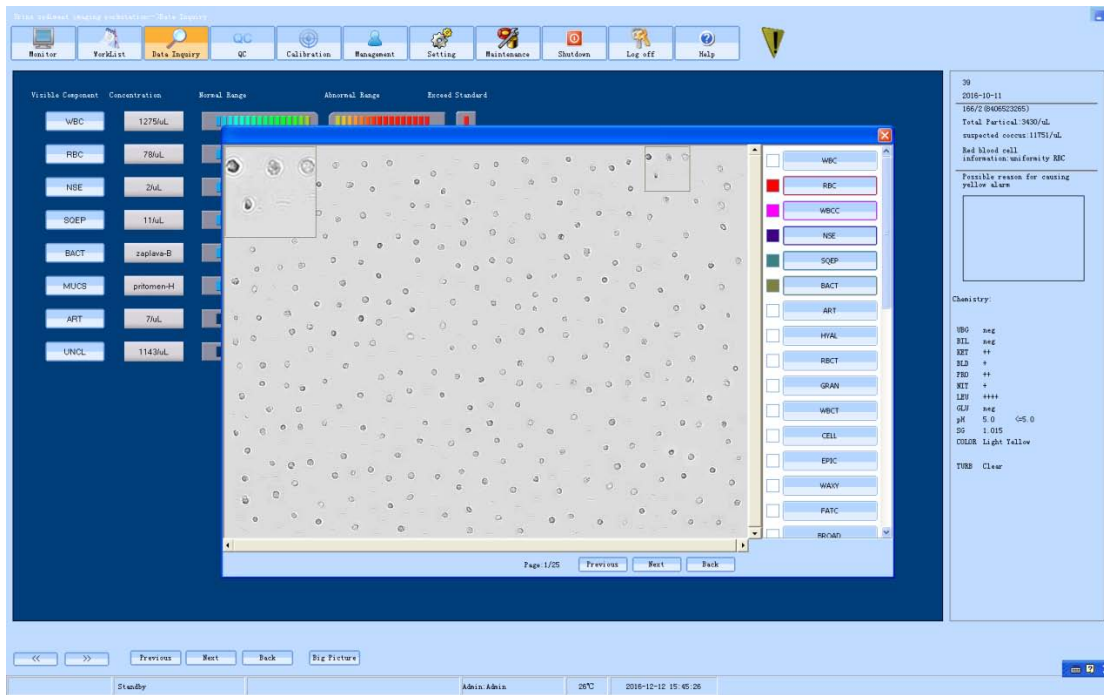
# Neutrophils



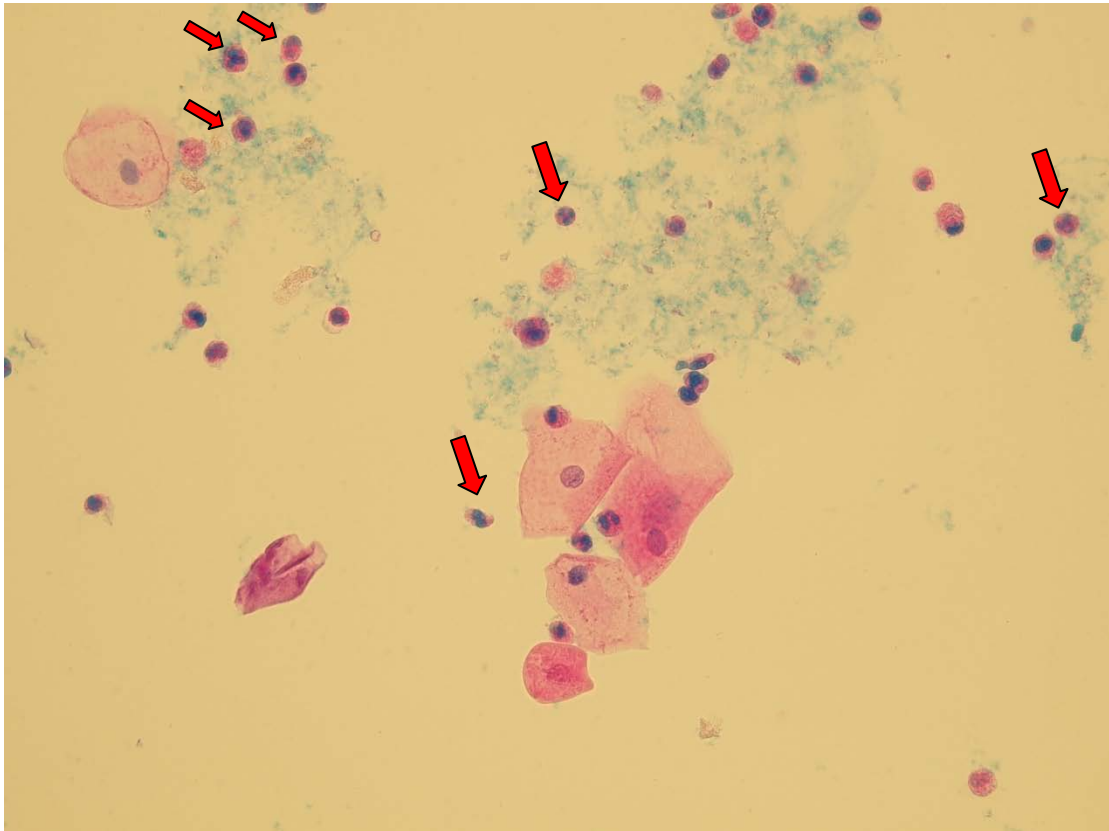
**WBCs (Neutrophils) - FUS-2000 isolated picture**



**WBCs (Neutrophils)-Microscopic picture of native sediment**



**WBCs (Neutrophils) - FUS-2000 big picture**

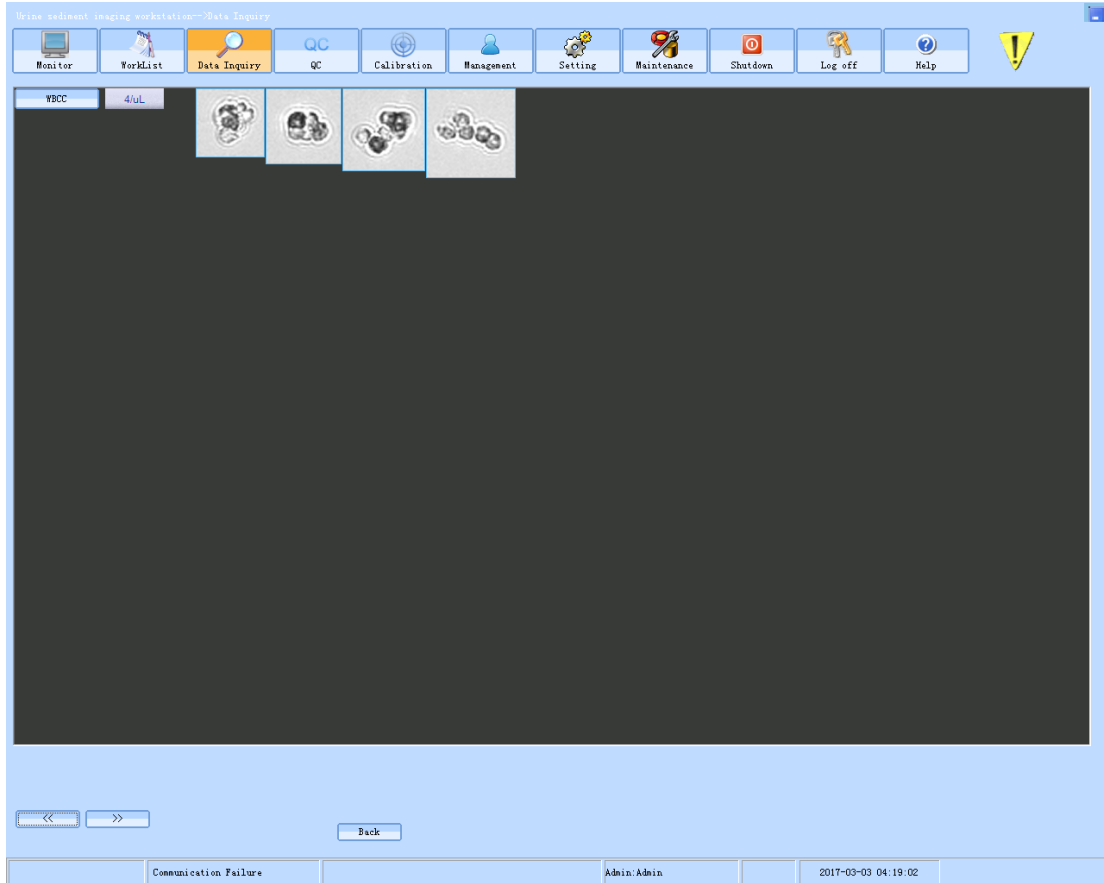


**WBCs (Neutrophils)-Microscopic picture of stained sediment**

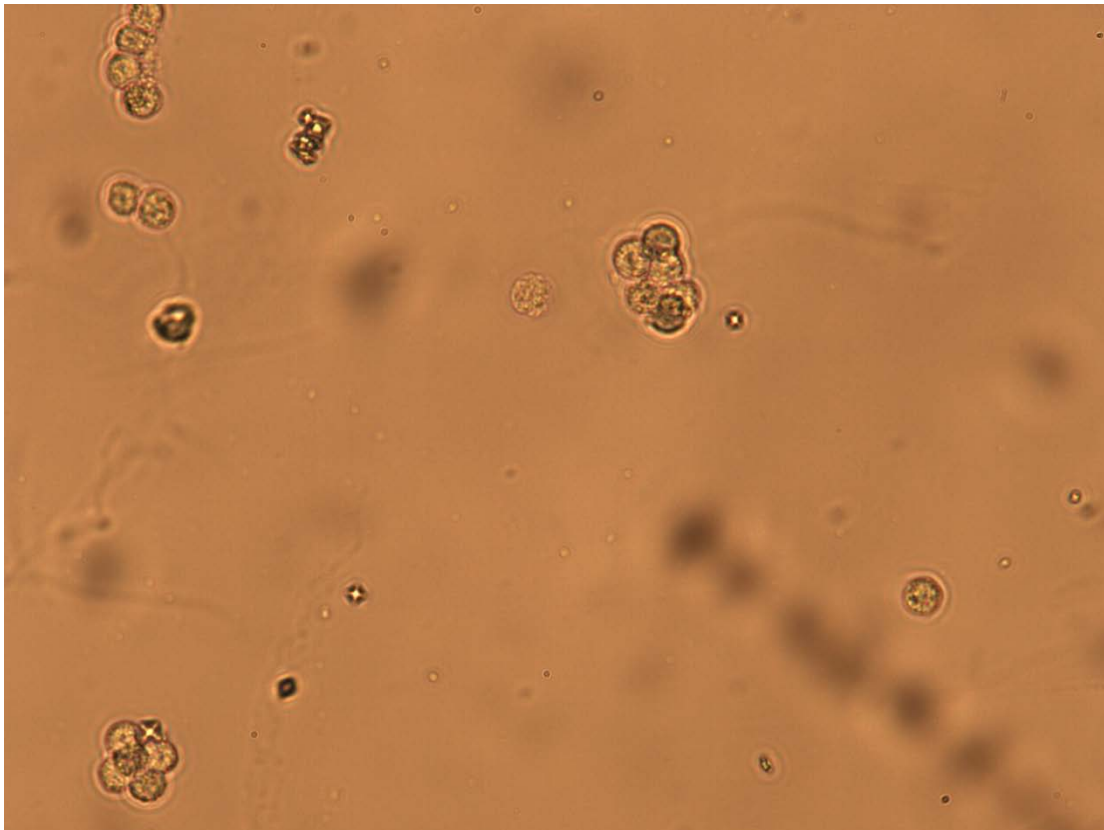
## WBCC s

Large clumps of WBCs are typically observed when there is inflammation or bacterial infections of the renal and urinary tract. The clumping is due to increased mucus in the urine.

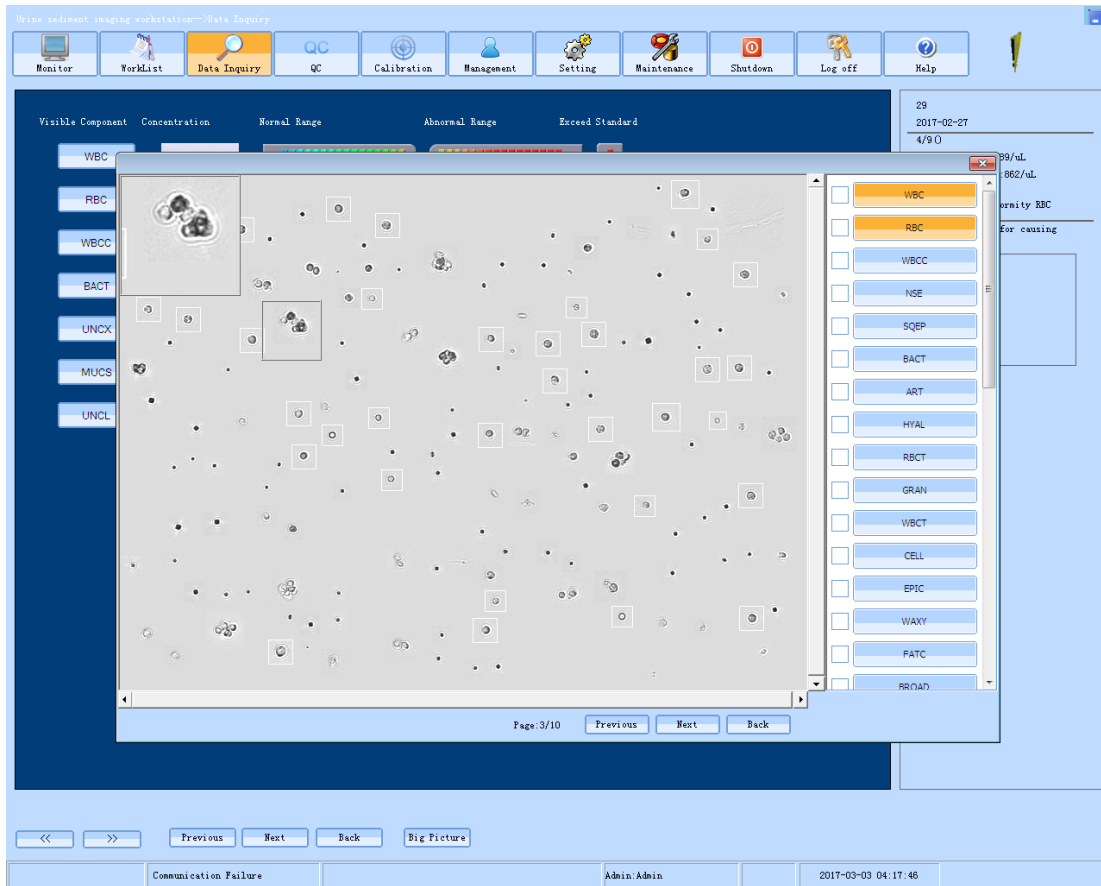
WBC clumps suggest renal origin of WBCs and should be reported when present



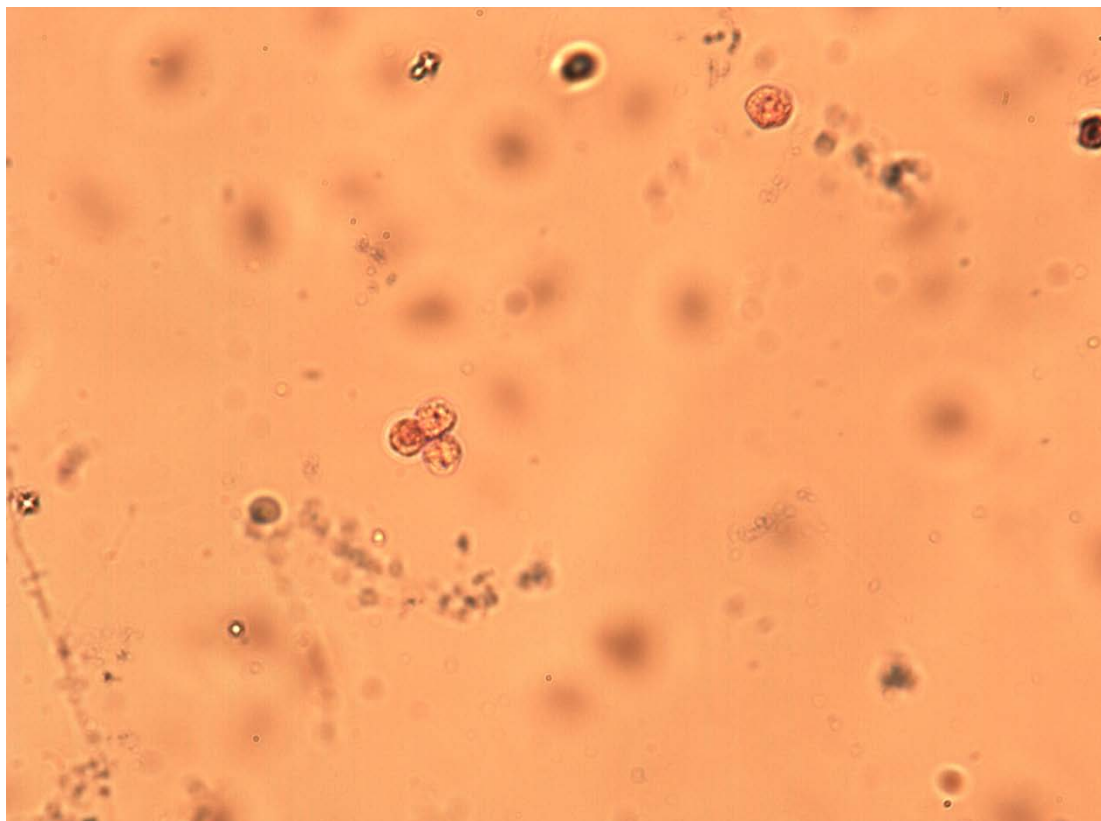
**WBCCs- FUS-2000 isolated picture**



**WBCCs-Microscopic picture of native sediment**



**WBCCs- FUS-2000 big picture**

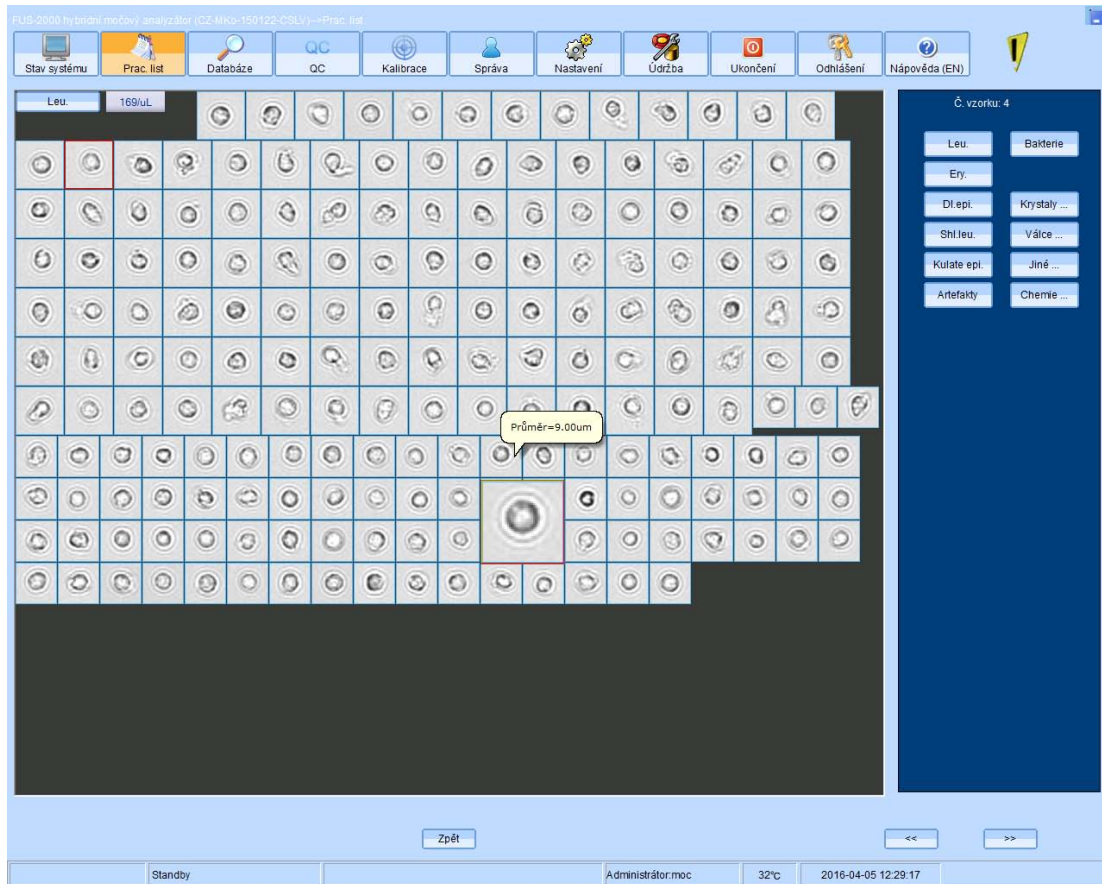


**WBCCs-Microscopic picture of stained sediment**

2. Lymphocytes are round or oval with diameter of 6-15  $\mu\text{m}$ . Generally there are no shape changes and few particles in the cytoplasm without any movement. The nucleus usually takes up most of the cell volume. It is found in renal transplant rejection, crescentic glomerulonephritis and doses of antibiotics and anti-cancer drugs.



# Lymphocytes

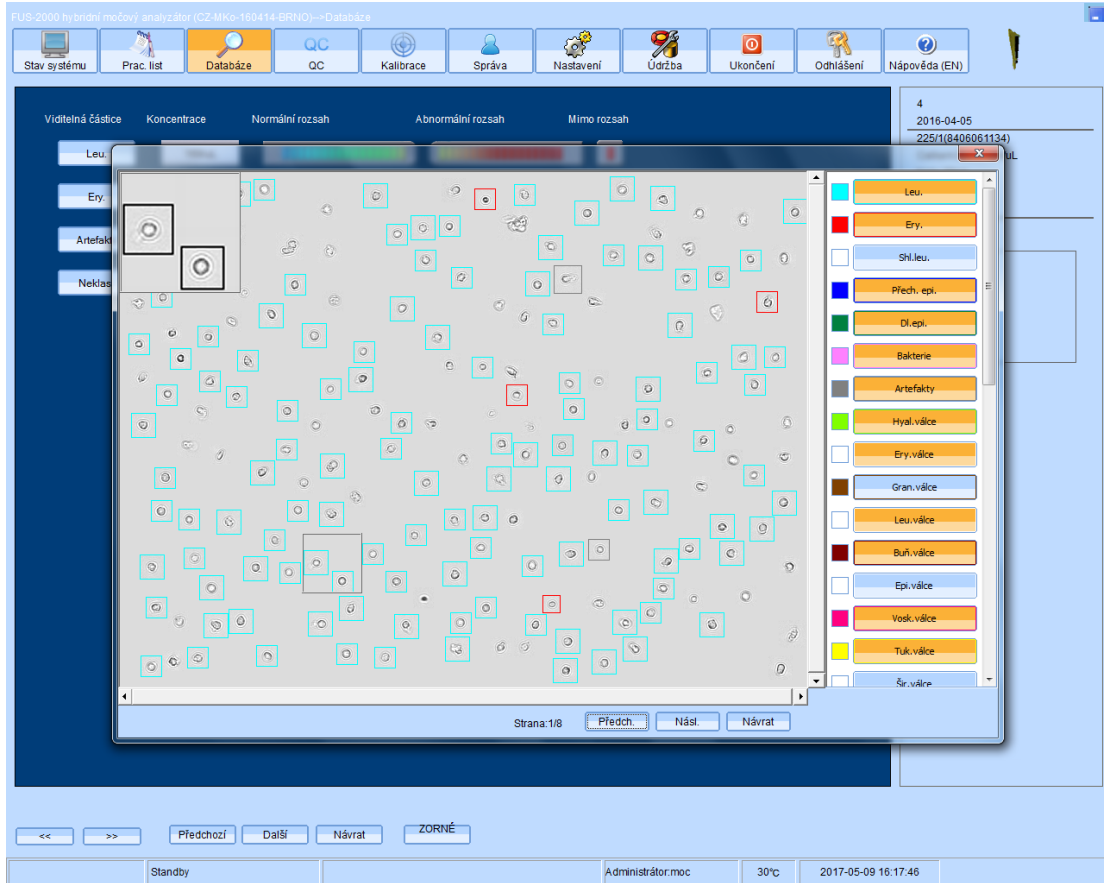


Lymphocytes- FUS-2000 isolated picture

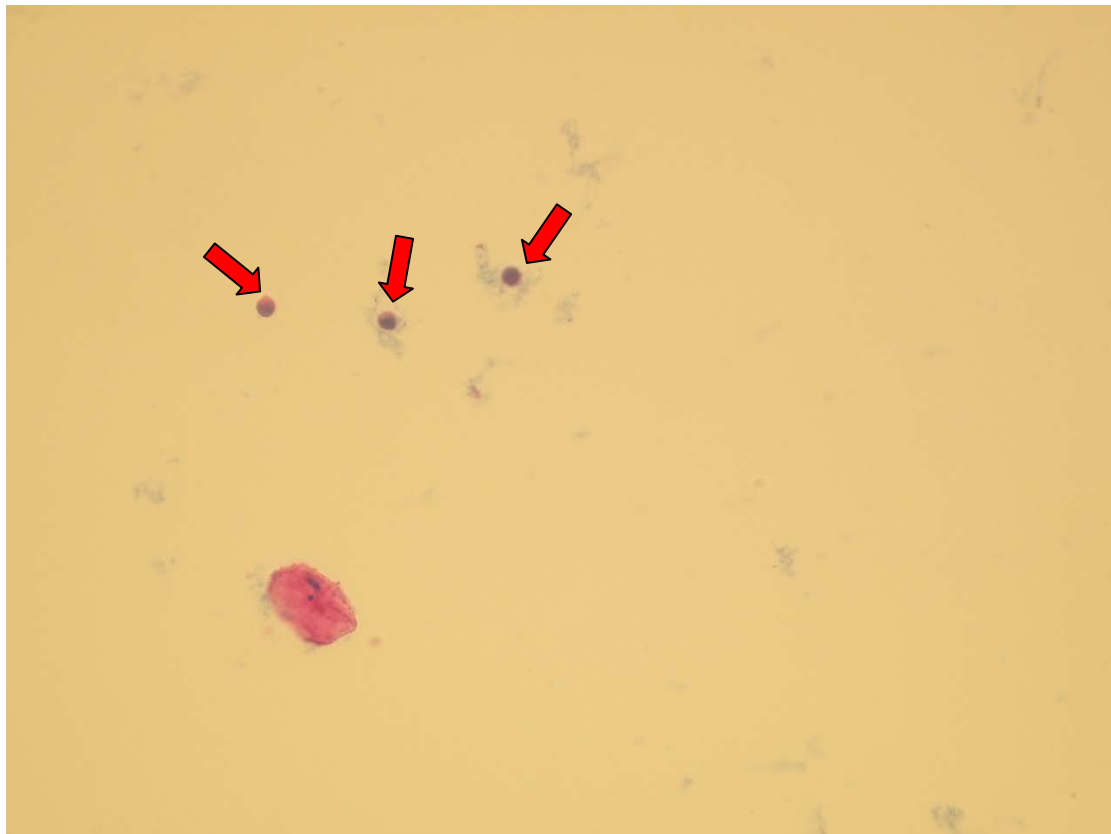


Lymphocytes-Microscopic picture of native sediment





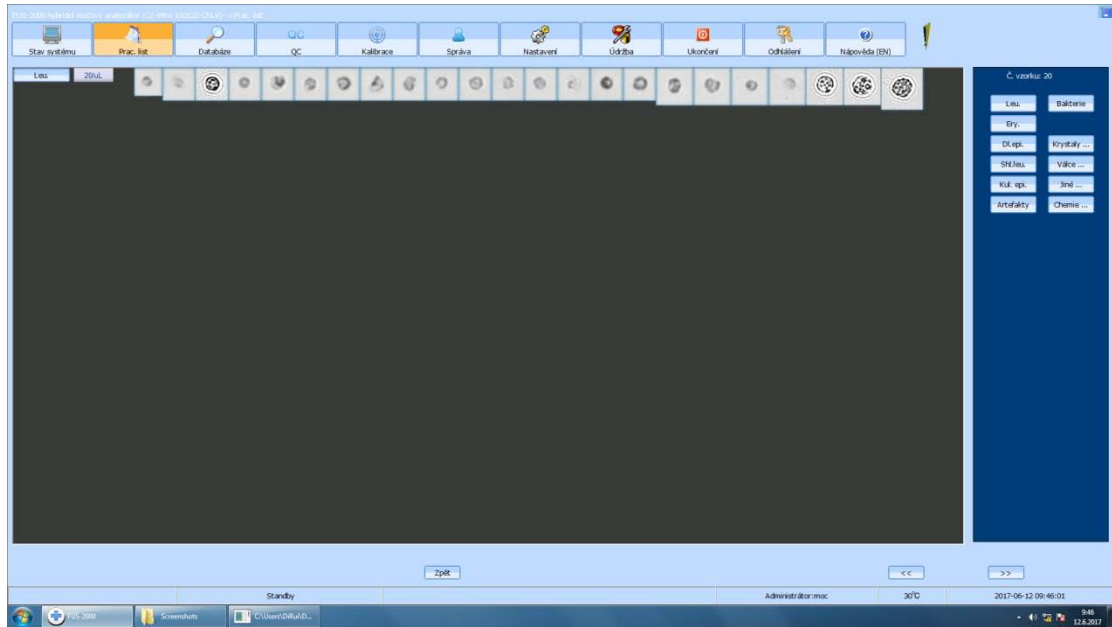
**Lymphocytes- FUS-2000 big picture**




**Lymphocytes-Microscopic picture of stained sediment**

3. Monocytes have the same active phagocytosis function in the urine as neutrophils. They usually phagocytose RBCs, other WBCs or cell debris as well as fat particles and sperms. When monocytes phagocytose other formed elements, they are known as macrophages. Monocytes have pseudopodia extended from cytoplasm. They are active and move slowly. Cells sizes are around 12-20  $\mu\text{m}$ . The forms can be various. Monocytes can diminish or disappear in acute renal tubular necrosis.

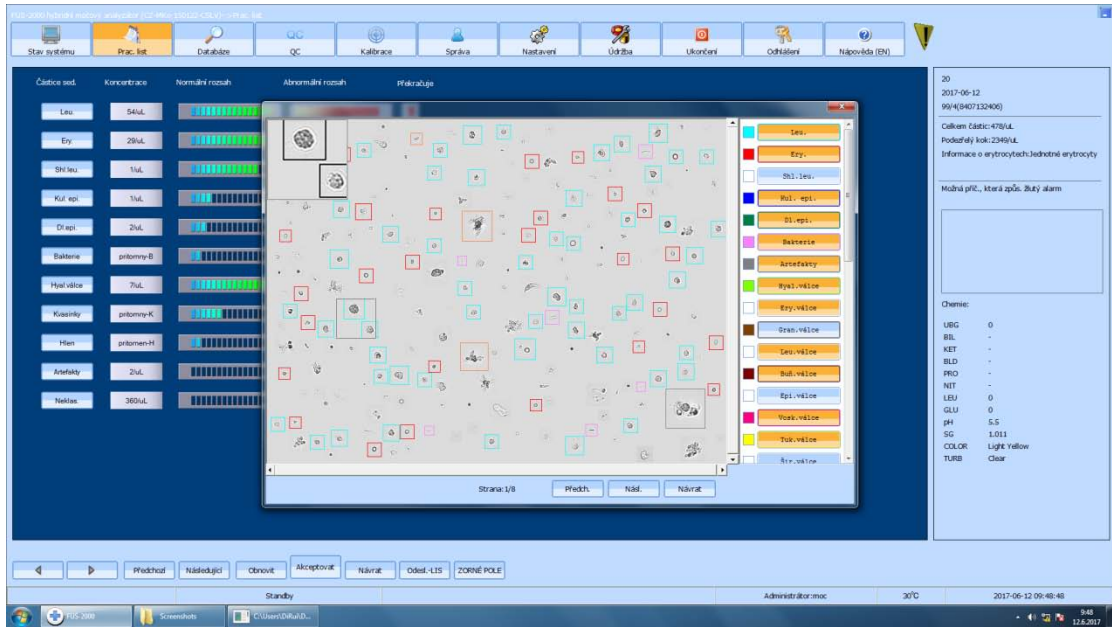
# Monocytes



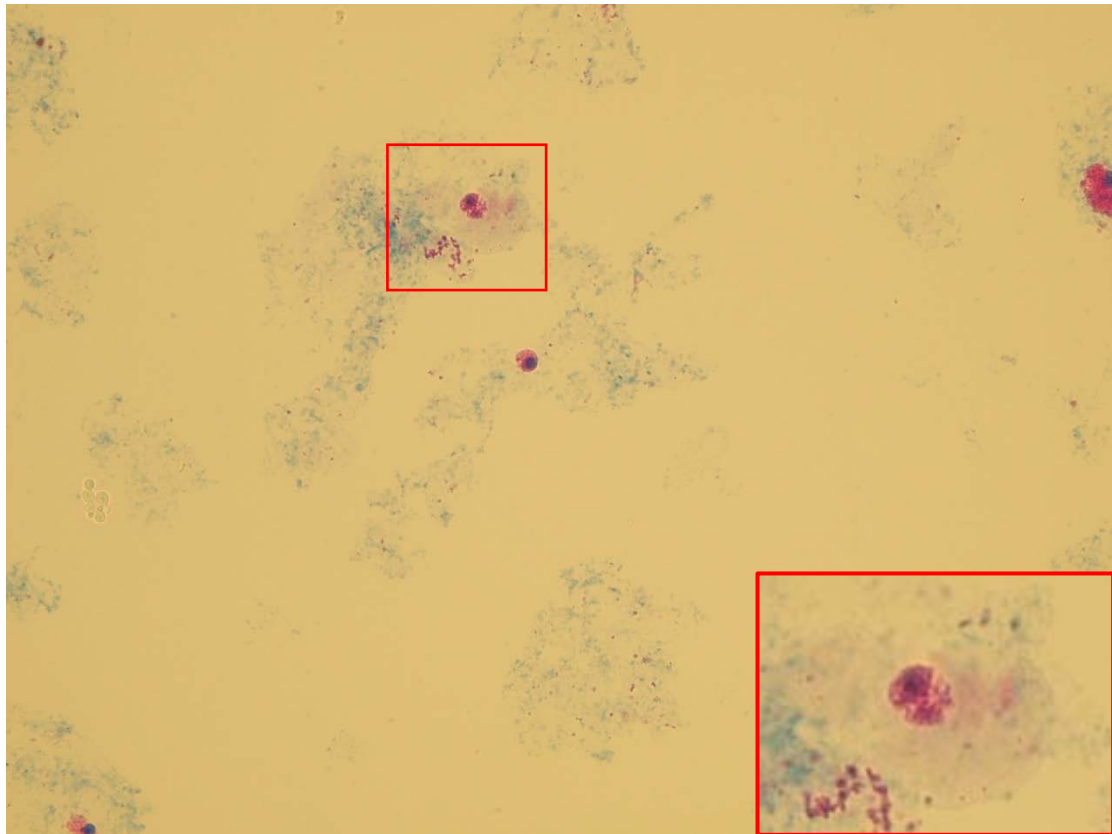
Monocytes- FUS-2000 isolated picture



Monocytes-Microscopic picture of native sediment



Monocytes- FUS-2000 big picture

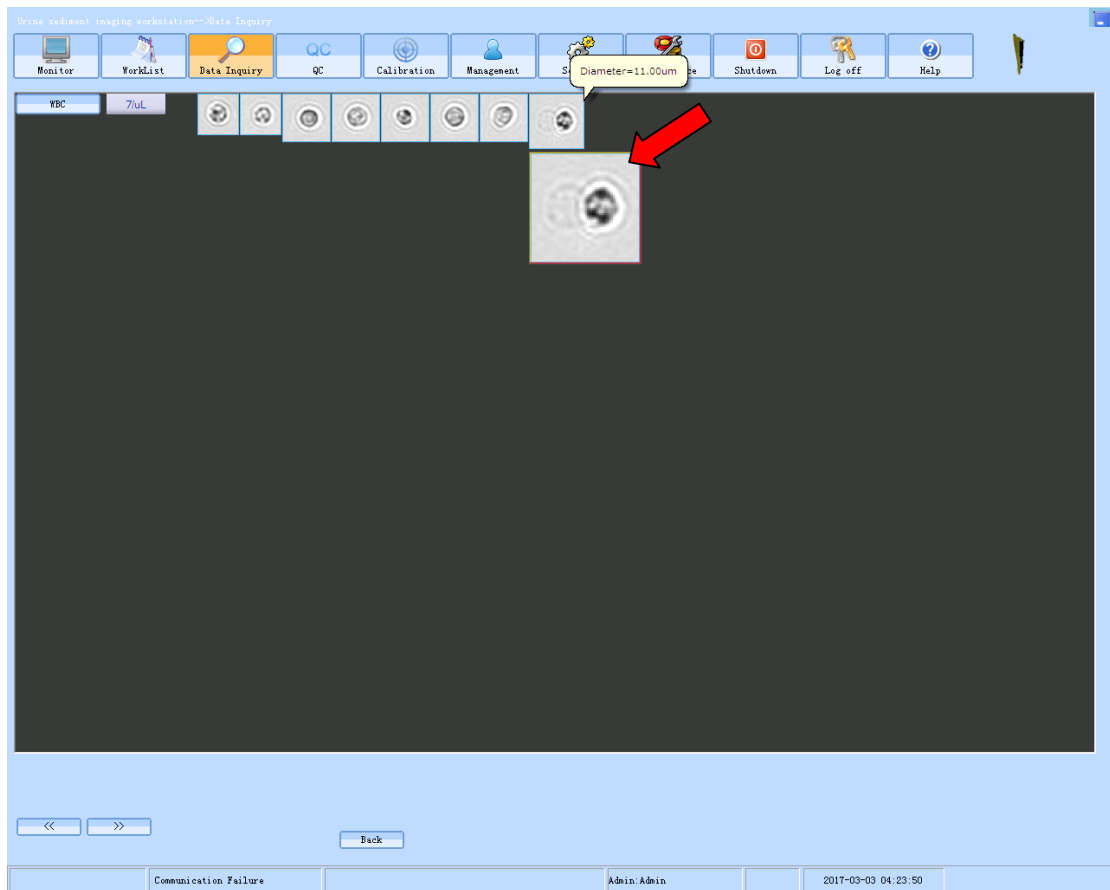


Monocytes-Microscopic picture of stained sediment

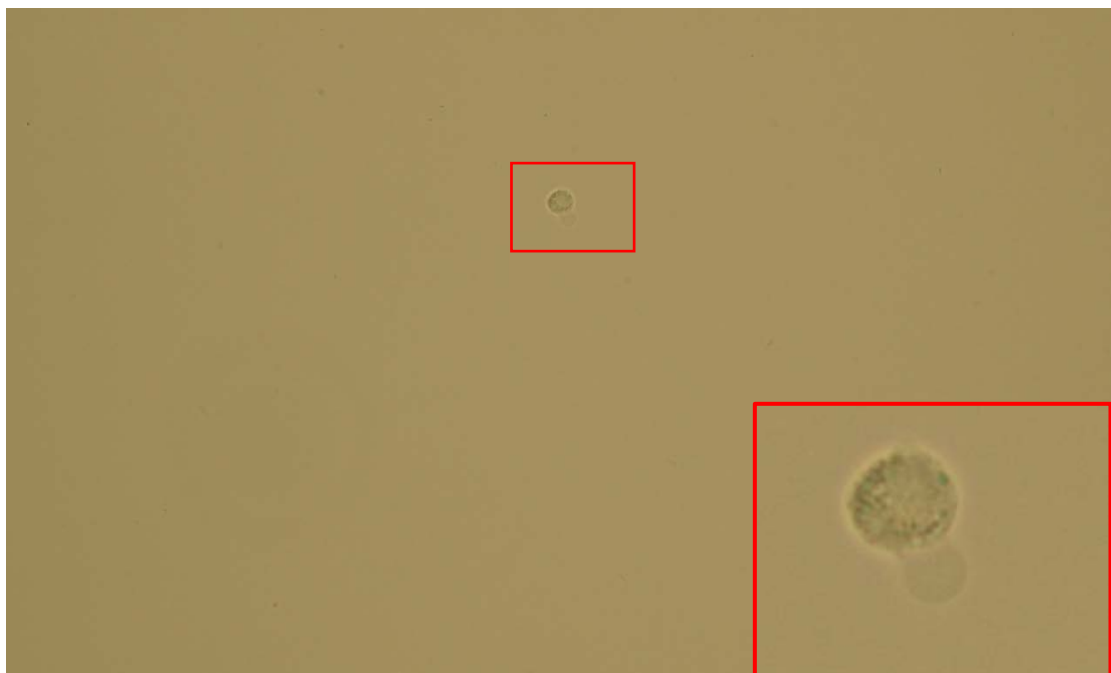
4, Eosinophils are mostly round or oval with diameter of 8-20 $\mu$ m. The 0.5 $\mu$ m diameter spherical eosinophilic granules have refractivity and are distributed in the cytoplasm. The nucleus is usually divided into two rounded lobes, bigger than the lobes of neutrophils nucleus. It is more common in acute interstitial nephritis, patients with drug-induced allergic reaction, allergic inflammation. Non-specific inflammation of urinary system and other parts caused by allergic diseases can also see urine increased eosinophils.

## Other WBCs

### 1. WBC with Spilled Cytoplasm



**WBC with spilled cytoplasm- FUS-2000 isolated picture**

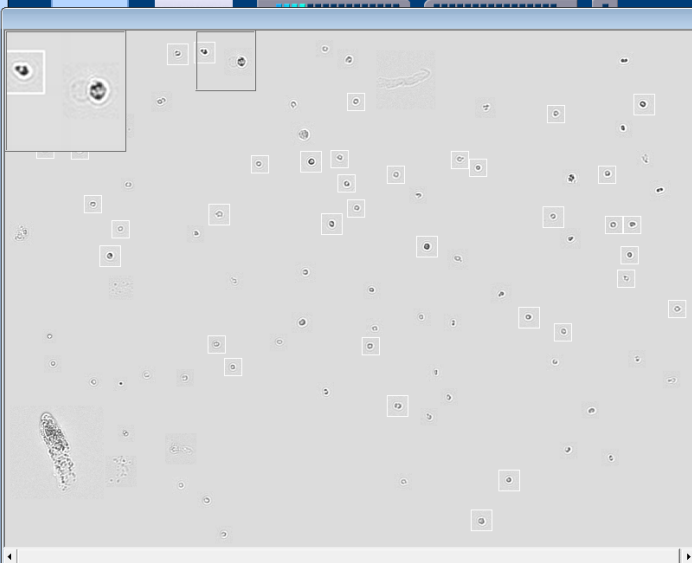


**WBC with spilled cytoplasm-Microscopic picture of native sediment**

Wine sediment imaging workstation--Data Inquiry

Monitor Worklist Data Inquiry QC Calibration Management Setting Maintenance Shutdown Log off Help

Visible Component Concentration Normal Range Abnormal Range Exceed Standard



Page: 2/6 Previous Next Back

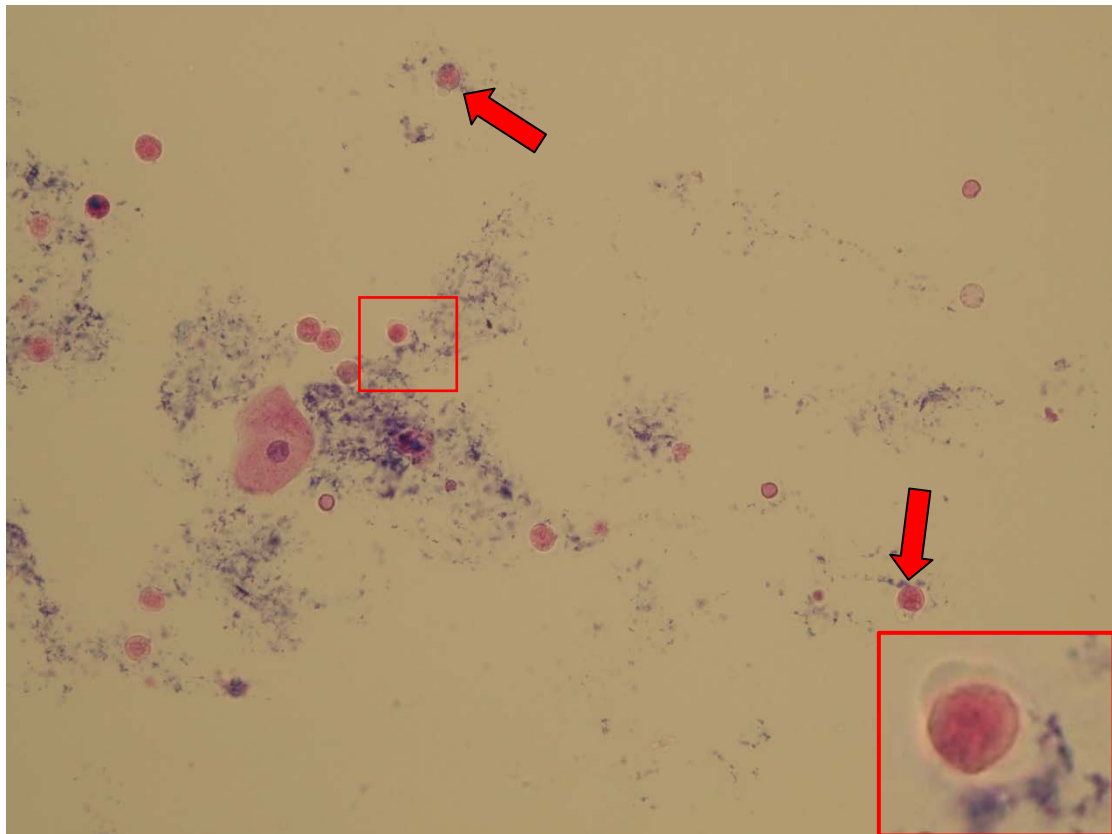
15  
2017-02-27  
3/5 0  
Total Particulate: 297/uL  
suspected coccol: 650/uL  
Red blood cell information: miscibility or nonuniformity IBC  
Possible reason for causing yellow alarm  
Meet IBC abnormality

Chemistry:

WBC  
RBC  
WBCC  
NSE  
SQEP  
BACT  
ART  
HYAL  
RBCT  
GRAN  
WBCT  
CELL  
EPIC  
WAXY  
FATC  
PROAN

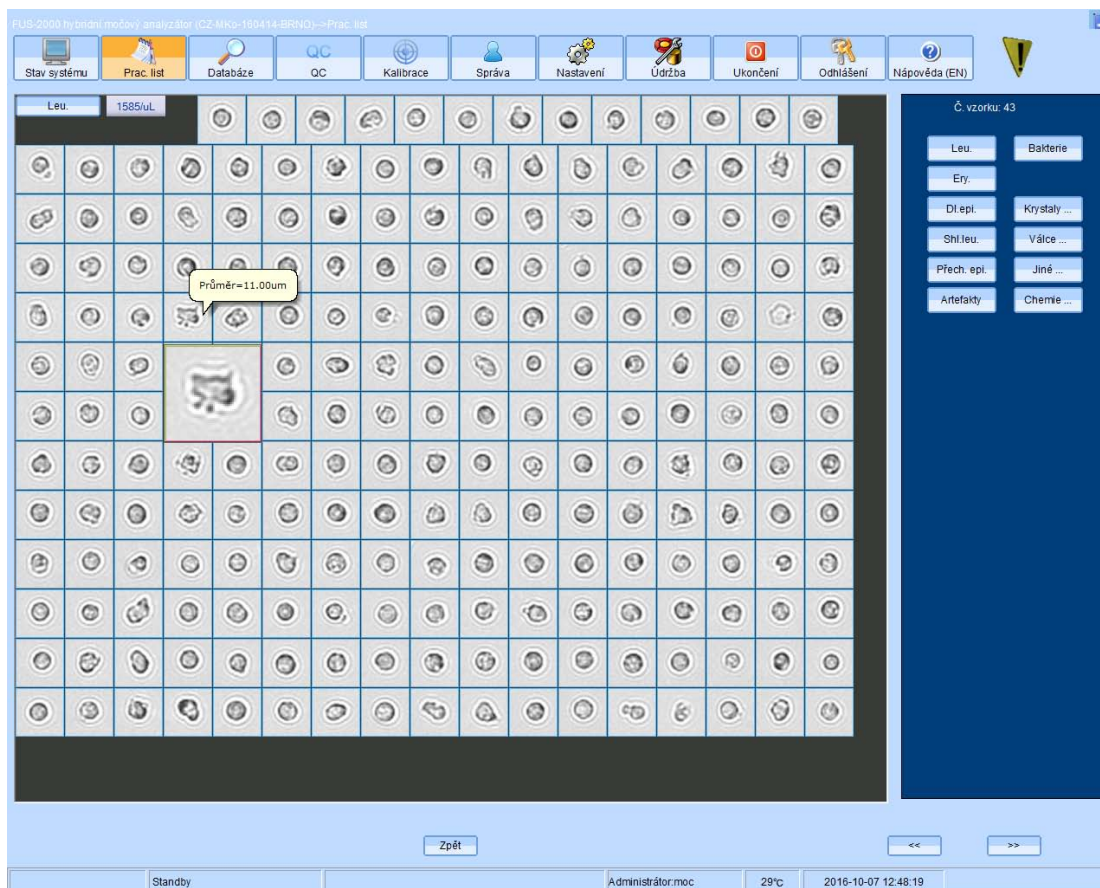
Communication Failure Admin: Admin 2017-03-03 04:25:42

**WBC with spilled cytoplasm- FUS-2000 big picture**




**WBC with spilled cytoplasm-Microscopic picture of stained sediment**

## 2. Pseudopodium WBCs

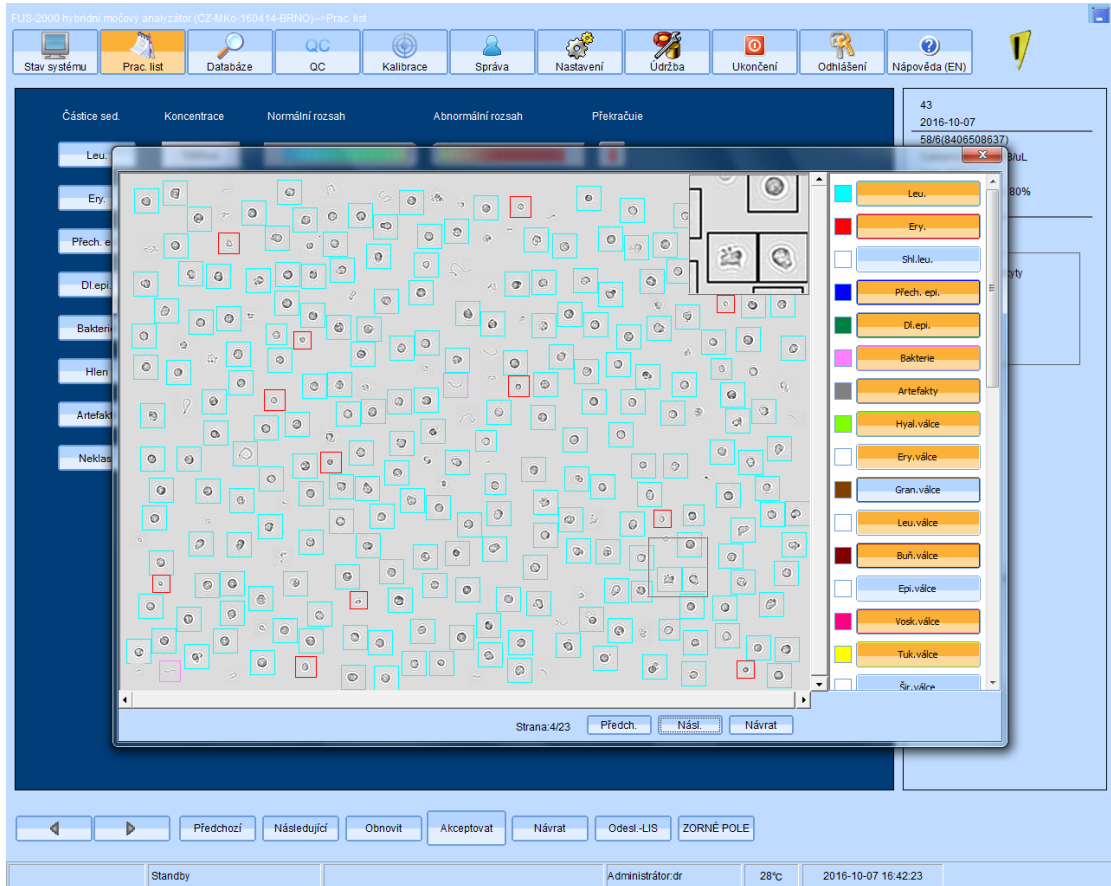


Pseudopodium WBCs- FUS-2000 isolated picture

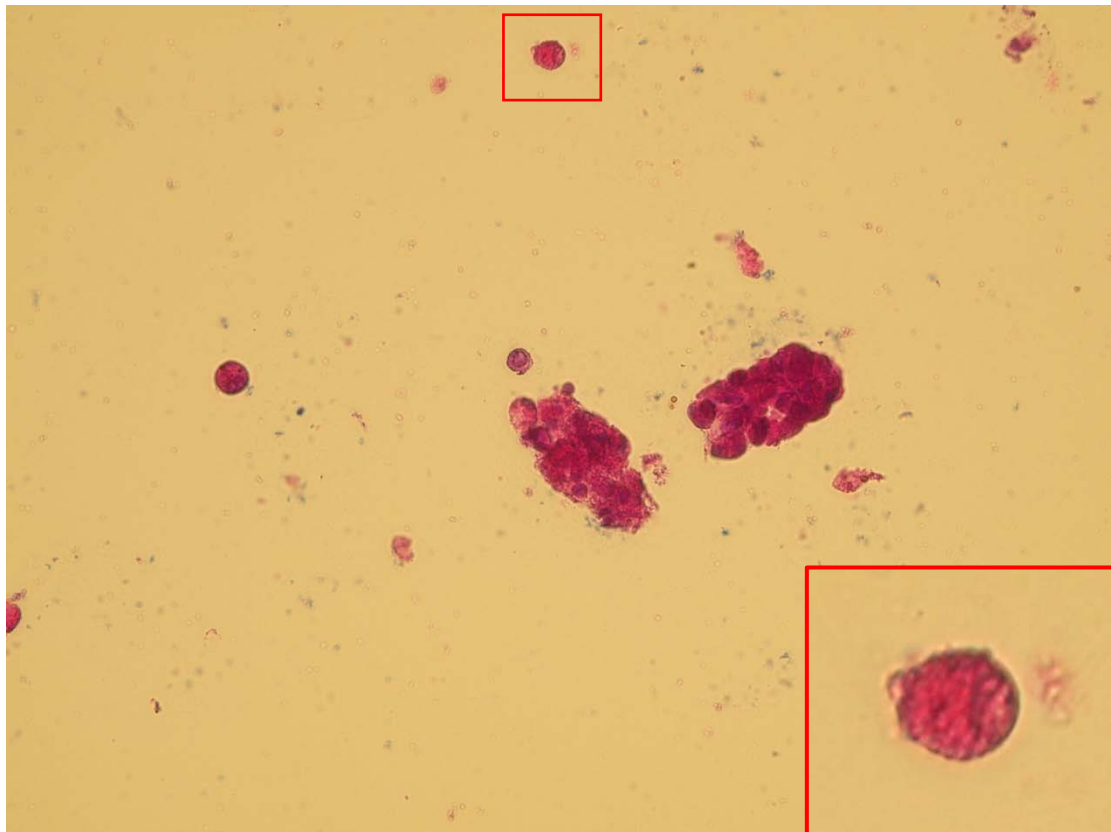


Pseudopodium WBCs-Microscopic picture of native sediment



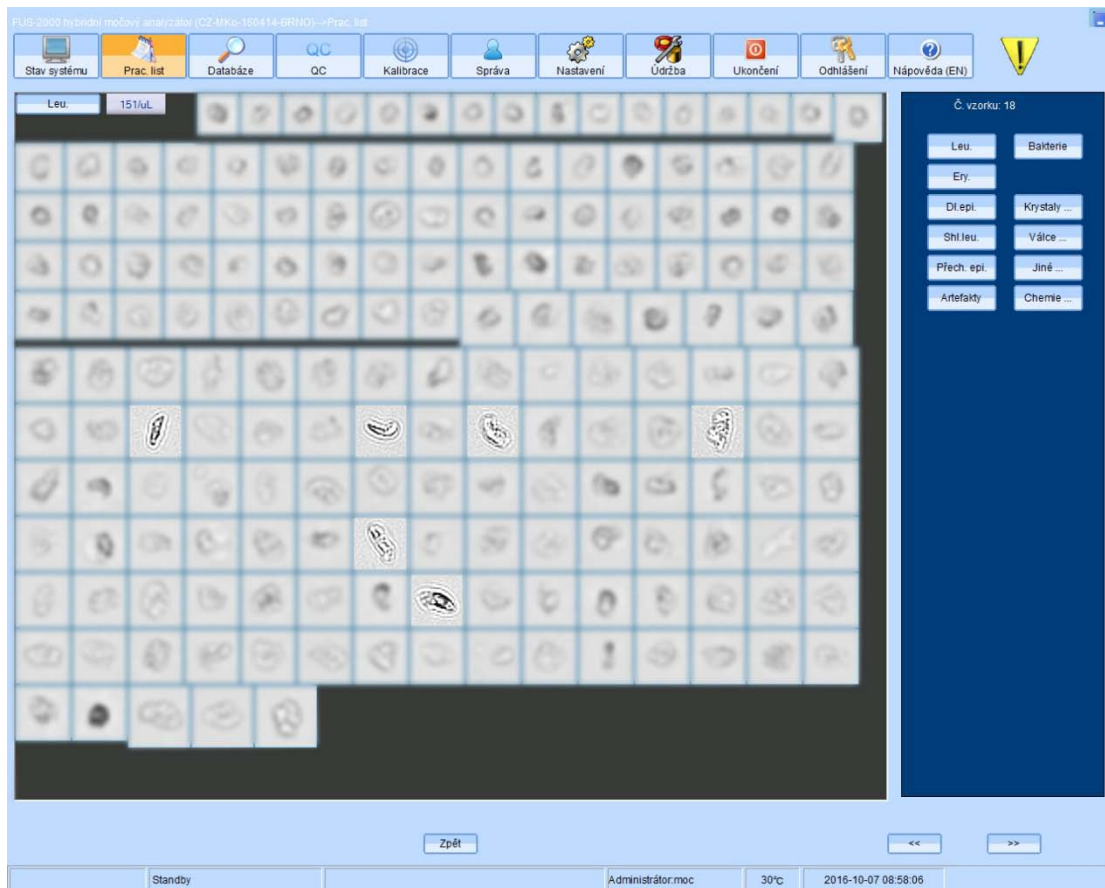


**Pseudopodium WBCs- FUS-2000 big picture**




**Pseudopodium WBCs-Microscopic picture of stained sediment**

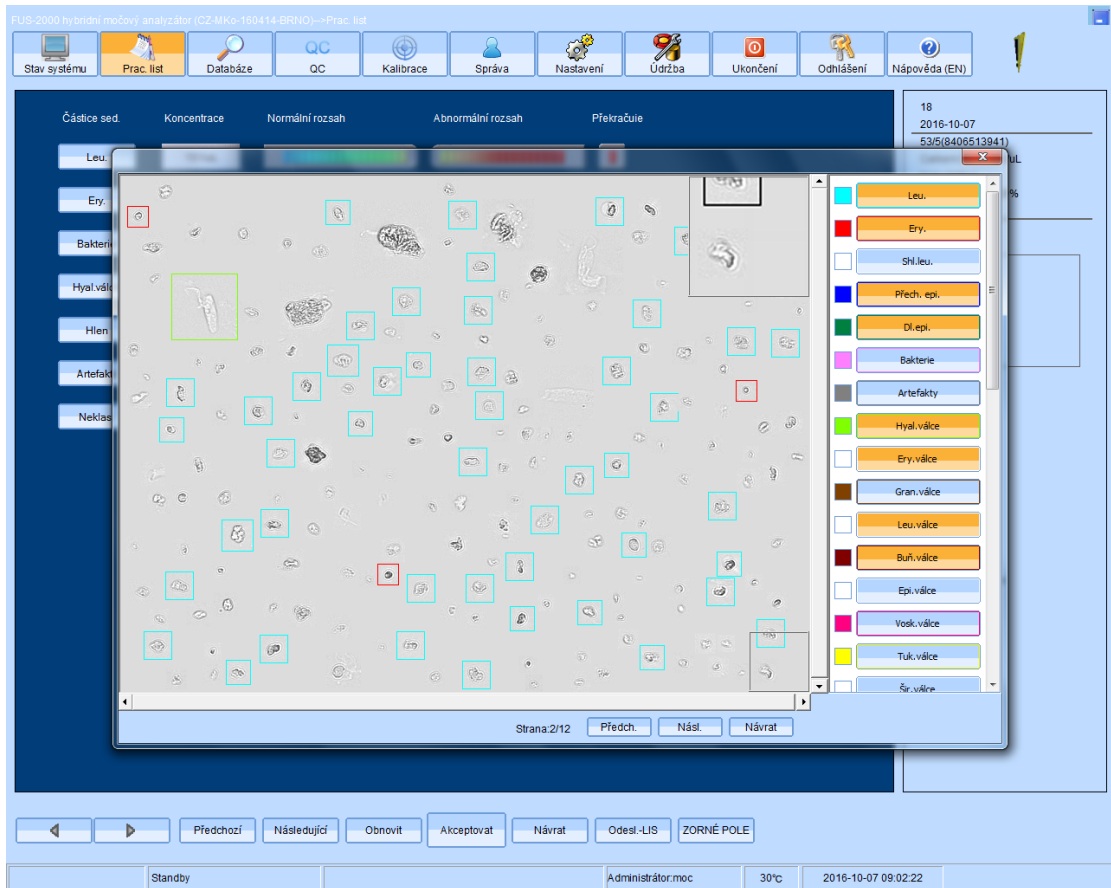
### 3. Rod shaped WBCs



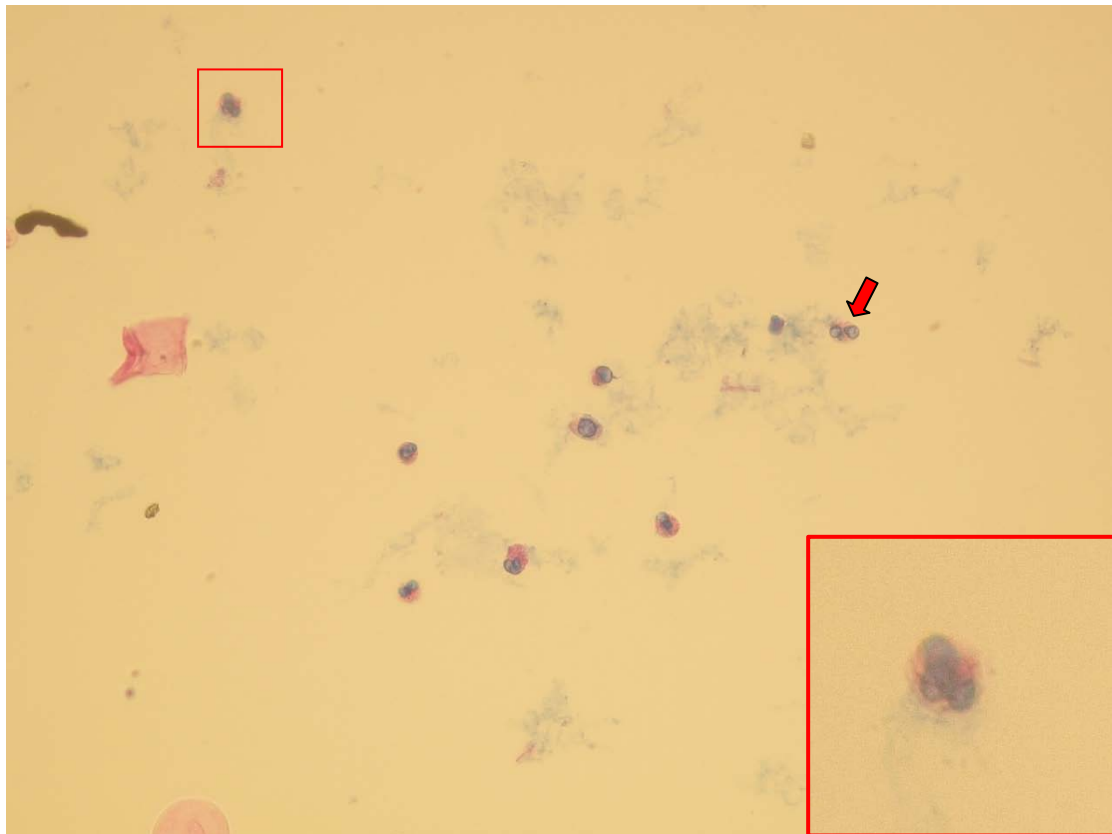
**Rod shaped WBCs- FUS-2000 isolated picture**



**Rod shaped WBCs-Microscopic picture of native sediment**



**Rod shaped WBCs- FUS-2000 big picture**



**Rod shaped WBCs-Microscopic picture of stained sediment**

Phagocytes can be divided into large and small ones.

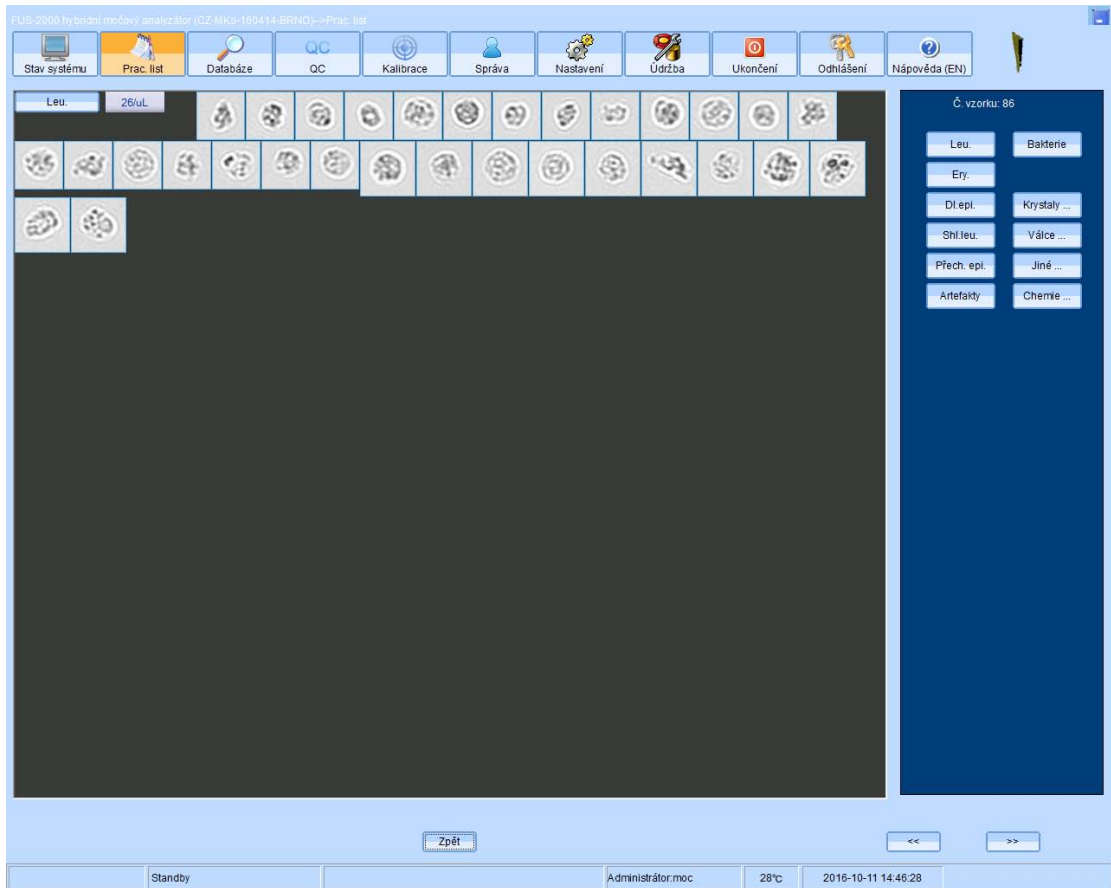
Small phagocytes, 2-3 times bigger than WBCs, come from neutrophils, phagocytosing tiny organisms such as cells.

Big phagocytes, 3-6 times bigger than WBCs, come from monocytes, also known as macrophages.

They are round or oval of irregular edges and rich in cytoplasm often with vacuoles. There could be Amoeba-like pseudopodia moving in fresh urine; nucleus is in kidney or oval shape, has fine structure and is slightly asymmetrical. Many cells are found phagocytosed in the cytoplasm, including RBCs, WBCs, fat droplets, sperms, granular objects and even other small phagocytes.

They can be seen in acute inflammation of the urinary system, such as acute pyelonephritis, cystitis, urethritis, and are often accompanied with increased WBCs, pus cells and bacteria.

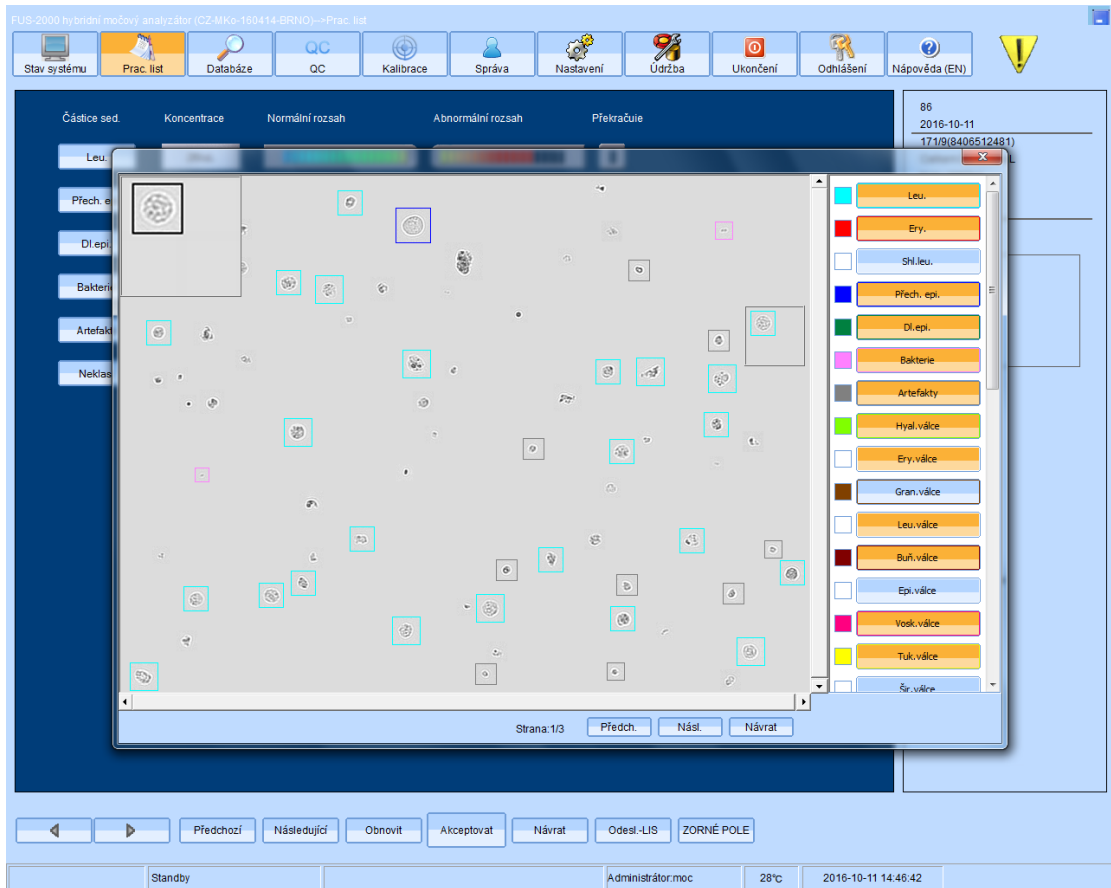
Amount of phagocytes in the urine is often closely related to inflammation degrees.



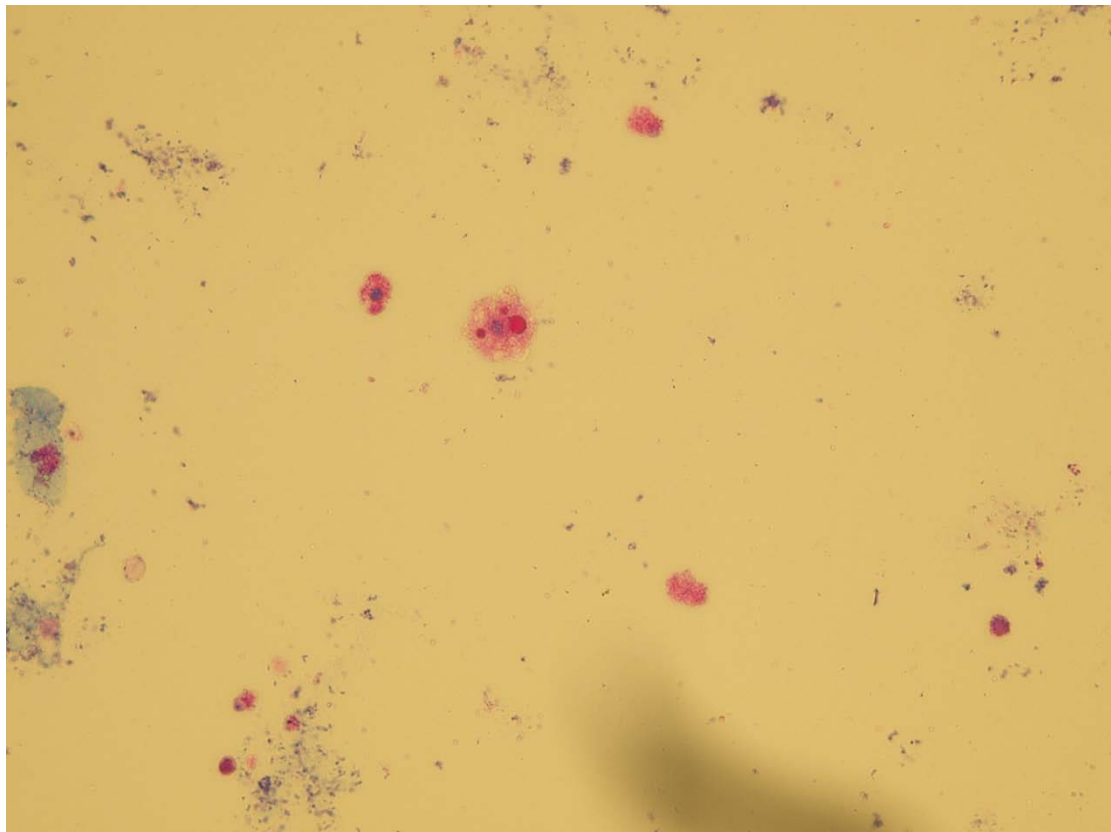
**Phagocytes- FUS-2000 isolated picture**



**Phagocytes-Microscopic picture of native sediment**

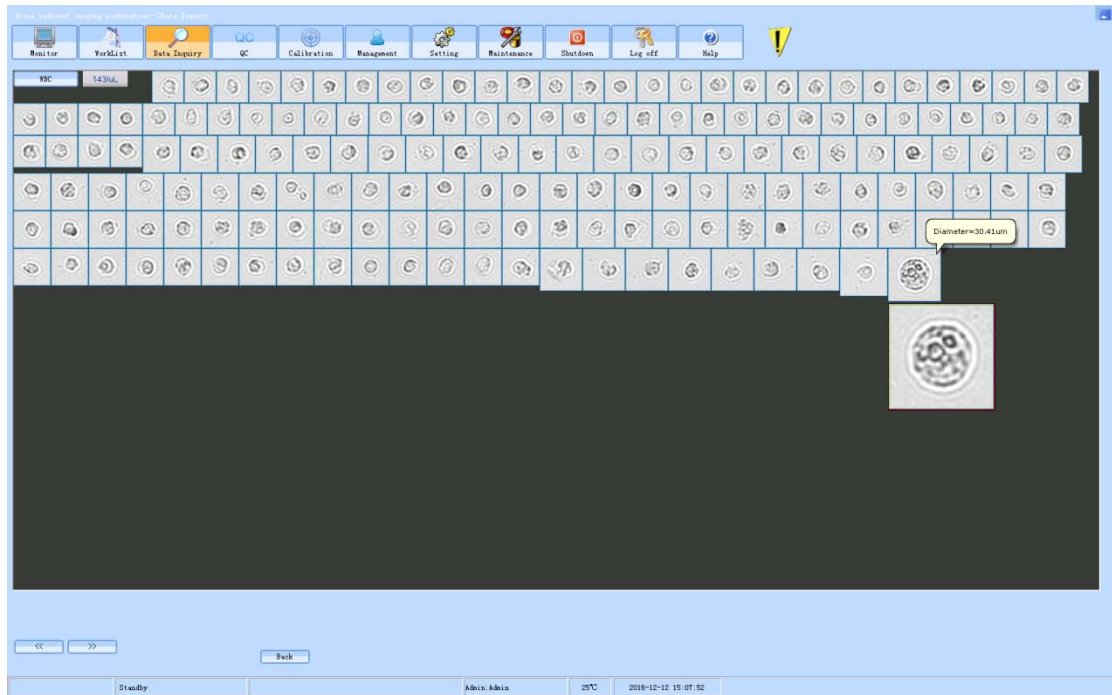


**Phagocytes- FUS-2000 big picture**

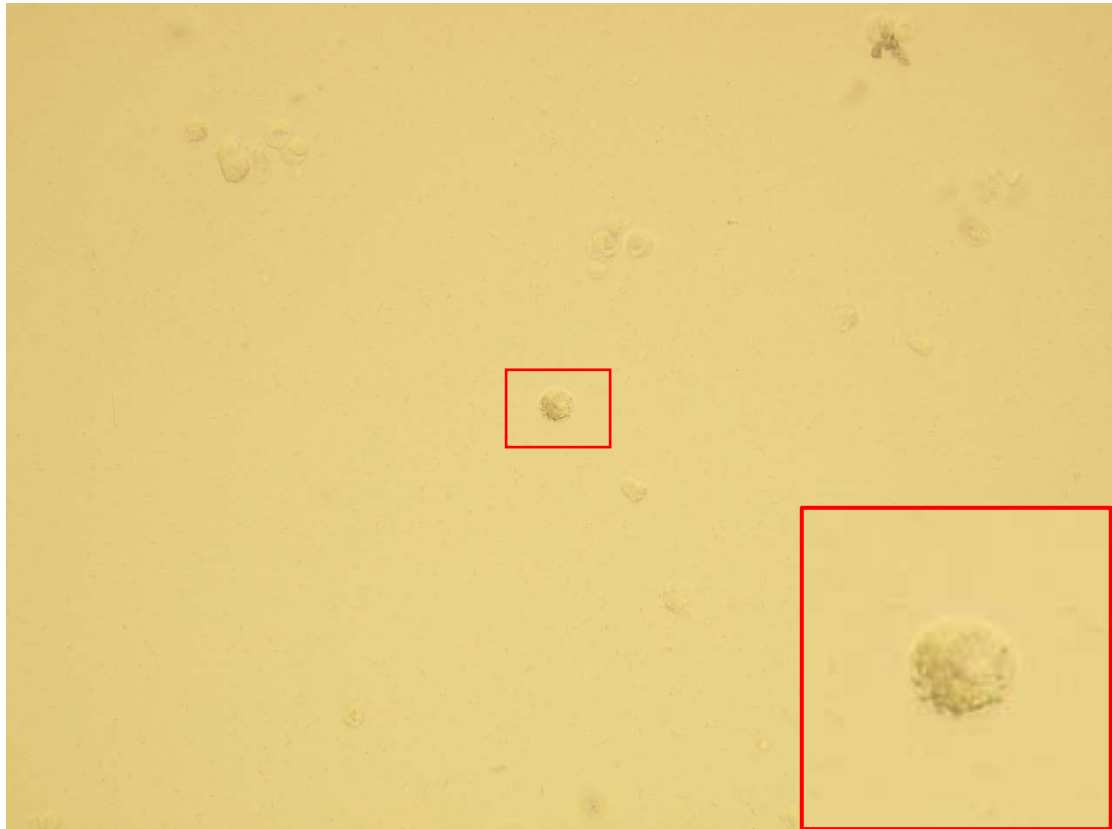


**Phagocytes-Microscopic picture of stained sediment**

## WBC Including Fat

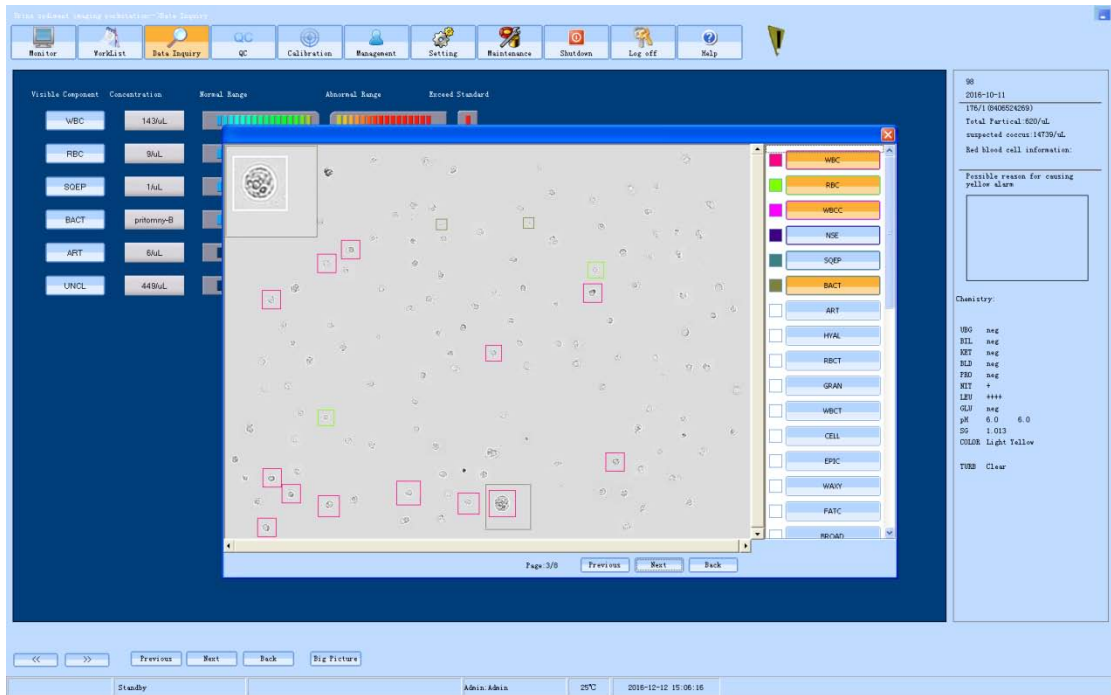


**WBC including fat- FUS-2000 isolated picture**

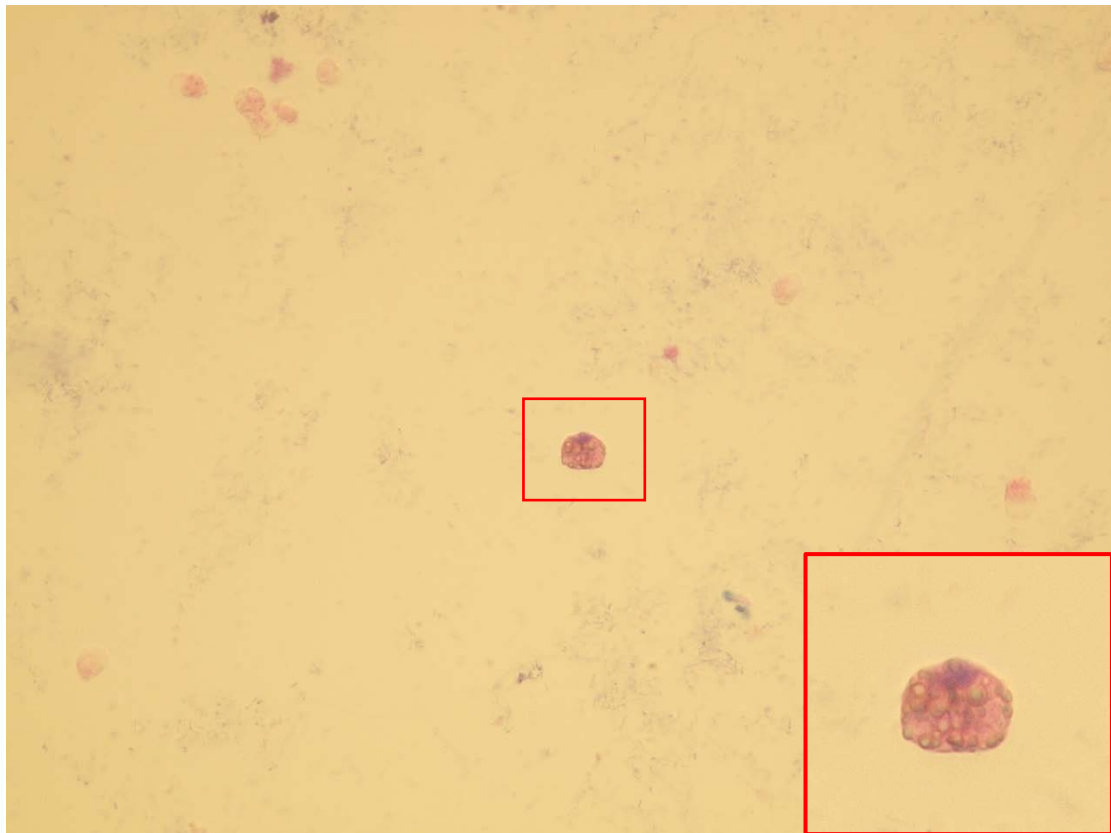


**WBC including fat-Microscopic picture of native sediment**





**WBC including fat- FUS-2000 big picture**



**WBC including fat-Microscopic picture of stained sediment**

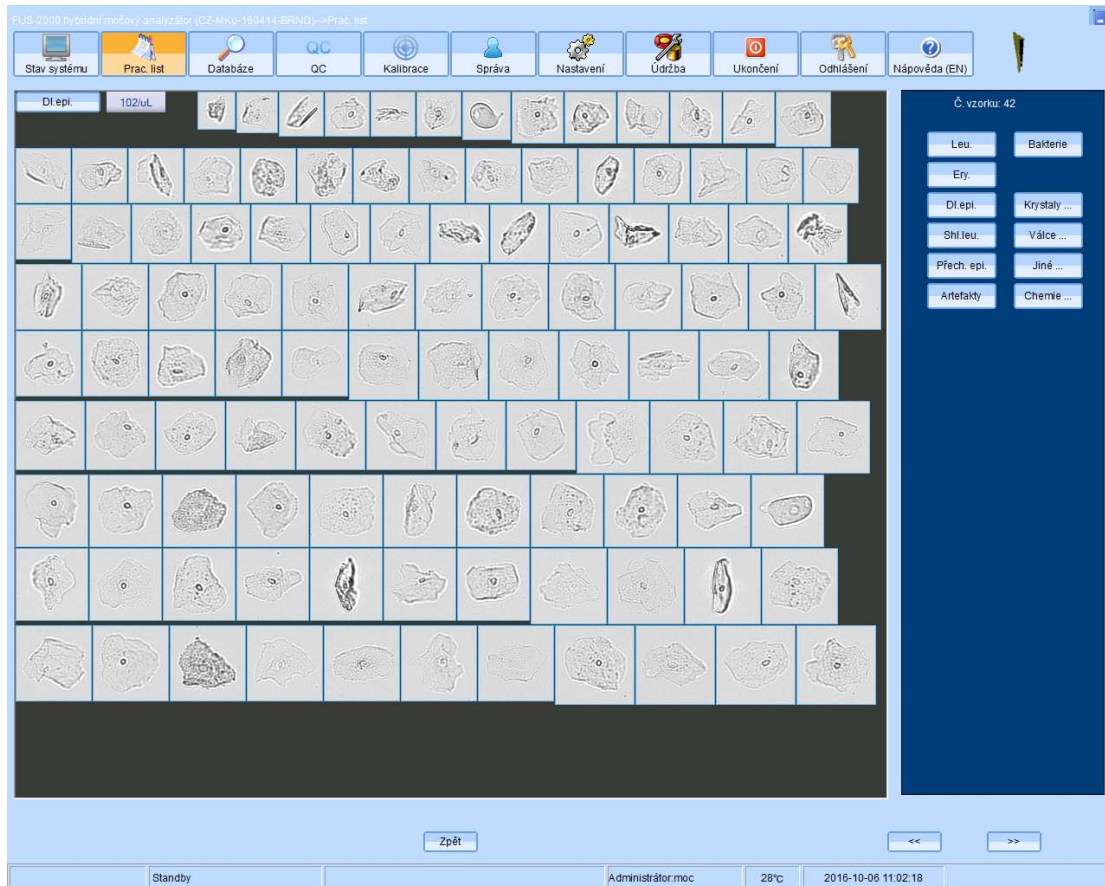


## Epithelial cells

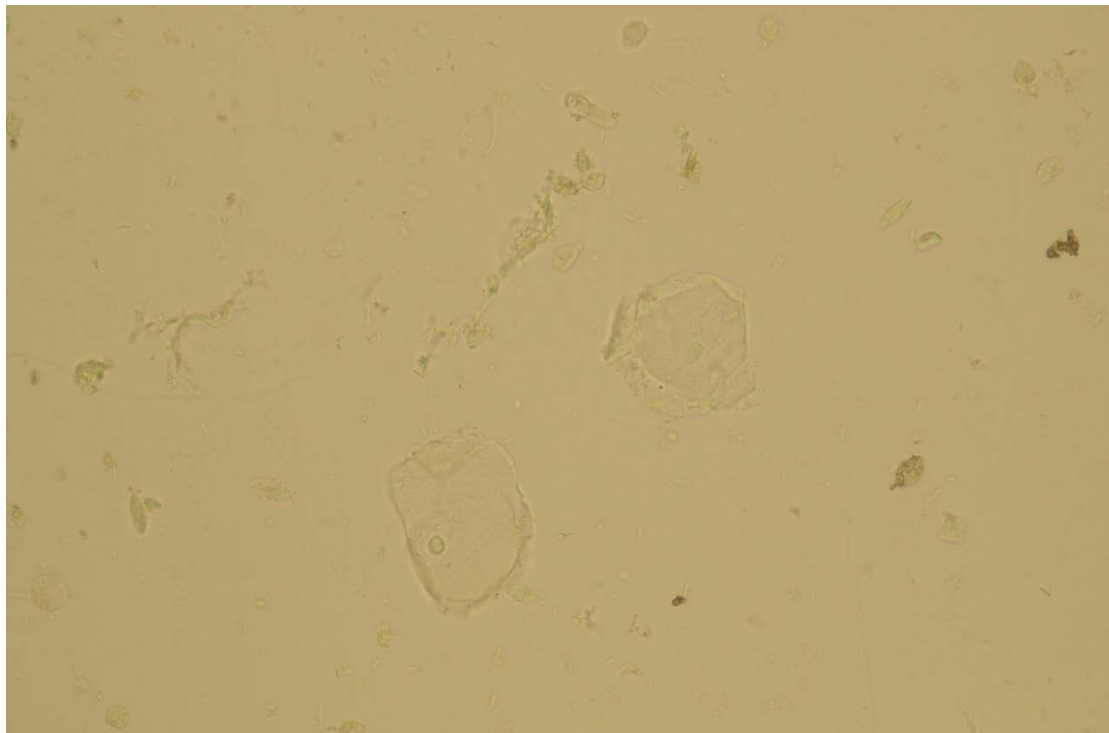
Desquamated epithelial cells in urine are mostly from urinary system such as tubules, renal pelvis, ureter, urinary bladder, urethra, etc. Squamous epitheliums desquamated from vagina can mix into urine. Inside of the renal tubules is covered by the renal tubular cuboidal epitheliums; lower ureteral, bladder, urethra and vagina surfaces are covered with stratified squamous epitheliums. Lesions of these parts would cause increase of epithelial cells in urine.

1. Squamous epithelial cells originate from the surface of external orifice of urethra and vulva. They are the largest epithelial cells in urine. They are flat as fish scales, irregular in shape often with curling edges. They are large, about 30-50  $\mu\text{m}$  in diameter. The nucleus is small, round or ovoid. Sometimes there are 2 or more small nuclei. Complete keratinized cells have smaller nuclei, which may even be invisible. Small amount of squamous epithelial cells can appear in healthy people urine, rare in males' urine and slightly more in adult females' urine (about 5 times of that in males' urine). If a lot of squamous epitheliums appear together with increased number of WBCs, there could be urinary tract inflammation. Squamous epithelial cells in samples from the female vaginal secretions have generally no clinical significance. In cases of *gardnerella vaginalis* infection, the squamous epithelial cells are sometimes entirely covered with cocco bacilli forming so called "clue cells".

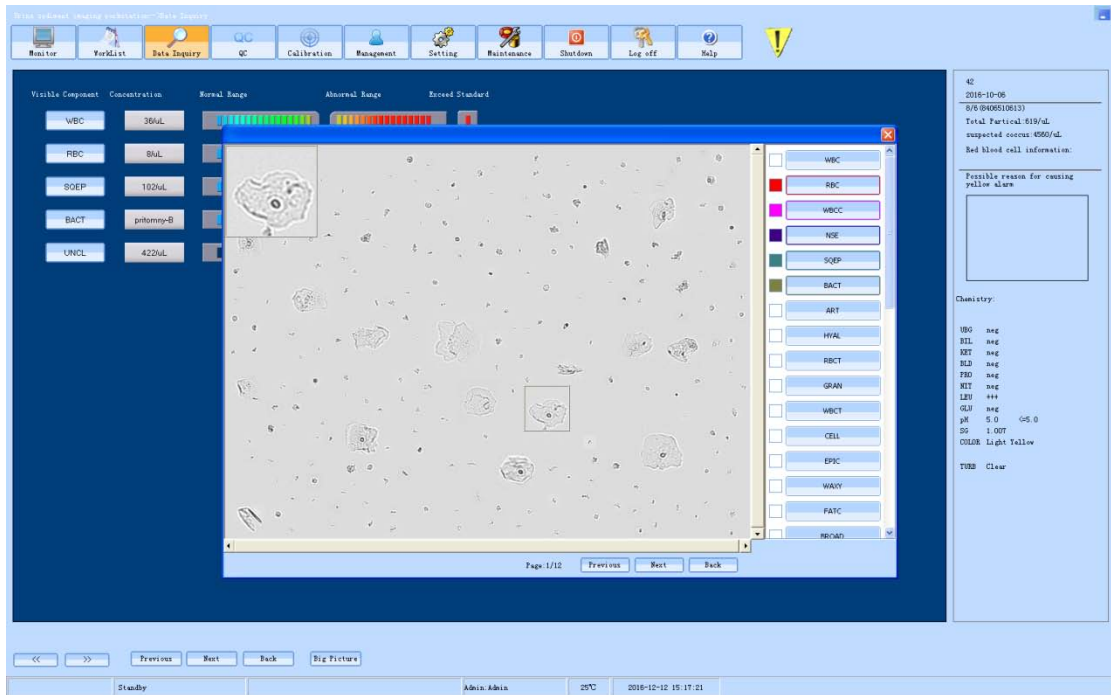
## Squamous Epithelial Cells



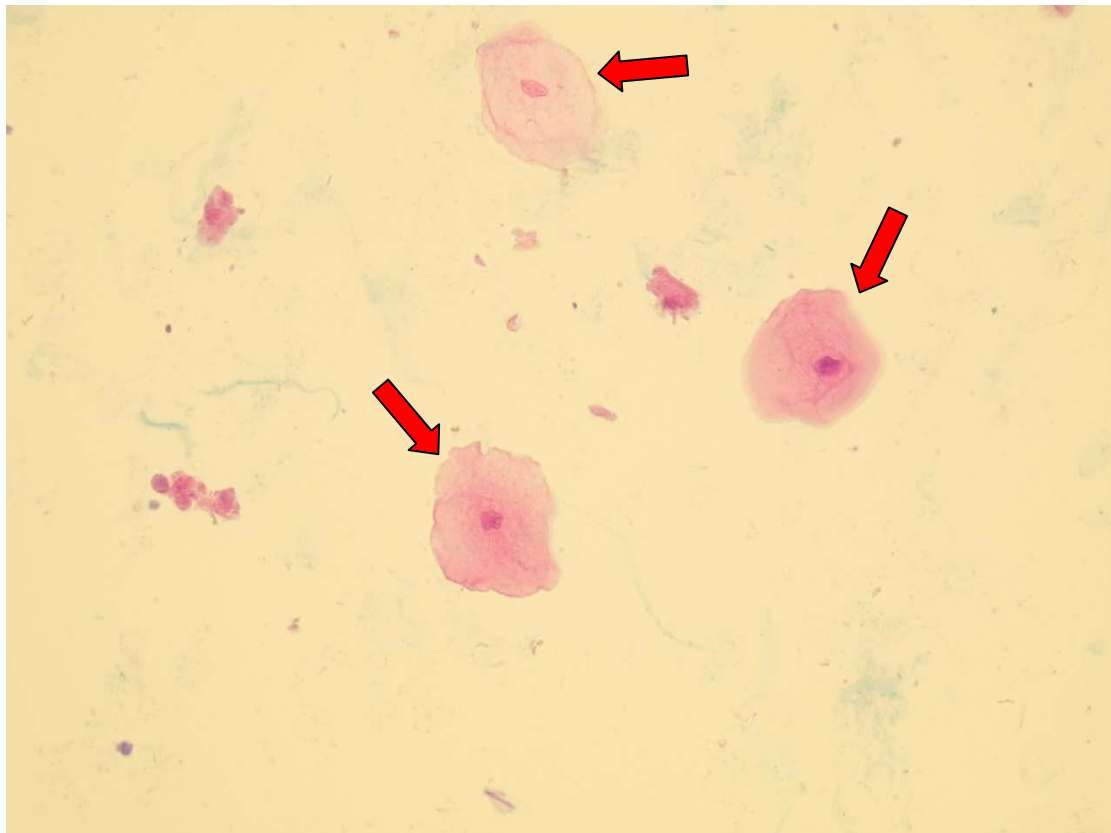
**Squamous epithelial cells- FUS-2000 isolated picture**



**Squamous epithelial cells -Microscopic picture of native sediment**



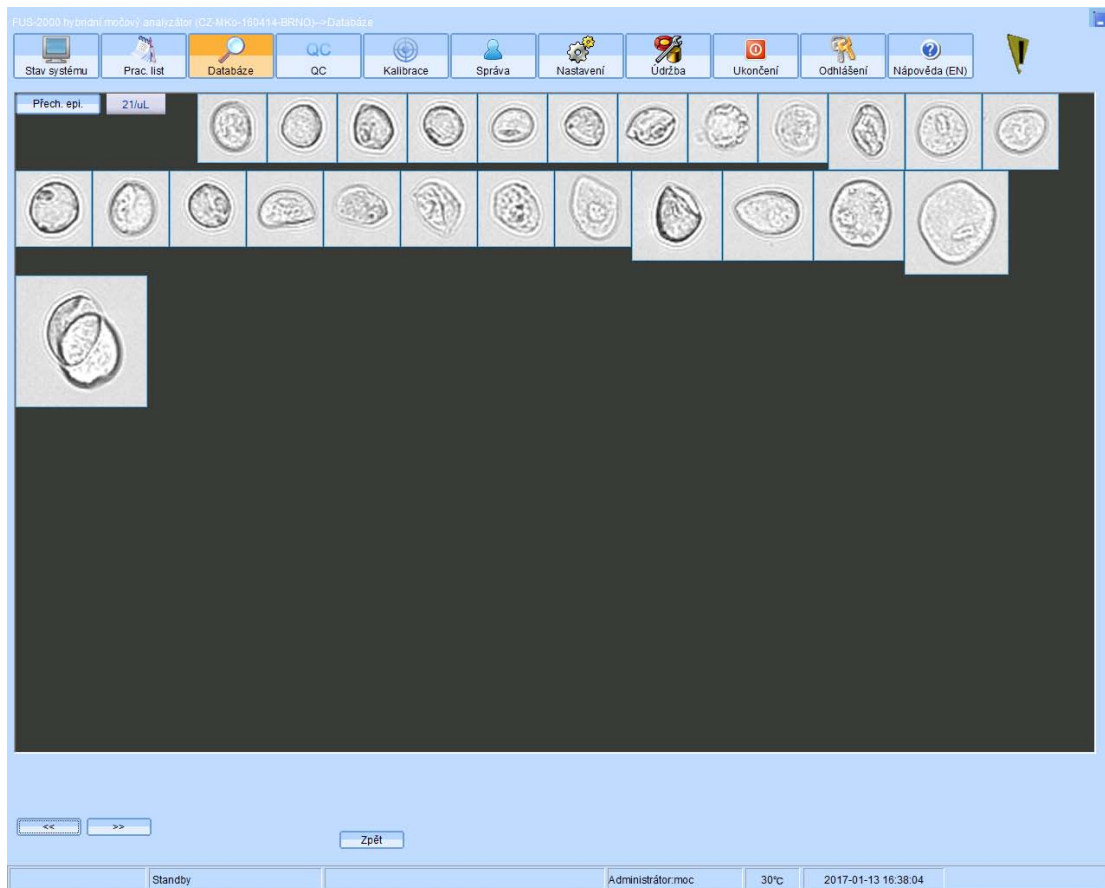
**Squamous epithelial cells- FUS-2000 big picture**



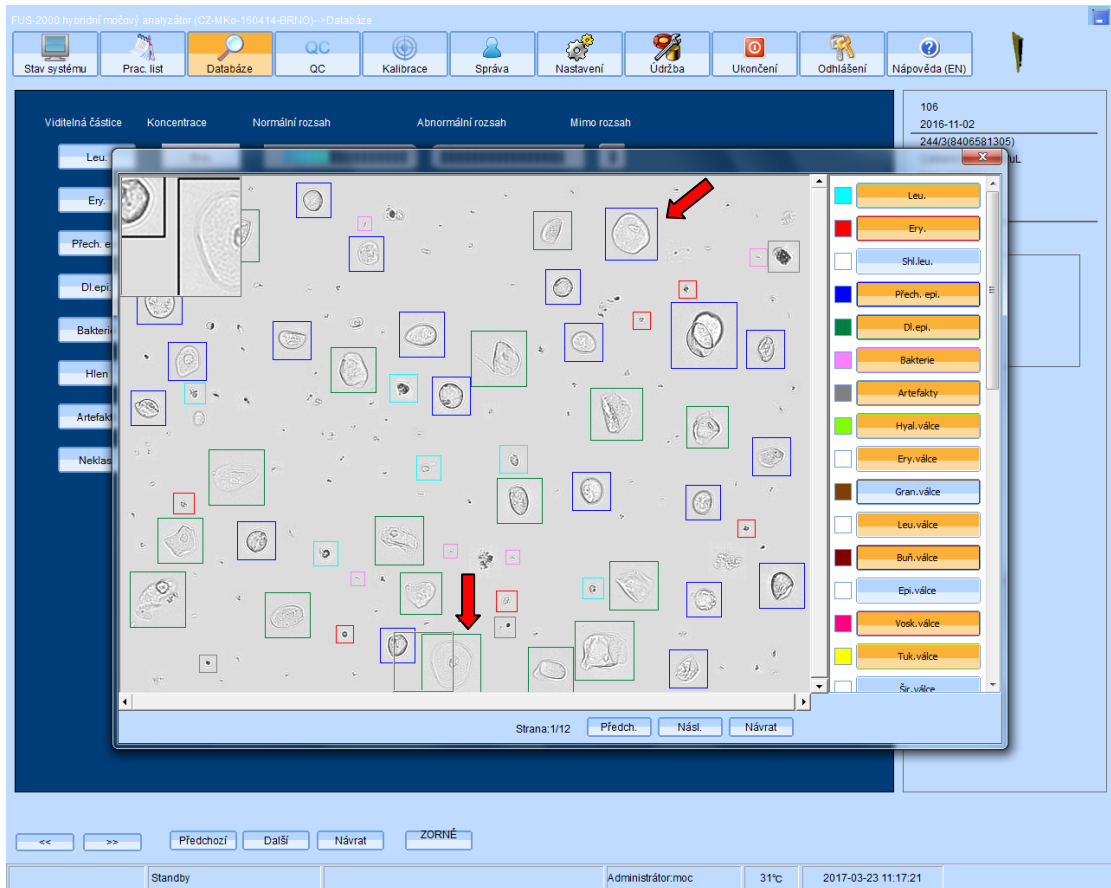
**Squamous epithelial cells -Microscopic picture of stained sediment**

2. Transitional epithelial cells come from the renal pelvis, ureter and bladder. Limited amount of transitional epithelial cells is of no obvious clinical significance. They may have two nuclei. If there is a large amount of cells with multiple nuclei in the finding, the cause may be urothelial carcinoma.
- a) Superficial transitional epithelial cells are mostly big round epithelial cells. If desquamated from engorged organs, the cell bodies would be larger, about 4-5 times of WBCs. They are irregular round. The nucleus is relatively small and is often in the middle of the cell. If desquamated from contracted organs, the cell bodies would be smaller, about 2-3 times of WBCs. They are round with bigger nucleus in the middle of the cells. In cystitis patients, the cells can flake off accompanied with increased WBCs.
  - b) Intermediate transitional epithelial cells are in various sizes of 20-40 $\mu$ m length, often in fish-shape, pear-shape, tadpole-shape, also known as the caudate epitheliums. The nucleus is big, eccentric and in round or oval shape. This kind of cells usually originate from the renal pelvis, so it is called renal pelvis epithelial cells; sometimes they originate from the ureter and bladder neck and when these parts have inflammation, the cells would flake off massively. Increase of intermediate transitional cells often suggests pyelonephritis.
  - c) Basal transitional epithelial cells are also known as small round epithelial cells, at the bottom or deep layers of transitional epithelium. It is round and small, a little bit bigger than renal tubular epitheliums, 2-3 times of WBCs. The nucleus is big but slightly smaller than the one of renal tubular epithelium and cells are slightly rich in cytoplasm. Due to their origins, which are ureters, bladder and urethra, the massive fall-off or flake-off suggests the inflammation or necrosis lesions from the renal pelvis to urethral. Too many basal transitional epithelial cells suggest that the inflammation is quite serious.
  - d) The cells with two nuclei are also categorized as transitional epithelial cells. Large number of cells with two nuclei or asymmetric cells can be found in urine from patients with transitional cell (urothelial) carcinomas.

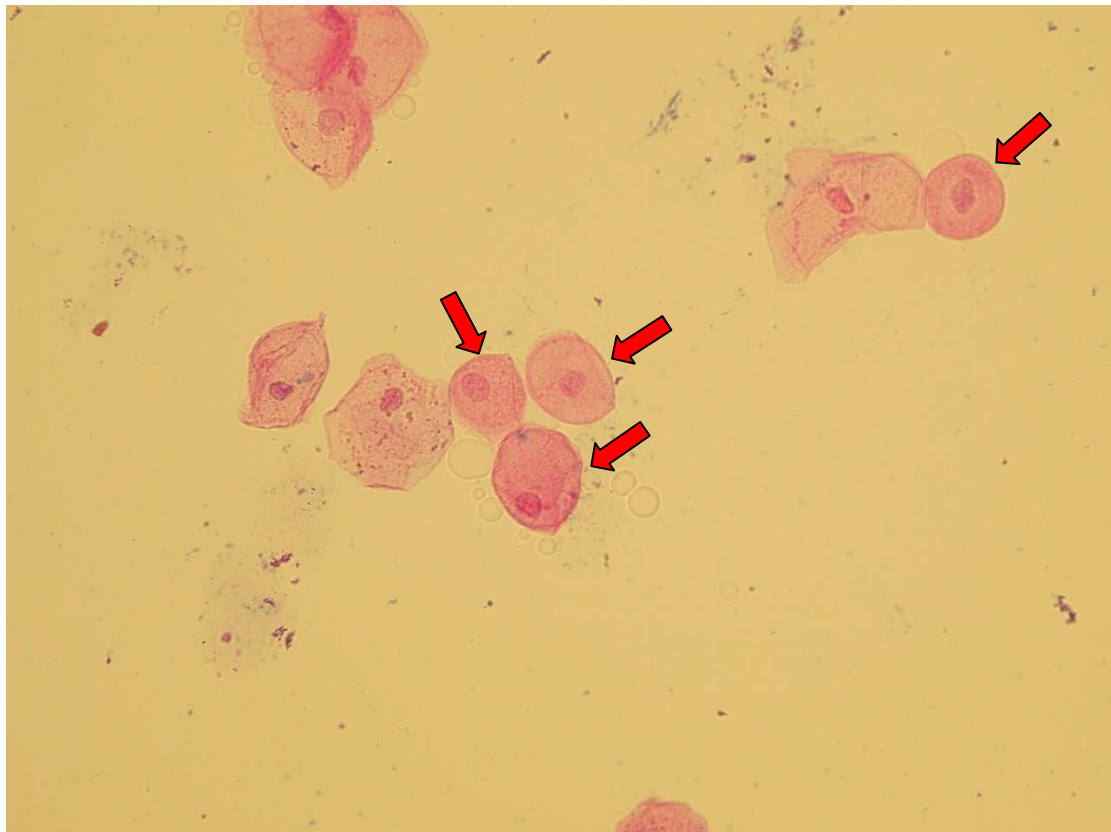
## Big round Epithelial Cells (Superficial Transitional Epithelial Cells)



**Big round epithelial cells- FUS-2000 isolated picture**

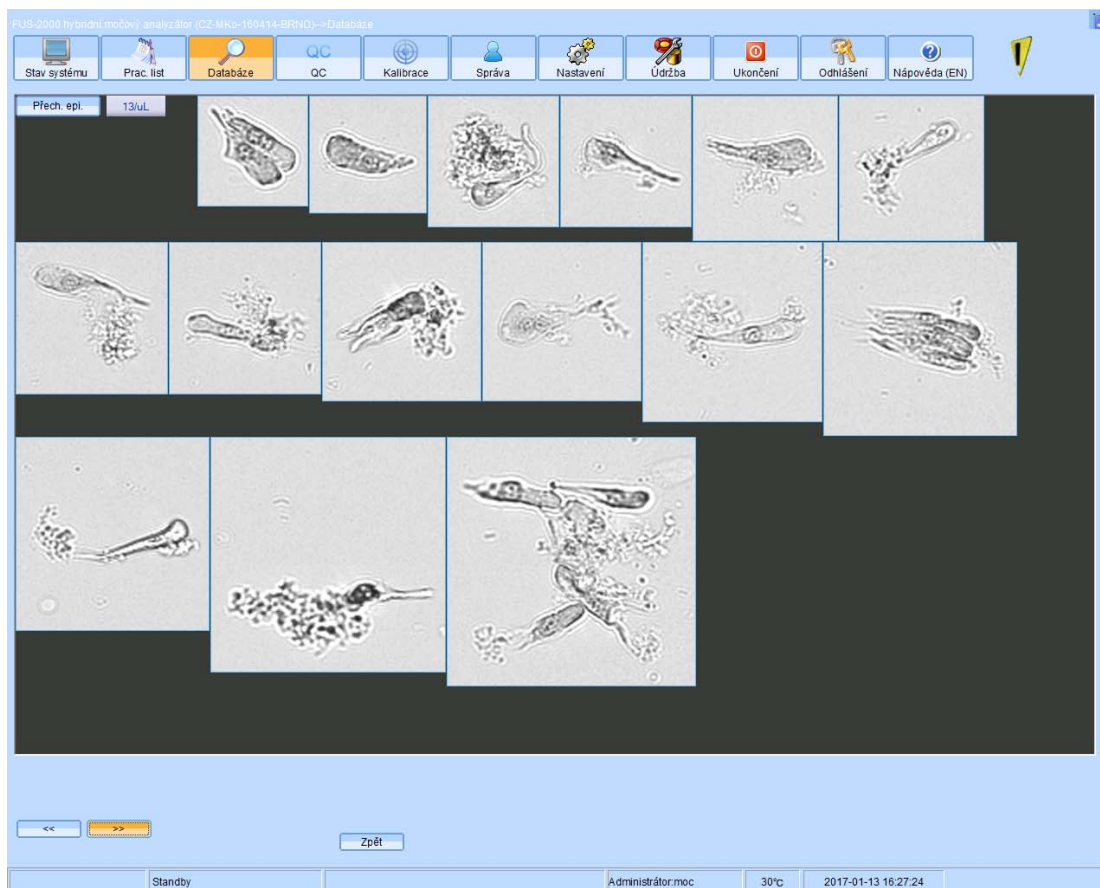


**Big round epithelial cells- FUS-2000 big picture**




**Big round epithelial cells -Microscopic picture of stained sediment**

## Caudate Transitional Epithelial Cells (Intermediate Transitional Epithelial Cells)

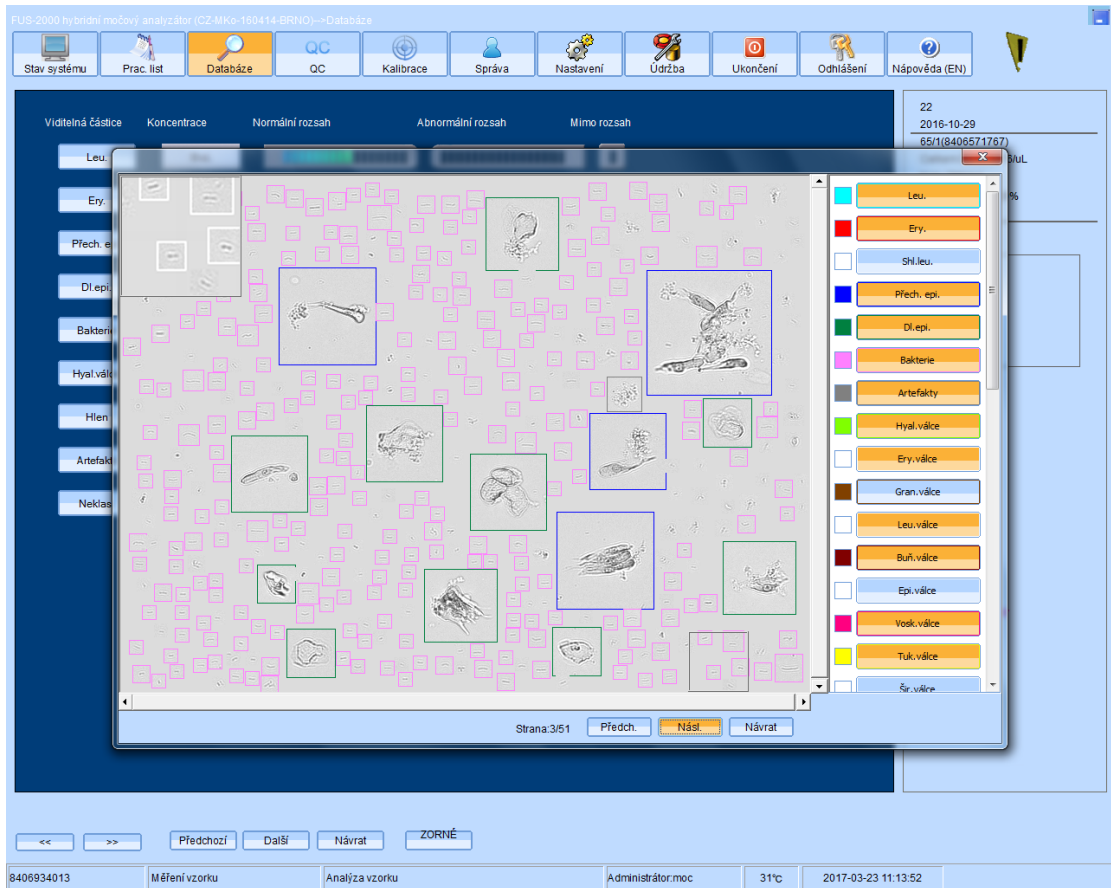


Caudate transitional epithelial cells- FUS-2000 isolated picture

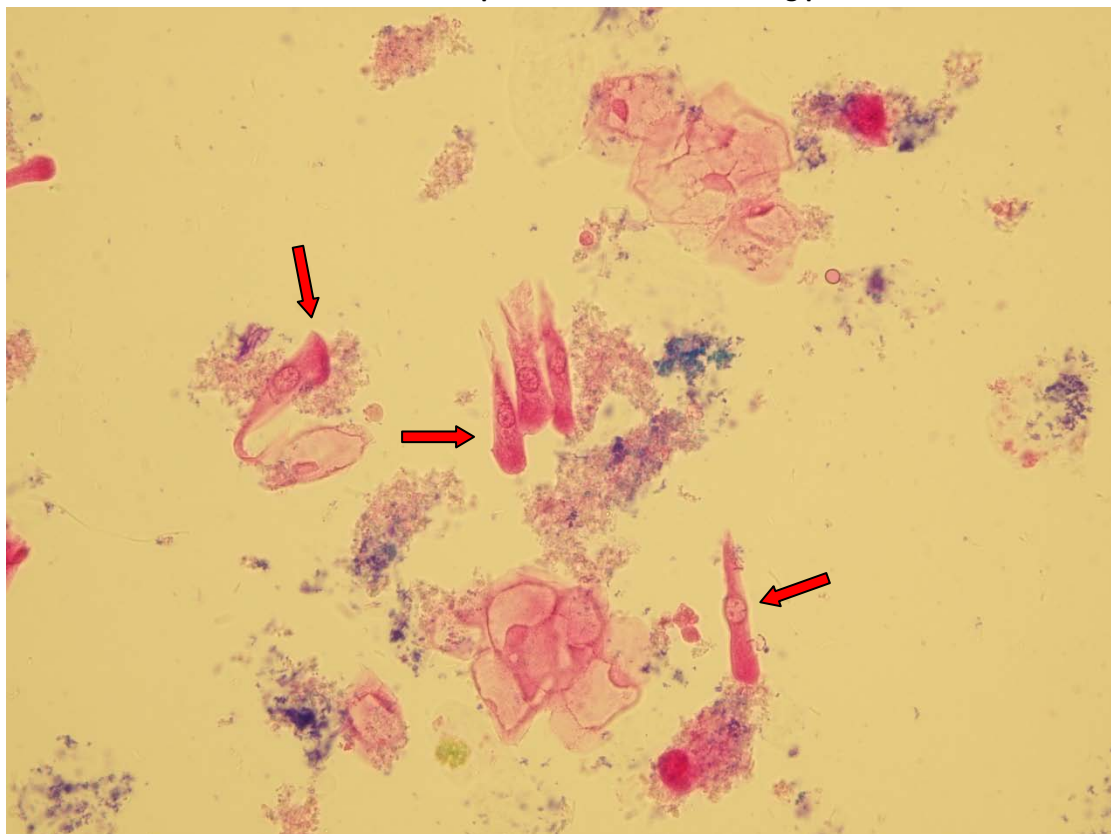


Caudate transitional epithelial cells -Microscopic picture of native sediment





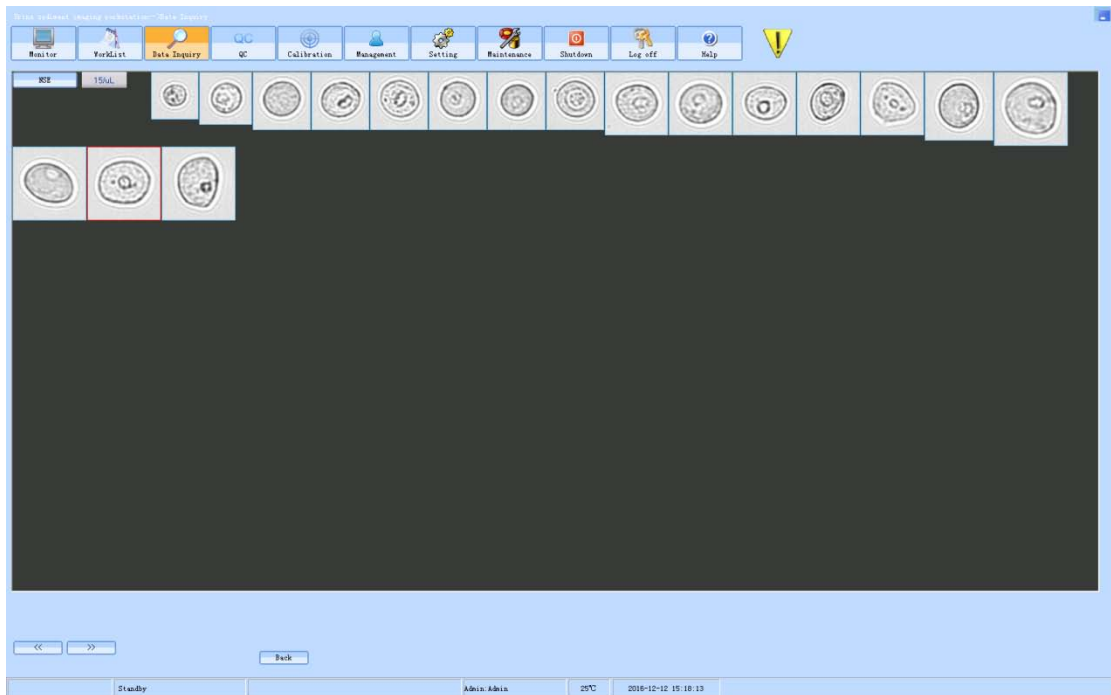
**Caudate transitional epithelial cells- FUS-2000 big picture**




**Caudate transitional epithelial cells -Microscopic picture of stained sediment**



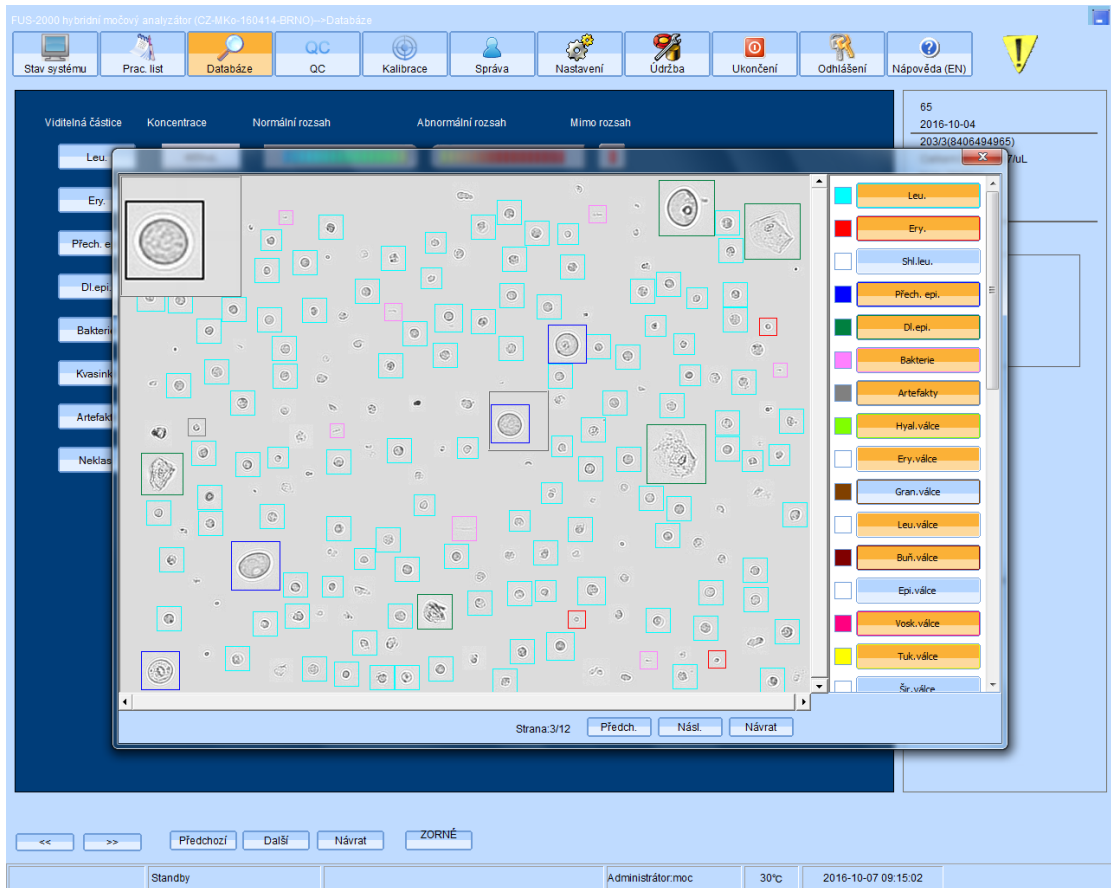
## Small Round Epithelial Cells (Basal Transitional Epithelial Cells)



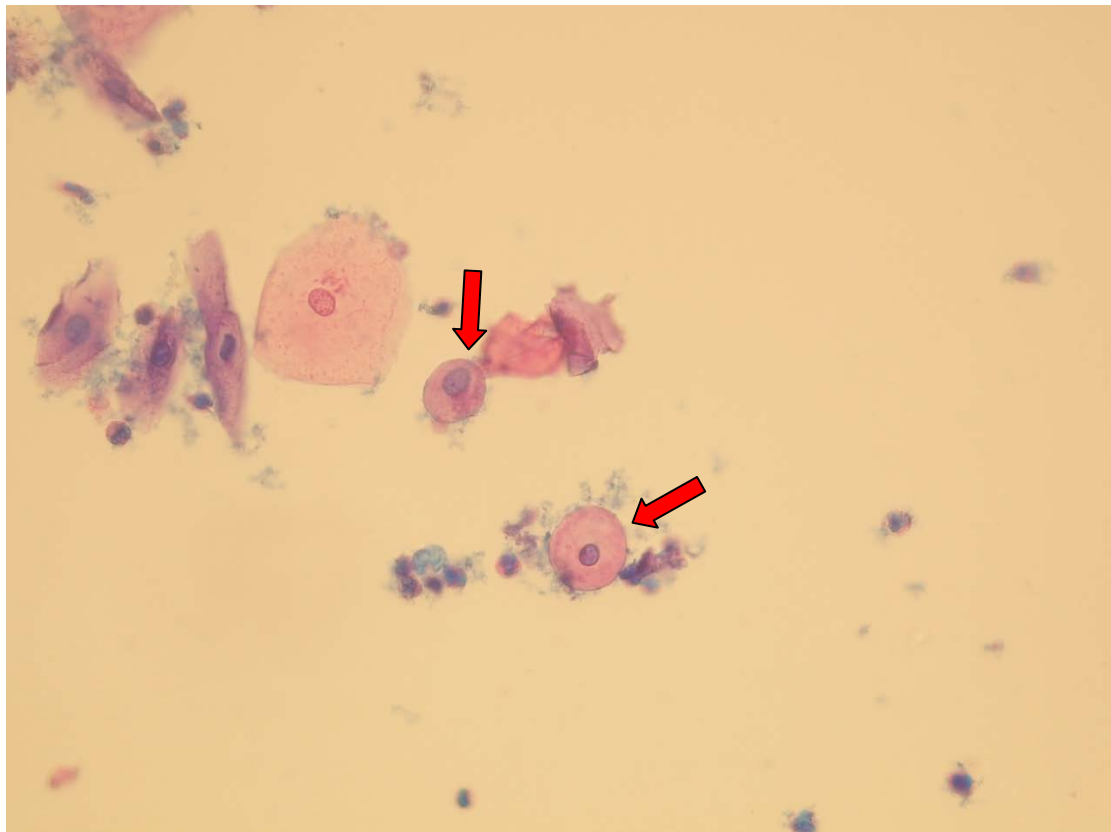
Small round epithelial cells- FUS-2000 isolated picture



Small round epithelial cells -Microscopic picture of native sediment

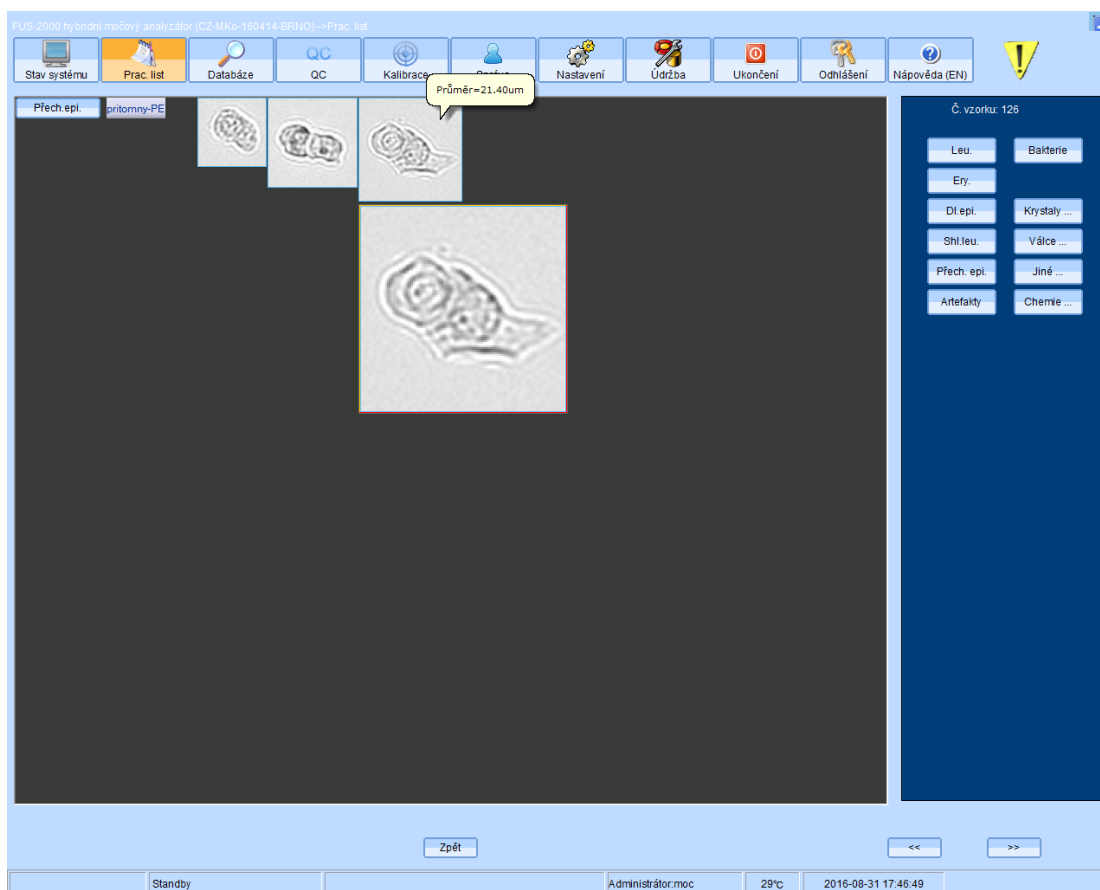


**Small round epithelial cells- FUS-2000 big picture**

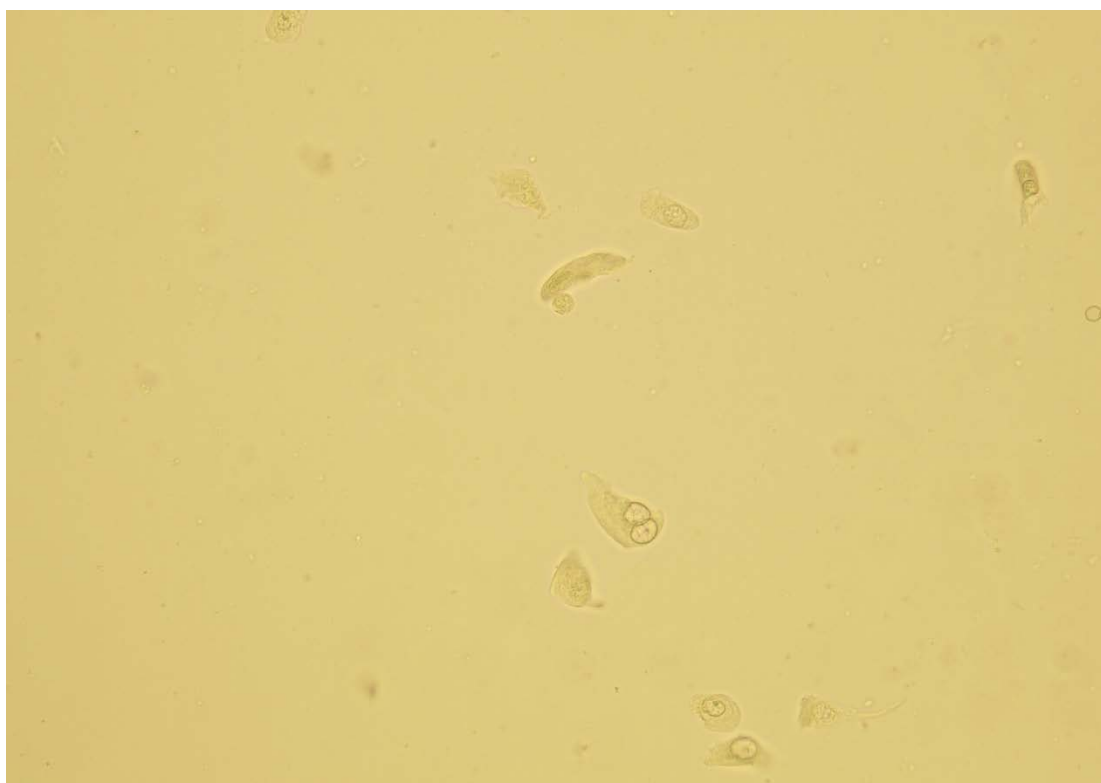


**Small round epithelial cells -Microscopic picture of stained sediment**

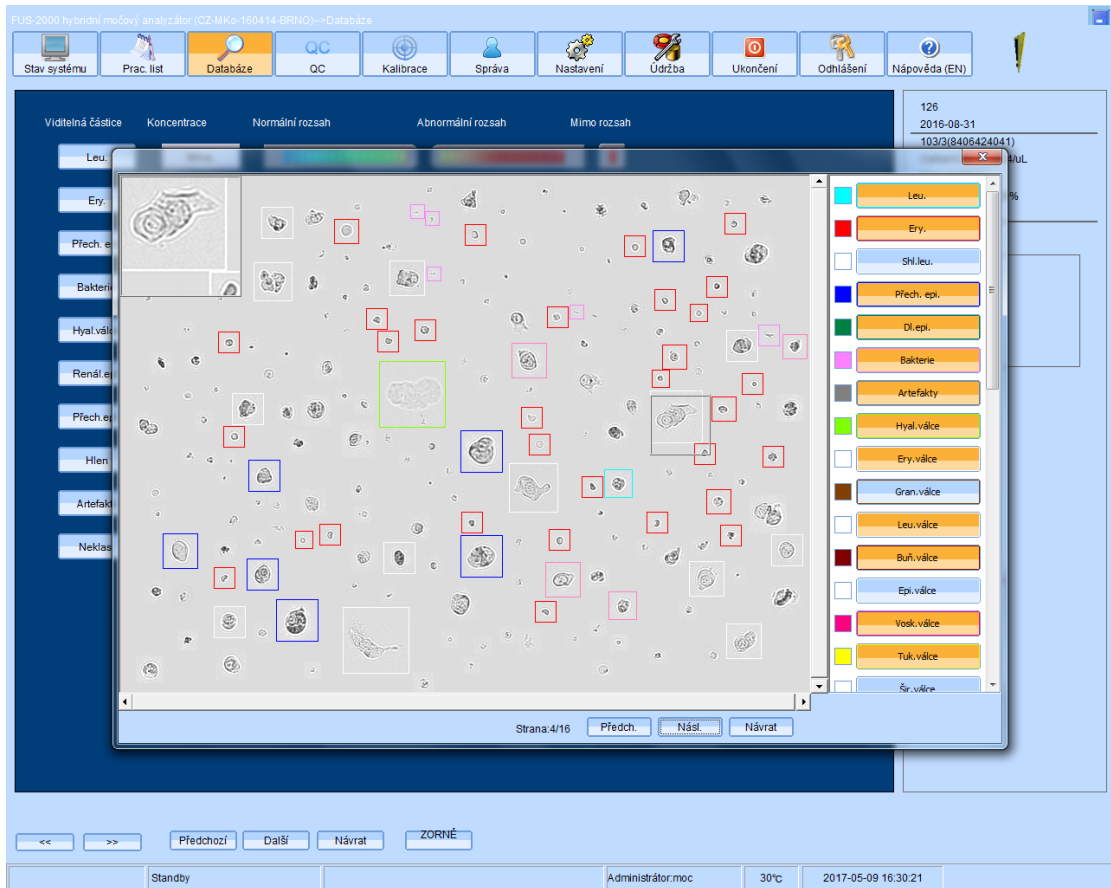
## Transitional epithelial cells with two nuclei



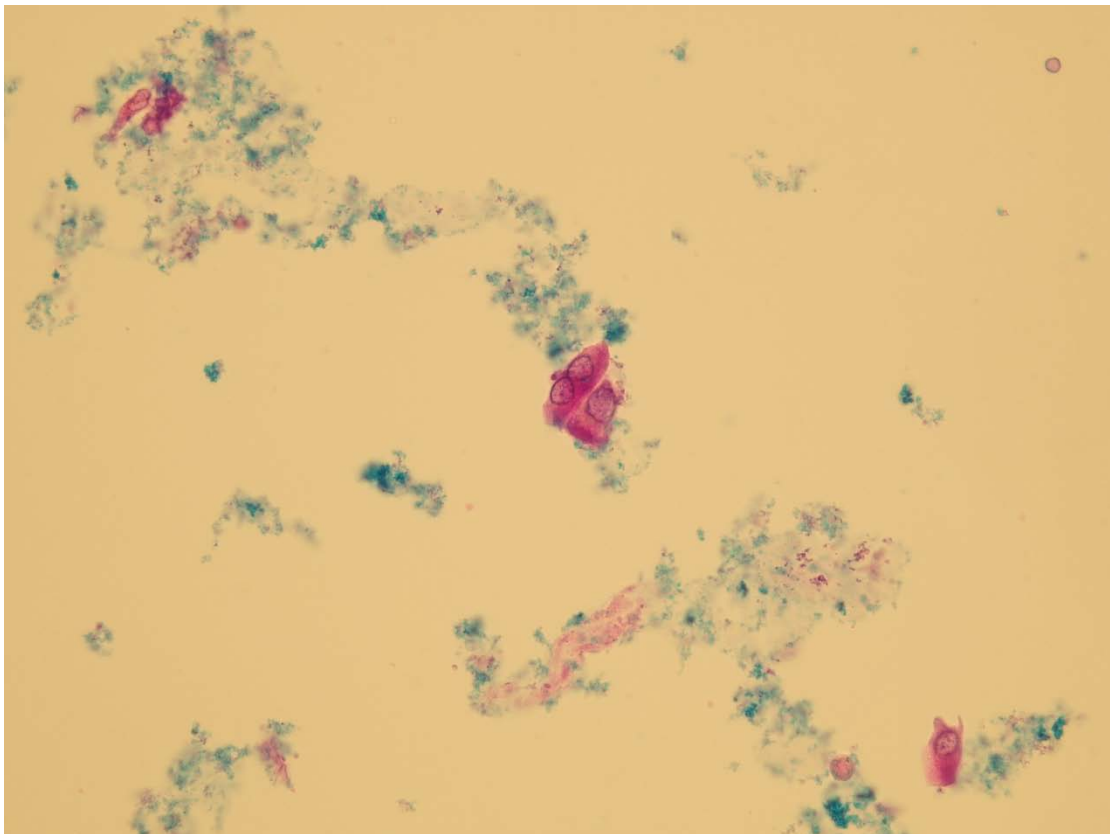
Transitional epithelial cells with two nuclei- FUS-2000 isolated picture



Transitional epithelial cells with two nuclei -Microscopic picture of native sediment



**Transitional epithelial cells with two nuclei- FUS-2000 big picture**

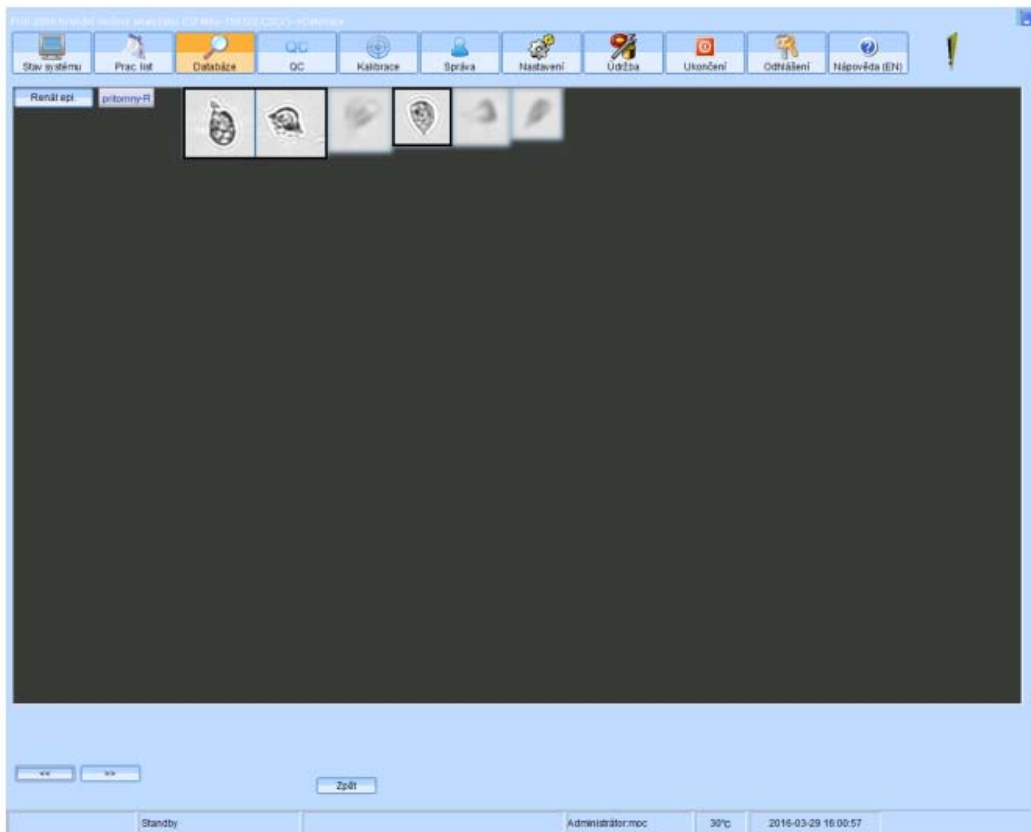


**Transitional epithelial cells with two nuclei -Microscopic picture of stained sediment**

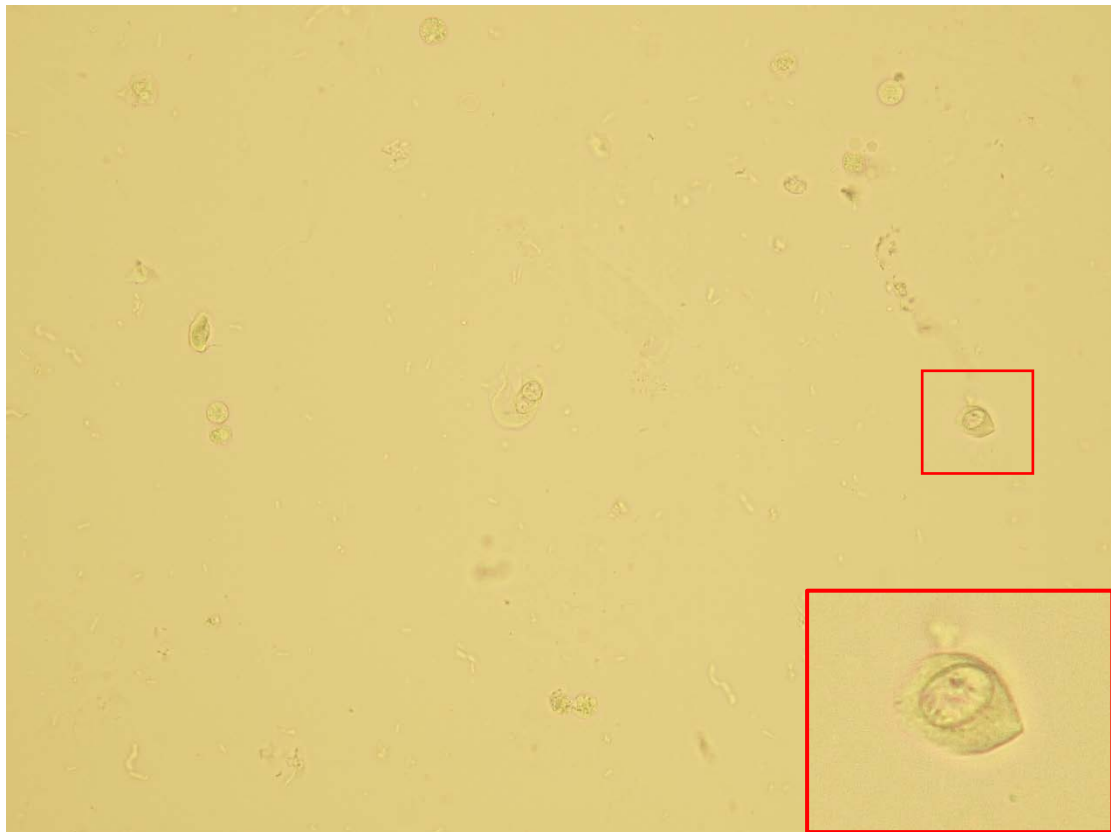3. Renal tubular epithelial cells

- a) Renal tubular epithelial cells come from the kidney tubules distal and proximal convoluted tubular cuboidal epitheliums with various forms and are easily deformed in the urine. They are typically polyhedral, irregular in shape, or can be small rounded. Their morphology is similar to WBCs, with diameter of 15-20 $\mu$ m, about 1.5-2 times bigger than neutrophils. Single nucleus is clear and large in round shape, mostly eccentric. The nucleus membranes are mostly thick and clearly visible. There are irregular granules in the cytoplasm. Sometimes too large number of particles can make the nucleus invisible. Renal tubular epitheliums are also known as renal epitheliums.
- i. The shape and size of renal tubular epitheliums are similar to small round epitheliums of basal layer transitional epithelium cells. They share the same name of small round epithelial cells when they are not differed.
  - ii. **Renal epithelial fragments** constitute of several renal cells of collecting duct origin. Their presence in urine is considered to be clinically severe and indicates heavy renal tubular damage.
- b) Oval fat bodies: in certain chronic nephropathy, renal tubular epithelial cells are prone to fatty degeneration. There are many fat particles or fat droplets of varied quantities and uneven distributions appearing in the cytoplasm.

## Renal Tubular Epithelial Cells

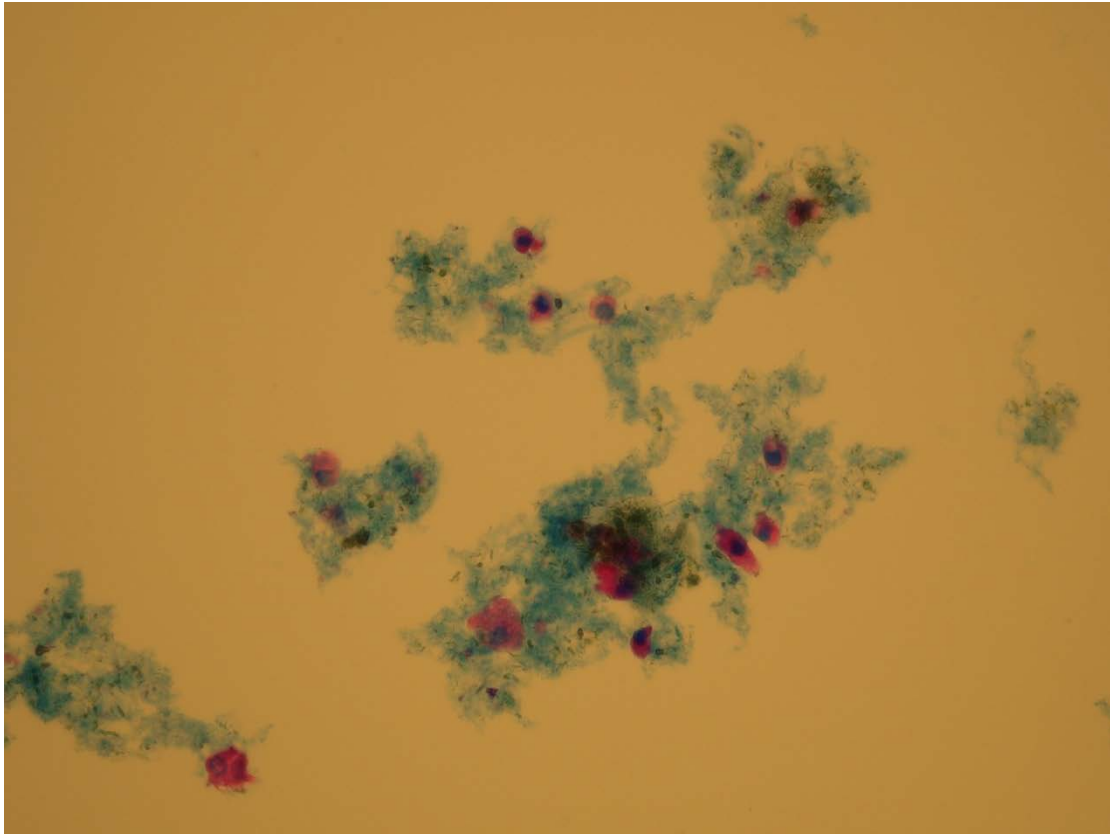


**Renal tubular epithelial cells - FUS-2000 isolated picture**



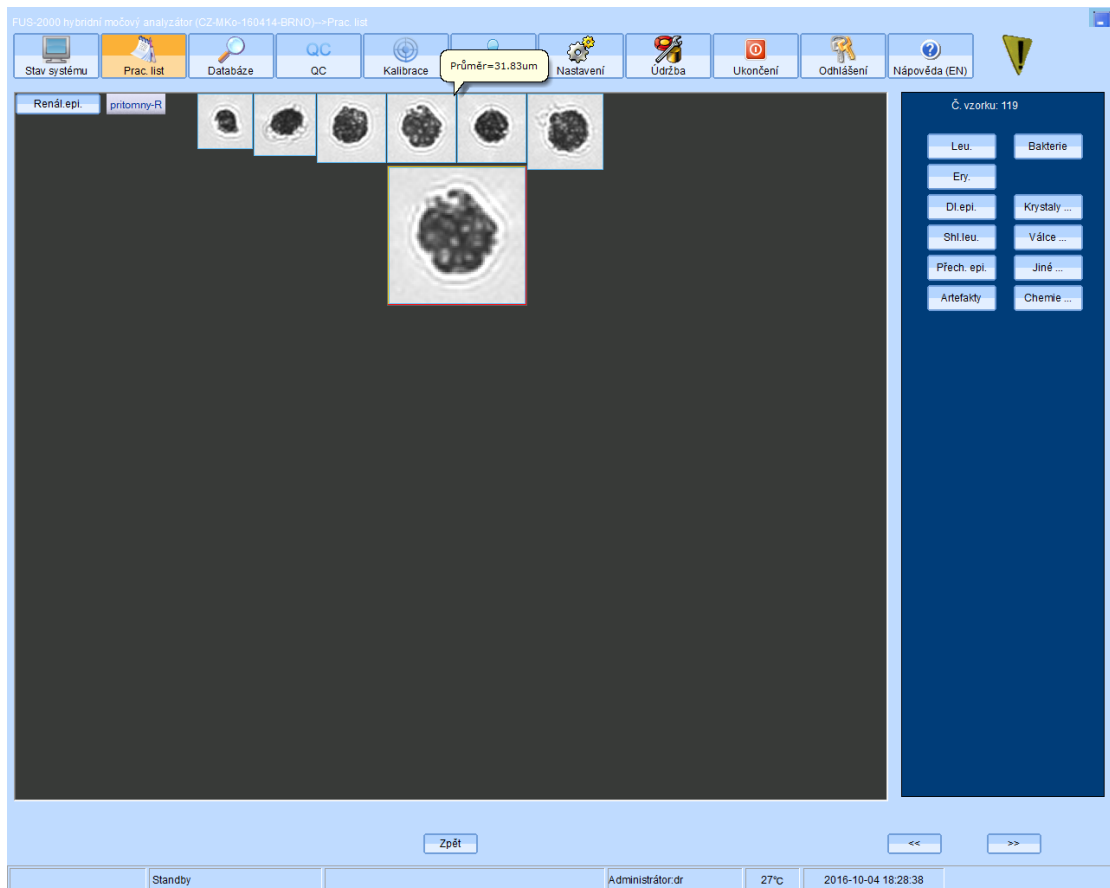
**Renal tubular epithelial cells-Microscopic picture of native sediment**



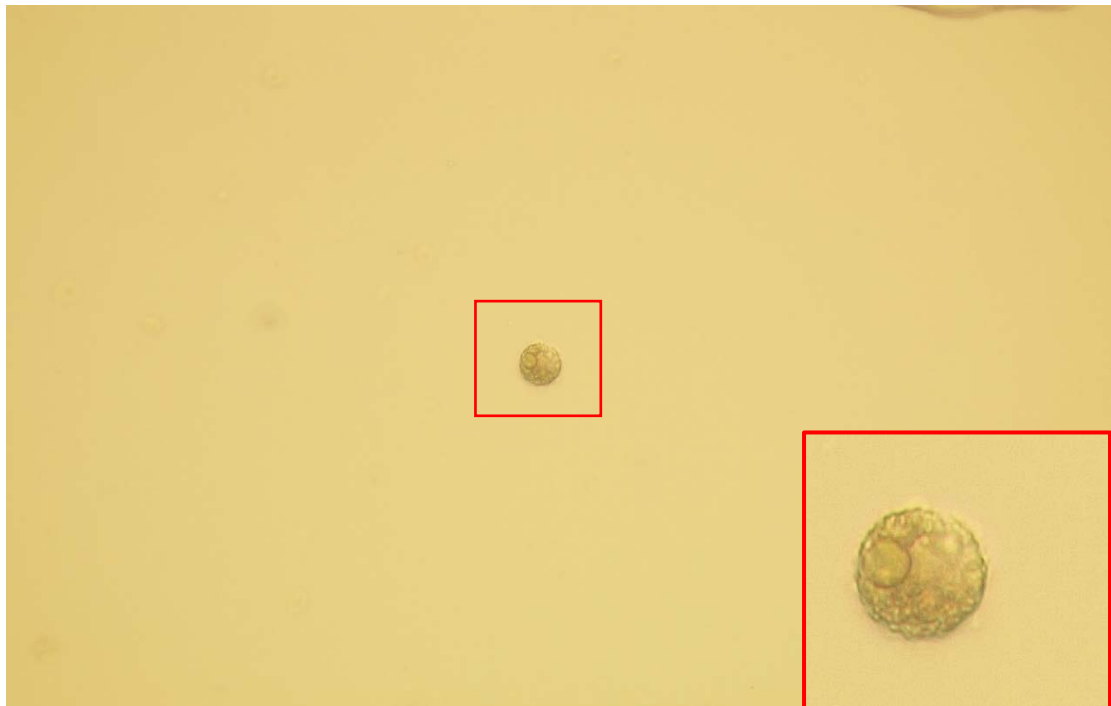


**Renal tubular epithelial cells-Microscopic picture of stained sediment**

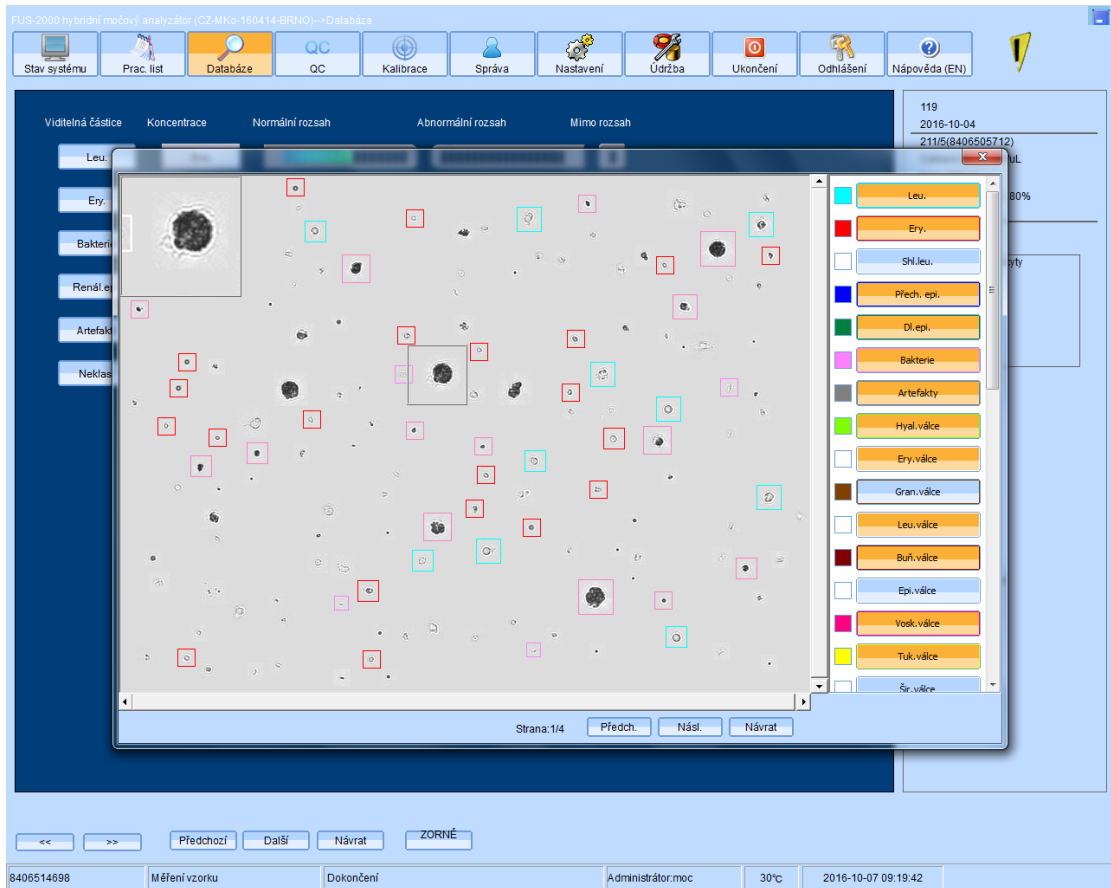
## Oval Fat Bodies



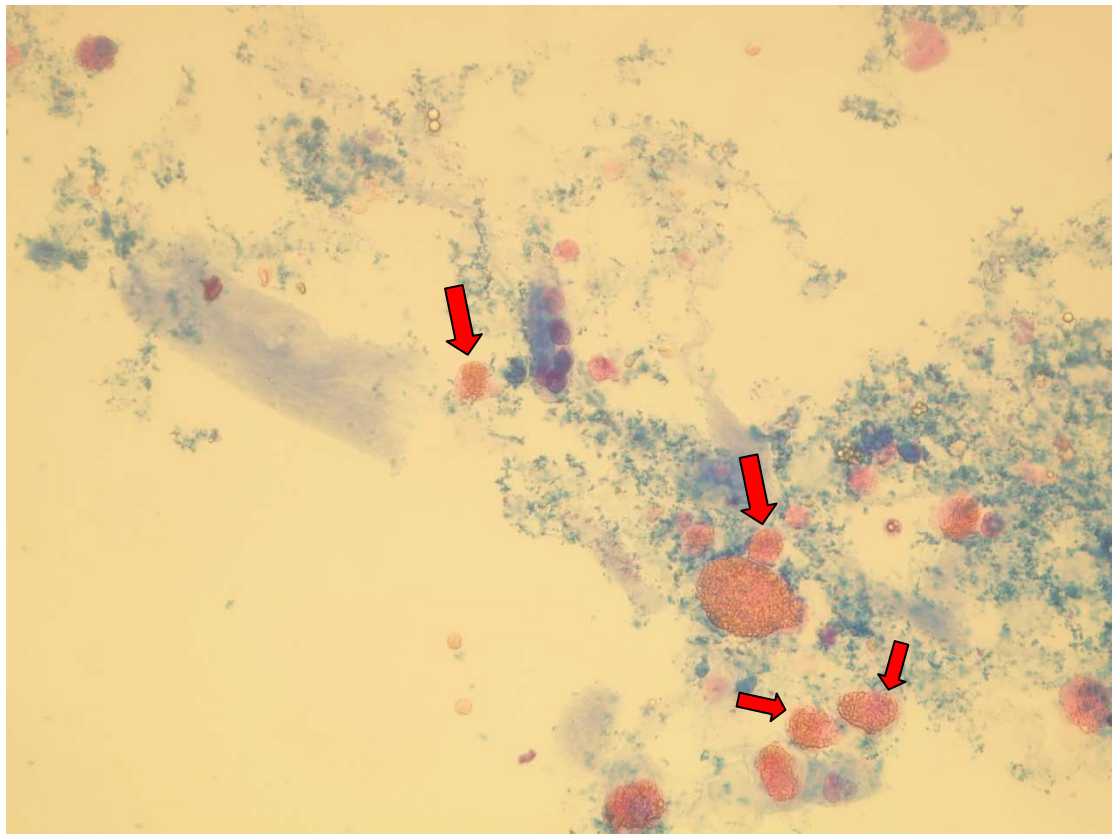
Oval fat bodies - FUS-2000 isolated picture



Oval fat bodies-Microscopic picture of native sediment



**Oval fat bodies - FUS-2000 big picture**



**Oval fat bodies-Microscopic picture of stained sediment**

4. Other epithelial cells

- a) Columnar epithelial cells are mostly cylindrical of 15-30 $\mu$ m long, with wide top and narrow end. The nuclei are eccentric in the lower or bottom part of the cells. The origins are the prostate, the middle part of urethra, urethral glands, seminal vesicle, part of the cervix and uterus. It is generally difficult to find in urinalysis. If during natural micturition more columnar epithelial cells appear, it suggest chronic urethritis or cystitis, chronic pancreatitis. In the area of medical intubation or other mechanical stimulation and operation, the columnar epithelial cells also increased significantly and pieces fall off.
- b) Multinucleated giant cells: it is generally considered that the origin is transitional epithelial cells of the urinary tract. They are mostly polygonal cells with 10 times size difference 20-200  $\mu$ m. There are several to dozens of oval nuclei. Such cells in the urine are found in viral infection patients of measles, chicken pox, mumps, and epidemic hemorrhagic fever and so; can also be found in patients of urinary tract inflammation and postoperative patients treated with radiotherapy.

## Casts

A. Formation condition of casts: casts are the cylindrical aggregates of proteins, cells and their breakdown products set in the renal tubules, collection tubes.

There are formation conditions of casts:

- 1) Existence of albumin and Tamm-Horsfall protein (T-H protein) in crude urine: this is the base material and primary factor to form casts. T-H protein is most likely to form casts.
- 2) Urine concentration and acidification function of renal tubules: concentration function can achieve increased concentration of proteins and salt which are needed for the formation of casts. Acidification function can stimulate the proteins to further denature, set and subside.
- 3) Alternated use of nephrons: it is helpful for the formation and excretion of casts. The "rest" state nephrons in the lesion part would store the urine. The store time is enough to form casts. When these nephrons recover to work and to excrete urine, the formed casts would be excreted together with the urine.

Urine sample may contain more than one type of cast. The casts go through different stages of development with increasing time in the kidney tubule: cell cast → granular cast → waxy cast.

Singular casts may have mixed morphology such as granular at one end and waxy at the other.

Casts	Compositions	Clinical significances
Hyaline Cast	T-H protein, albumin, a few chloride	Occasionally seen in healthy people Increase: parenchymal lesion of the kidney
RBCs Cast	Cast matrix + RBCs	Bleeding of renal glomerulus or tubules
WBCs Cast	Cast matrix + WBCs	Kidney infection disease
Epithelial cells Cast	Cast matrix+Epithelial cells	Renal tubules disease
Granular Cast	Cast matrix + decomposed products of degenerated cells	Parenchymal lesion of the kidney accompanied with nephron stasis
Waxy Cast	Evolved from fine granular casts	Severe lesion of renal tubules with poor prognosis
Fatty Cast	Cast matrix + fat droplets	Renal tubular injury, fatty degeneration of renal tubular epithelial cells
Renal Failure Cast	Derived from granular cast and waxy casts	Serious kidney disease with poor prognosis
Bacteria Cast	Cast matrix + Bacteria	Suppurative infection of the kidney
Yeast Cast	Cast matrix + Yeast	Mycotic infection
Bilirubin Cast	Cast matrix + Bilirubin crystals	Severe jaundice
Mixed cells Cast	Cast matrix + different cells and other compositions	Recurrent attacks of nephritis, bleeding, vascular necrosis, renal transplant rejection

1. Hyaline casts are also known as the glass casts, composed mainly of T-H protein and also

albumin and sodium chloride. They are colorless and transparent, and soluble in alkaline urine. Hyaline casts varies in sizes and are in cylindrical shape, often parallel in sides and rounded at ends (one end could be slightly tapering like tail).The texture is thin.

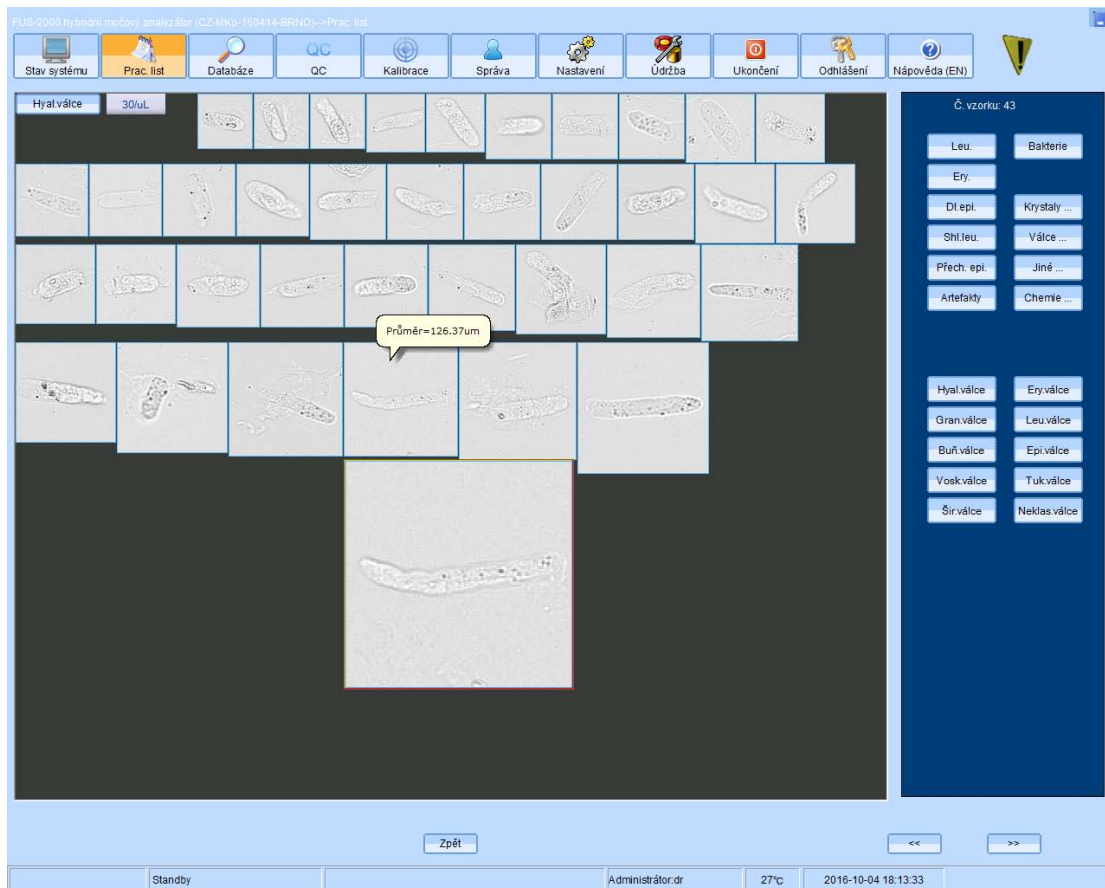
Hyaline casts can be divided into 2 types depending on if there are cells and granules inside:

- a) Simple hyaline casts: no granules or cells.
- b) Compound hyaline casts: containing a few granules or cells (less than 1/3 of the volume).


Hyaline casts appear in urine of healthy adults occasionally (0-a few/LP). When there is slight or temporary function impairment of the kidney, such as strenuous exercise, longtime fever, heart failure, anesthesia or taking diuretics, a small amount of hyaline casts would be present. Elderly people can also see increases of hyaline casts in urine. Significant increase of hyaline casts is found in renal parenchymal disease, such as acute or chronic glomerular nephritis, nephrotic syndrome, acute pyelonephritis, renal congestion, congestive heart failure and malignant hypertension. When acute glomerular nephritis happens, hyaline casts would appear together with other pathological casts. In the urine of patients with chronic interstitial nephritis, hyaline casts can be present in long-term and large amount. Late stage of nephritis can often see abnormally thick and wide hyaline casts, known as kidney-failure casts, one type of broad casts.



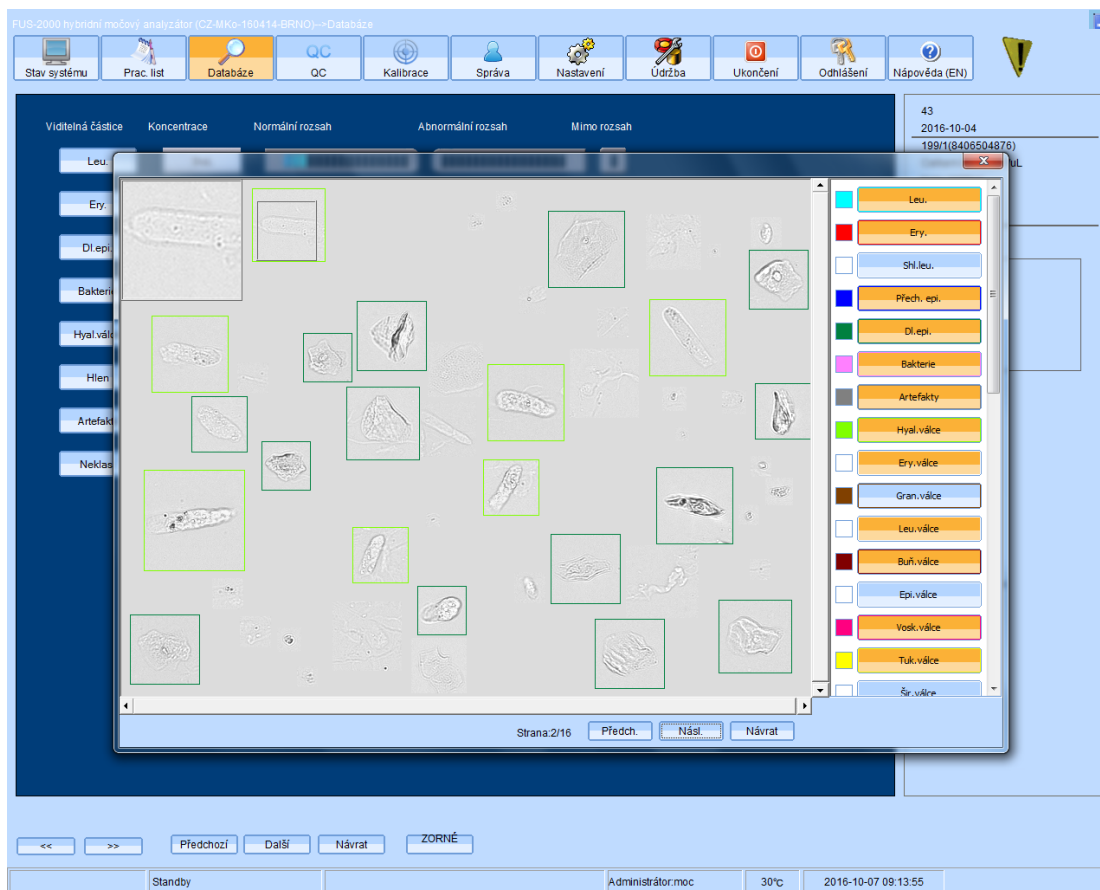
## Hyaline Casts



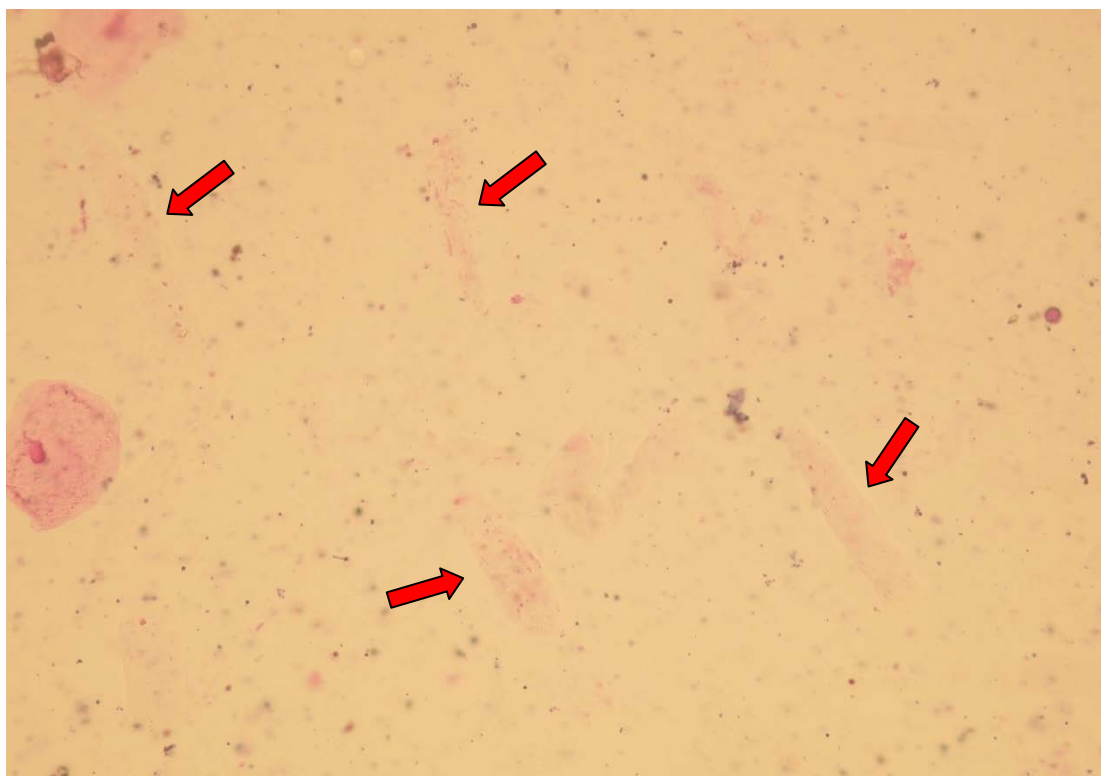
Hyaline casts - FUS-2000 isolated picture



## Hyaline casts-Microscopic picture of native sediment



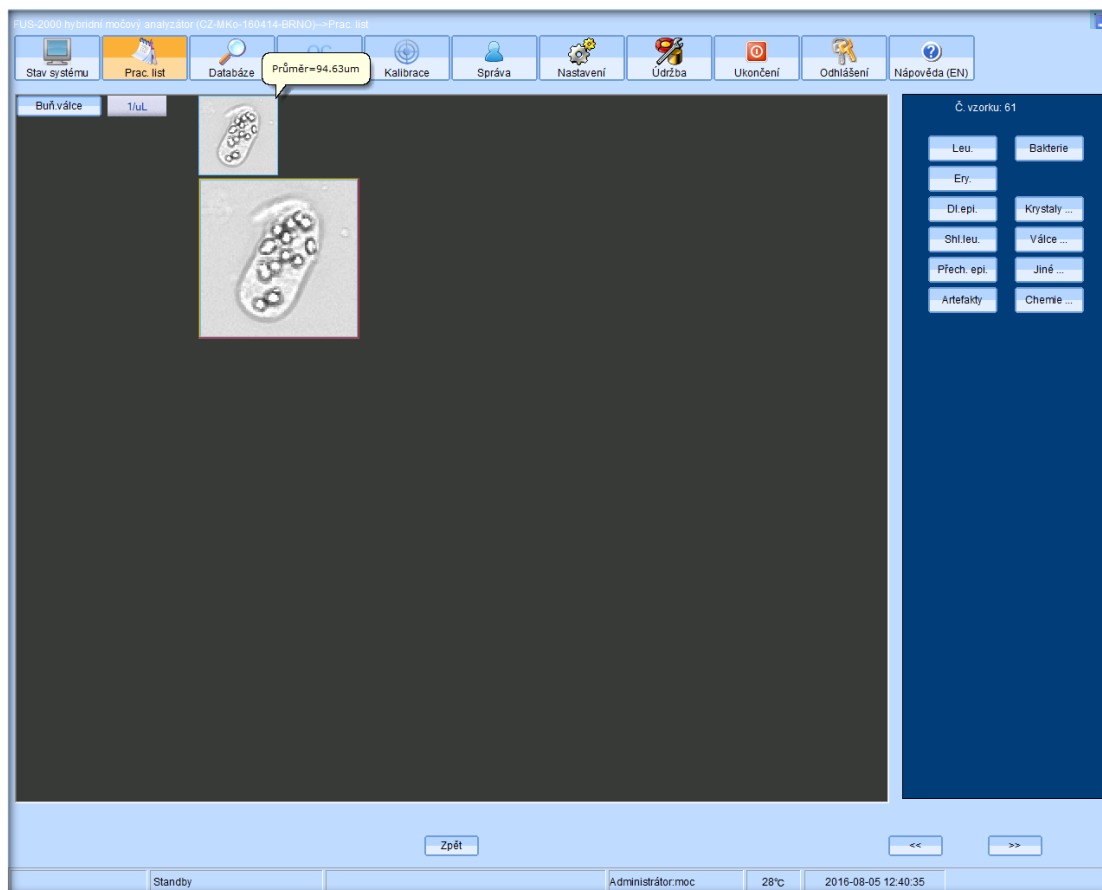
## Hyaline casts - FUS-2000 big picture



## Hyaline casts-Microscopic picture of stained sediment

2. Cell casts contain cells taking up more than 1/3 volume of the casts. Depending on cells types, cell casts can be divided into RBC casts, WBC casts and epithelia casts. If less than 1/3 volume, it can be called casts with cells, like casts with RBCs.
  - a) RBC casts' matrix are embedded with RBCs or their fragments. When there is renal infarction, RBC casts would degenerate to become wide and dark brown granular casts. If RBCs are dissolved or broken, RBC casts would become reddish brown blood casts or homogeneous hemoglobin casts. RBC casts are caused due to glomerular or tubular bleeding, seen in acute glomerular nephritis, acute attack of chronic glomerulonephritis, kidney hemorrhage, acute tubular necrosis, kidney transplant rejection, renal vein thrombosis, malignant hypertension and also seen in lupus nephritis, sub-acute endocarditis and IGA nephropathy. Hemoglobin casts are found in urine of patients with, acute renal tubular necrosis, renal hemorrhage or kidney transplant rejection.

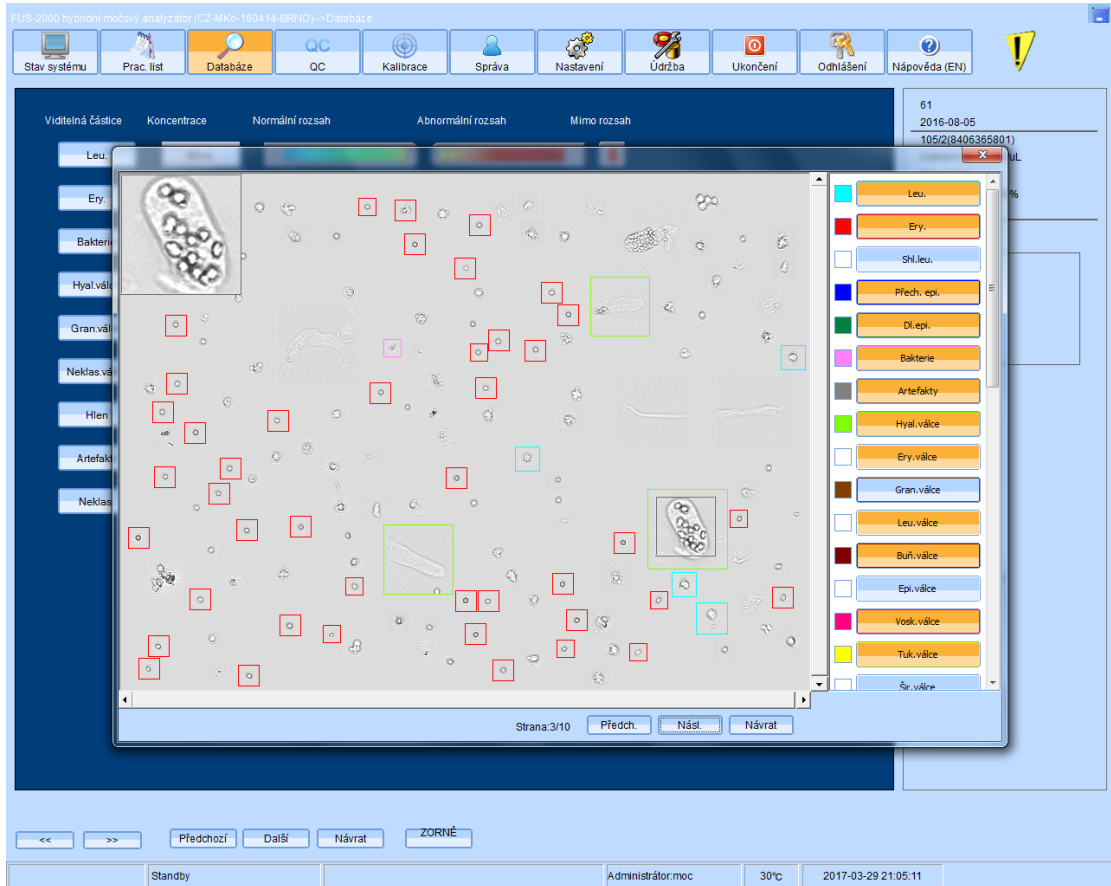
## RBC casts



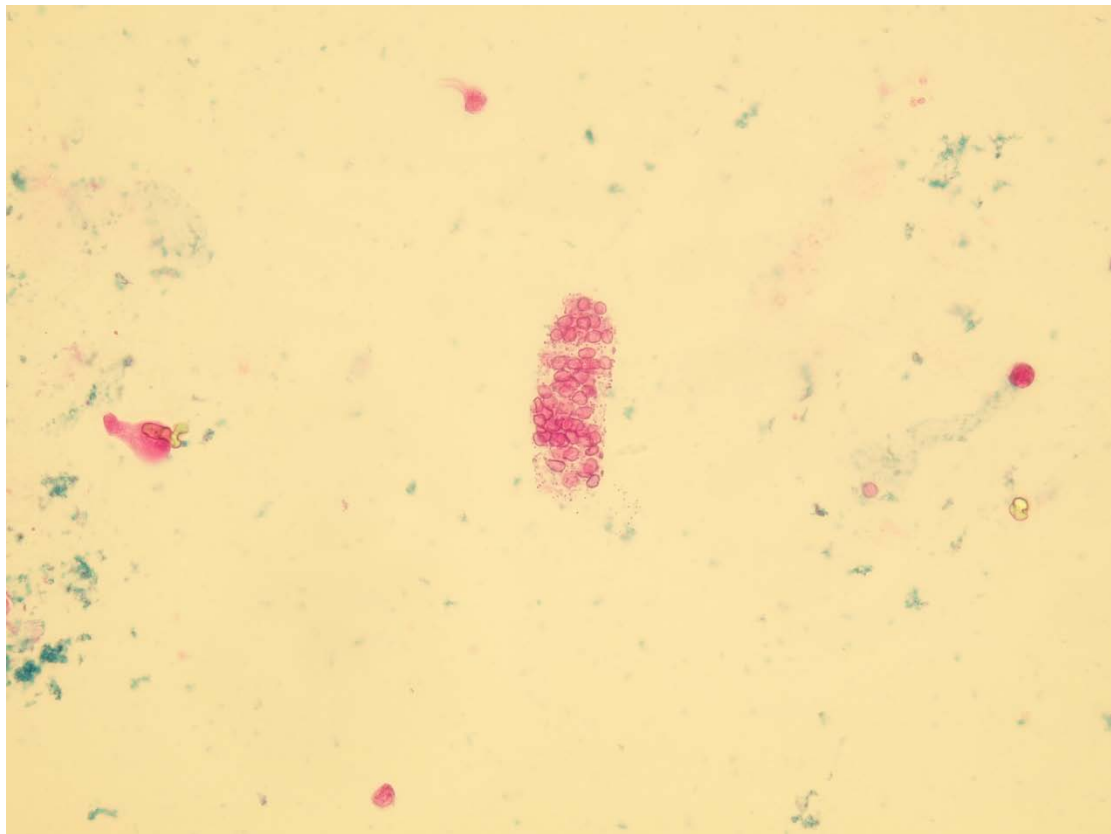
RBC casts - FUS-2000 isolated picture



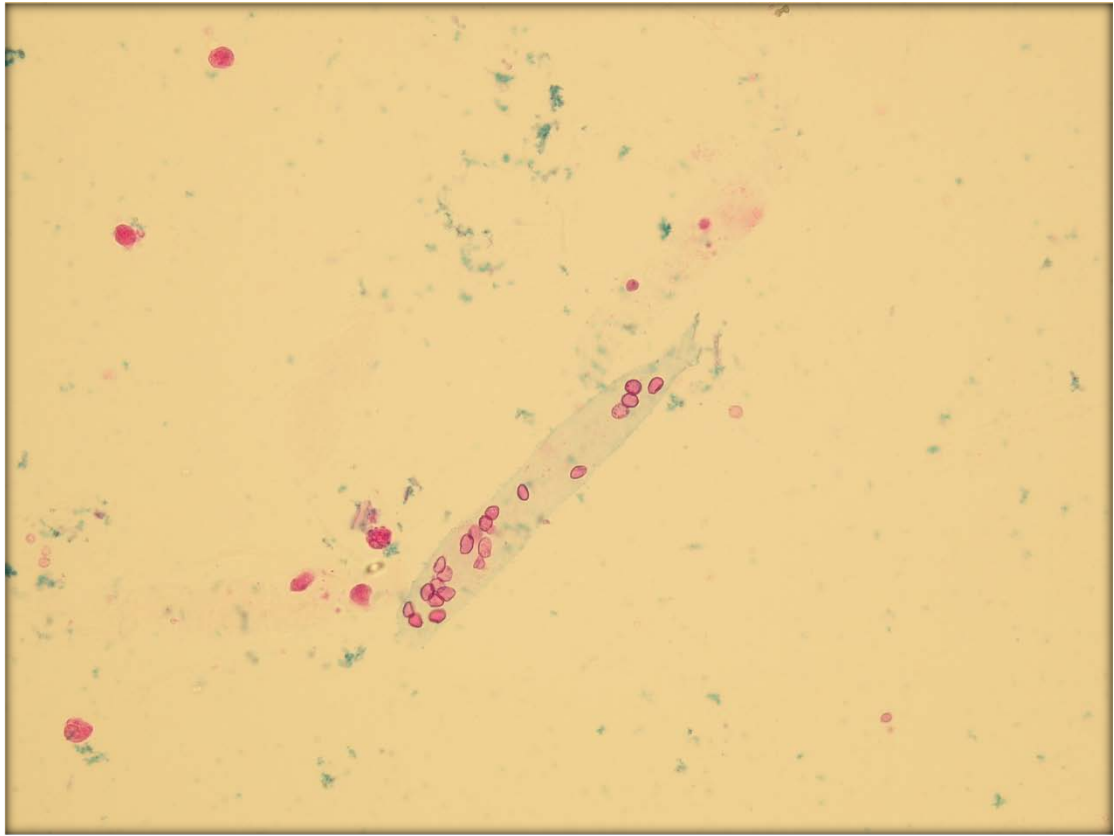
RBC casts-Microscopic picture of native sediment



**RBC casts - FUS-2000 big picture**



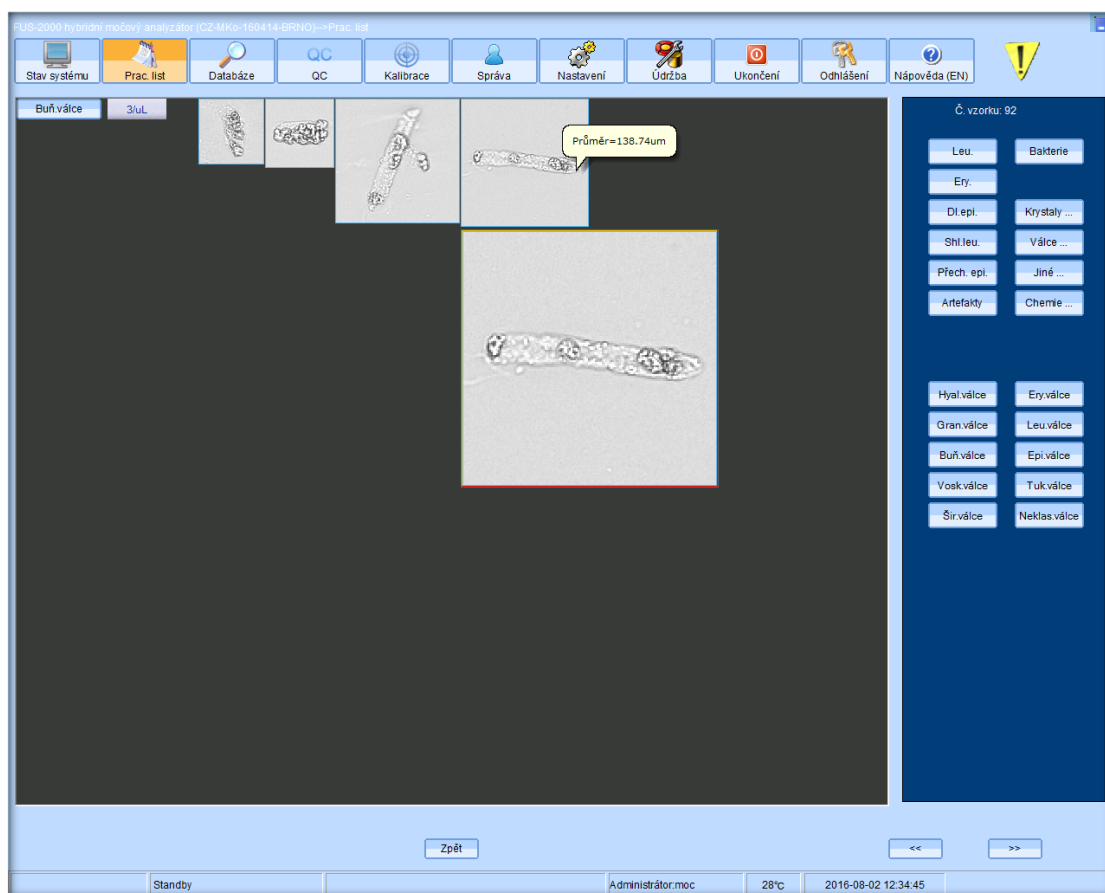
**RBC casts-Microscopic picture of stained sediment**



**Hyaline cast with RBCs-Microscopic picture of stained sediment**

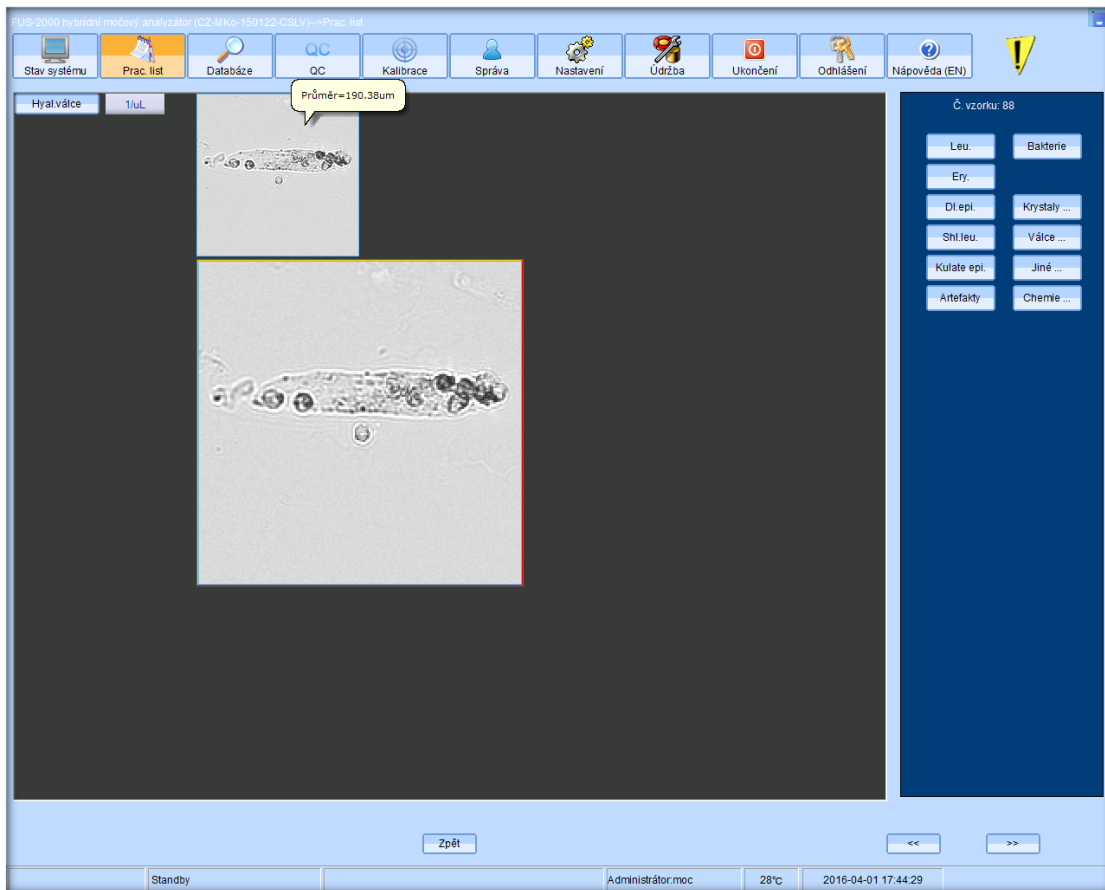
- b) WBC casts are full of WBCs (or pus cells), most of which are degenerated or necrosis cells. WBCs are spherical but often overlapping and gathering into blocks, uneasy to distinguish in morphology with epithelial cells casts. WBC casts are positive to peroxidase staining. After adding acid, the segmented nuclei of neutrophils are clearer. WBC casts suggest infectious diseases of renal parenchyma, such as acute pyelonephritis, renal abscess, interstitial nephritis, and acute glomerulonephritis and are also found in nephrotic syndrome, lupus nephritis. WBC casts contains generally neutrophils but also lymphocytes in case of renal transplantation rejection.

## WBC casts

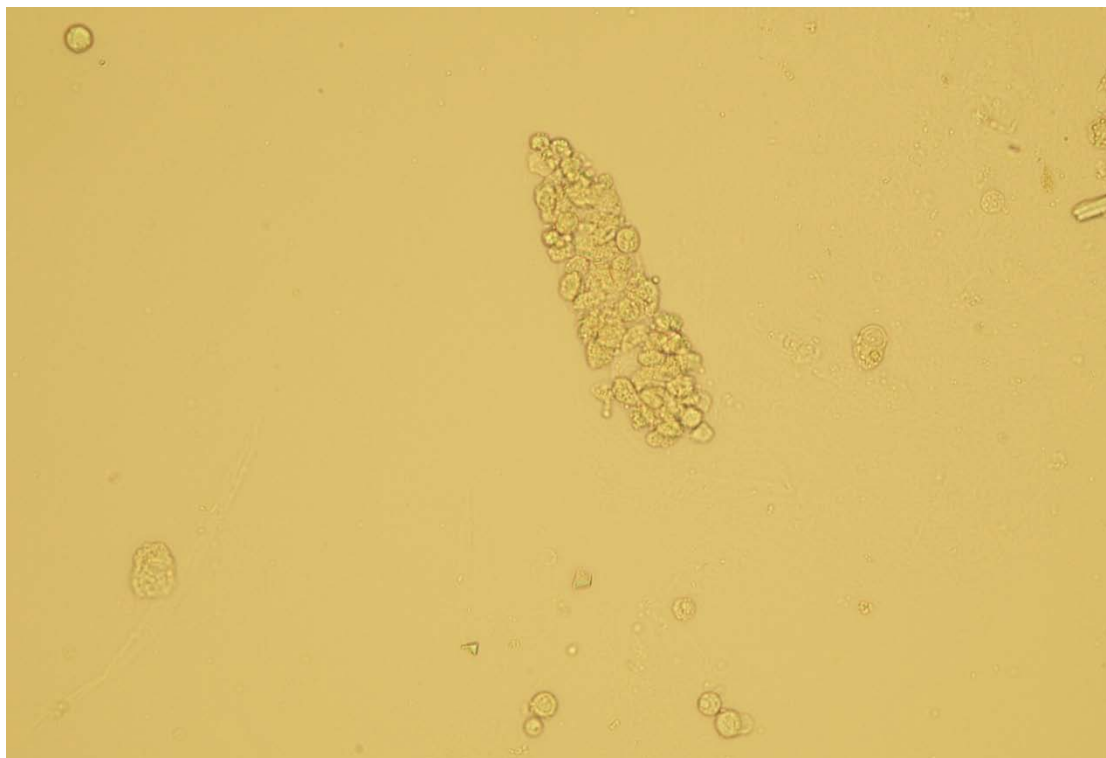


WBC casts - FUS-2000 isolated picture

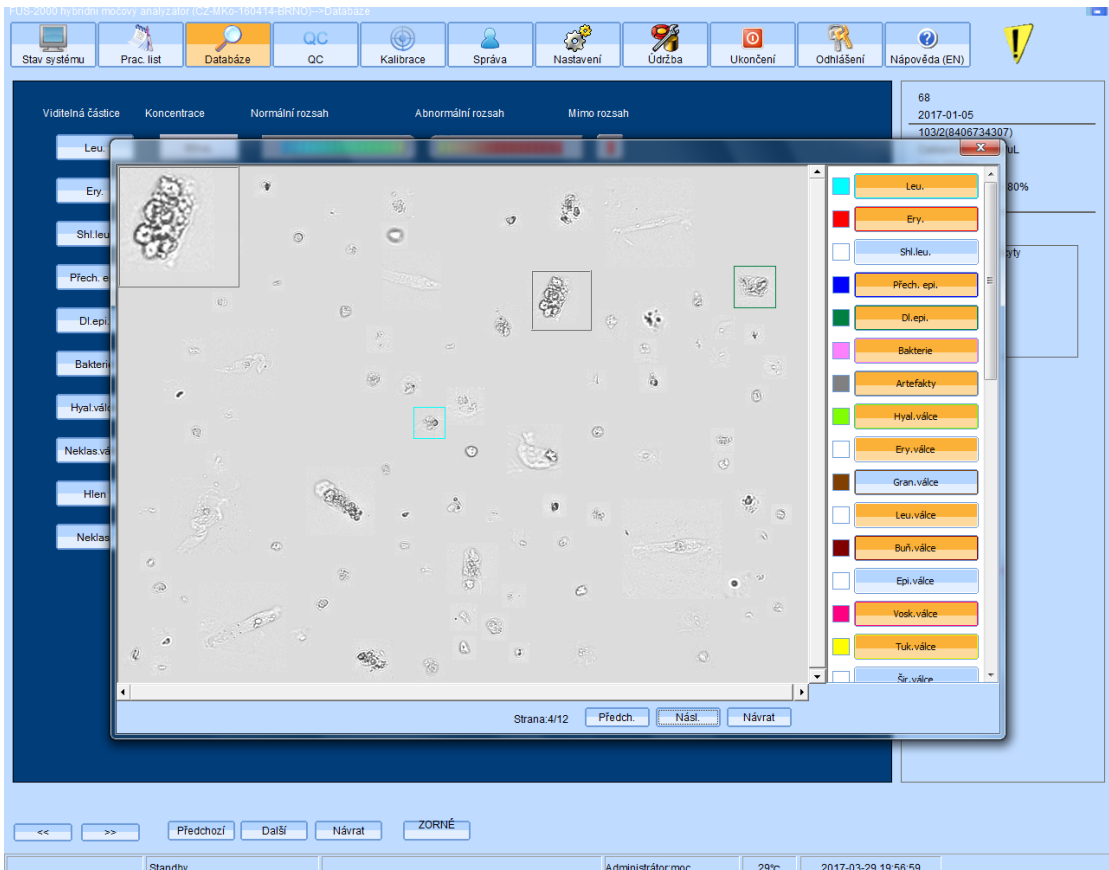




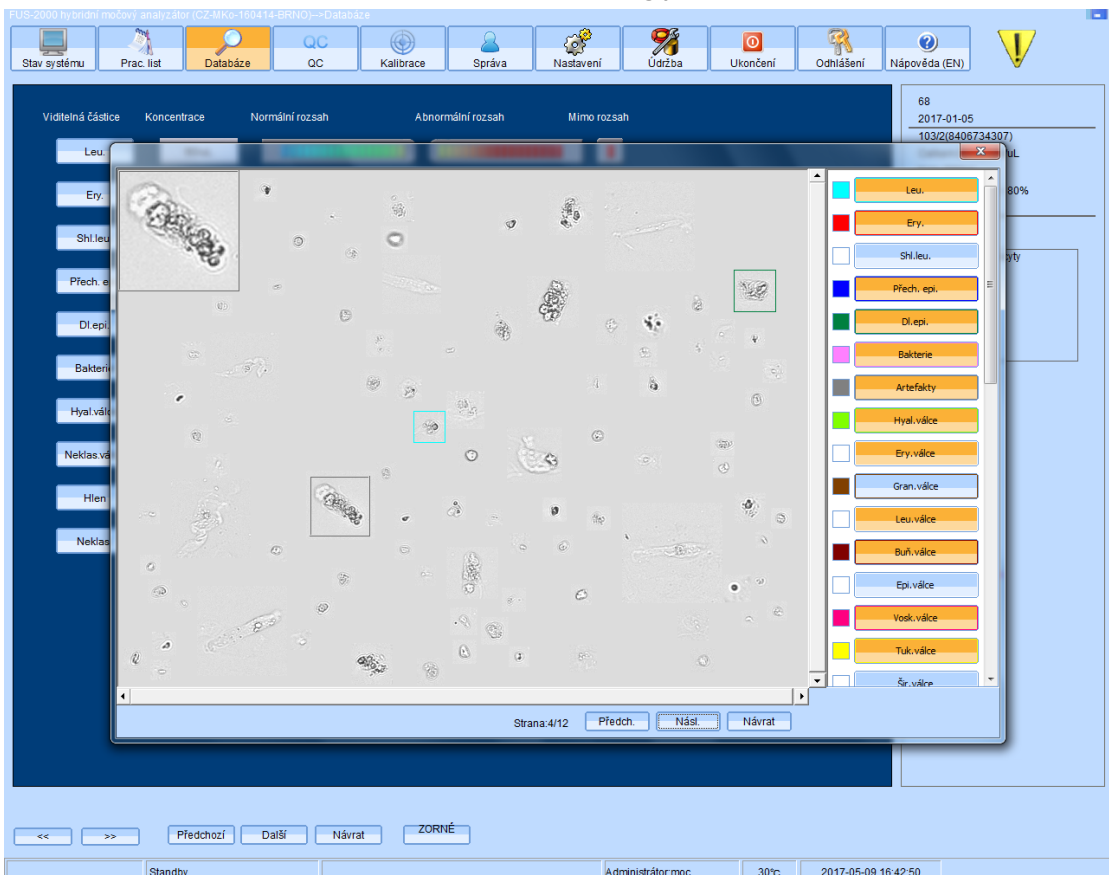
**WBC casts - FUS-2000 isolated picture**



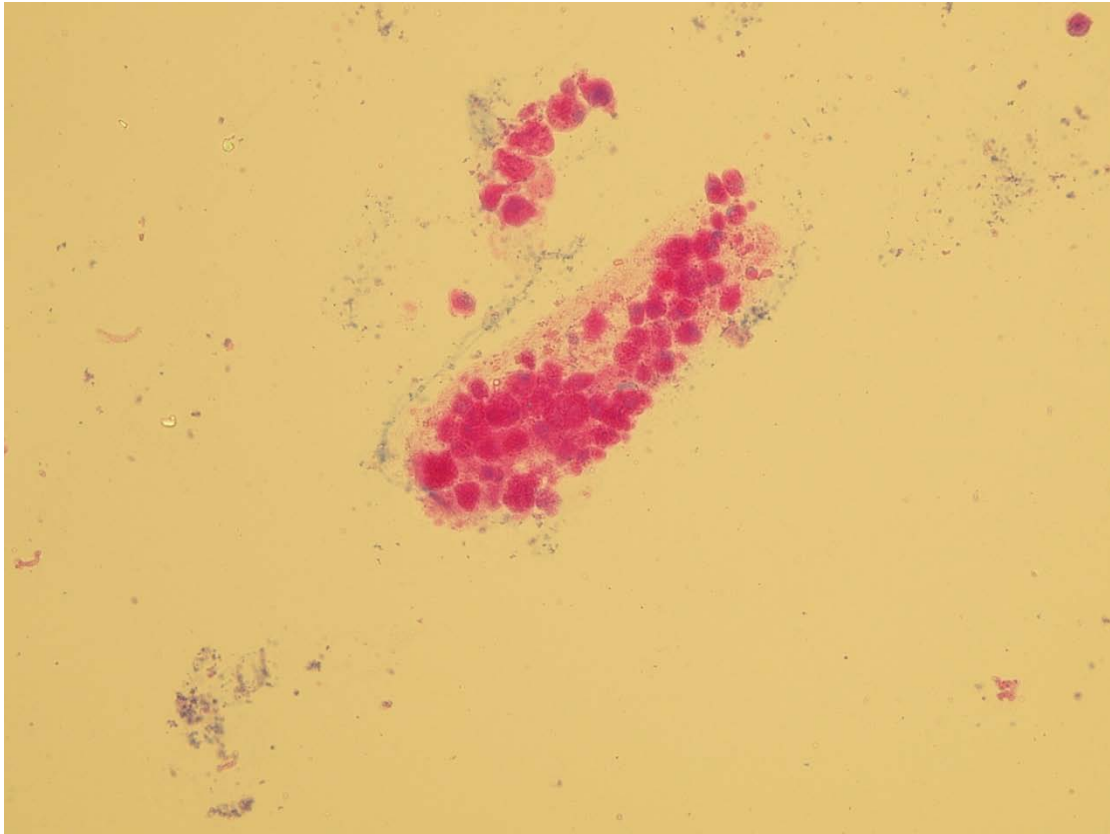
**WBC casts-Microscopic picture of native sediment**



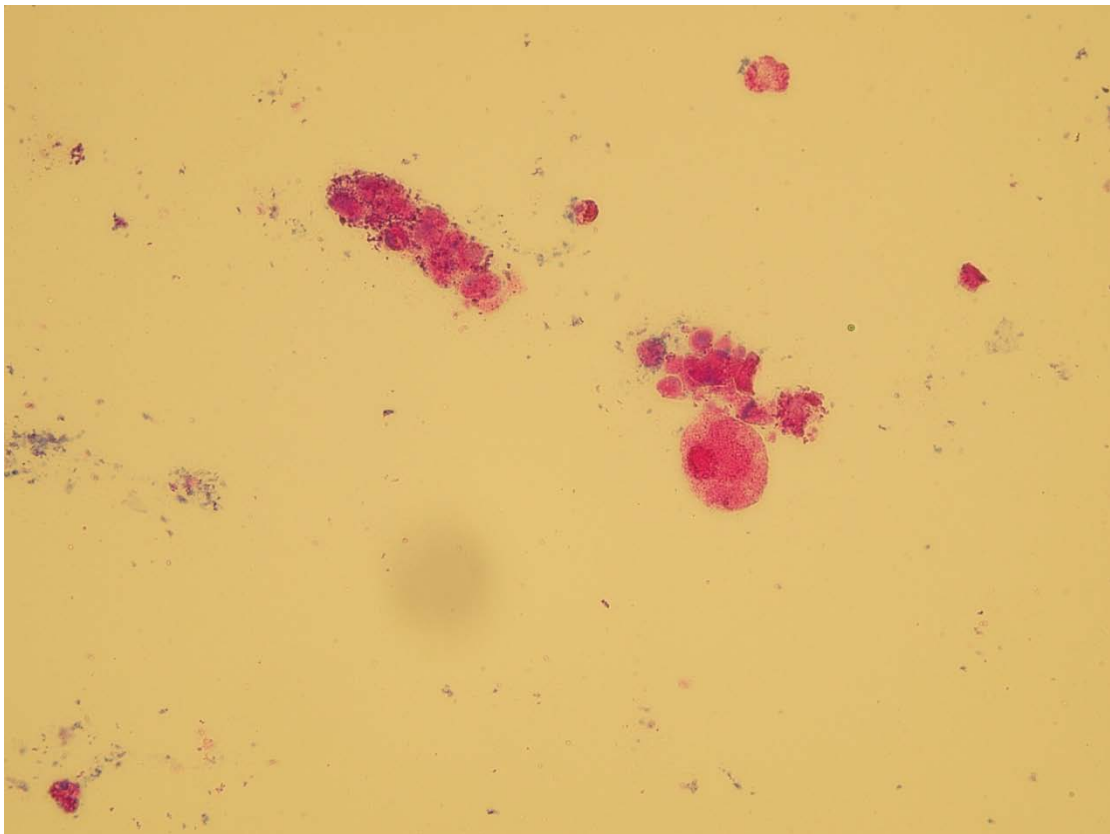
**WBC casts - FUS-2000 big picture**



**WBC casts - FUS-2000 big picture**



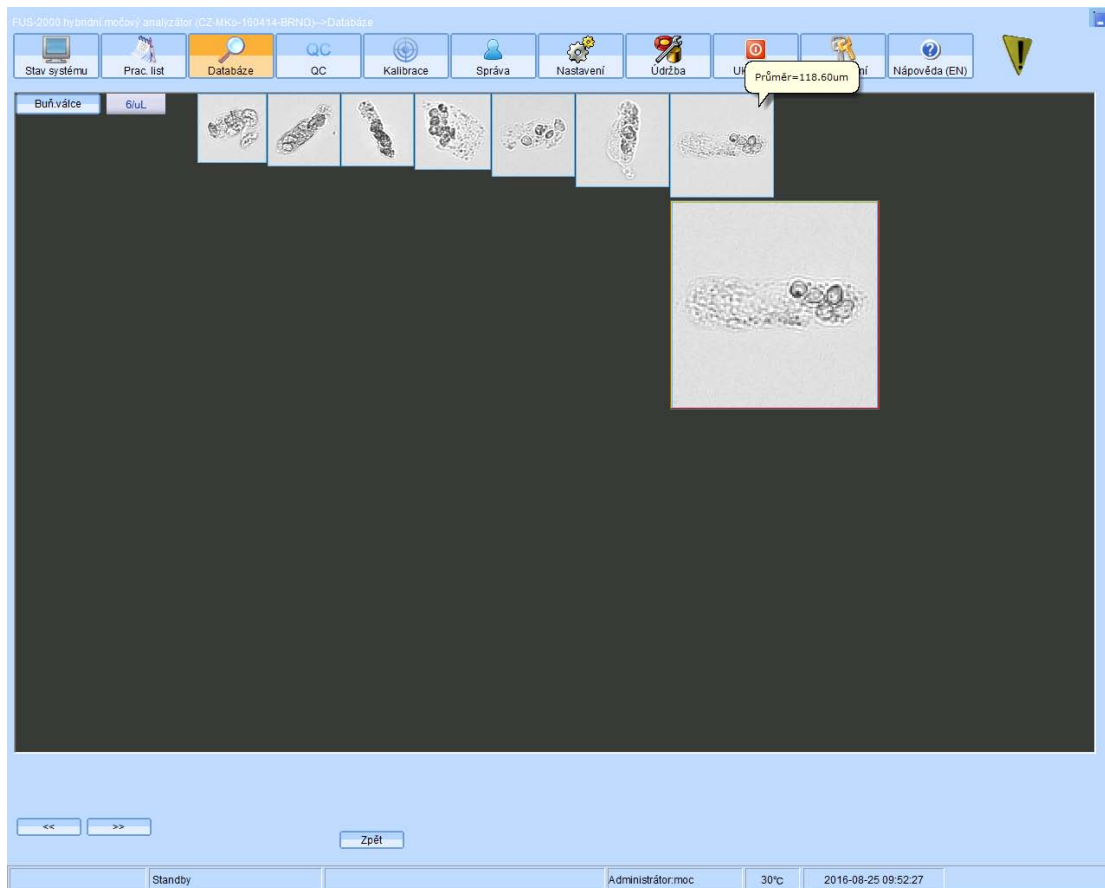
**WBC casts-Microscopic picture of stained sediment**



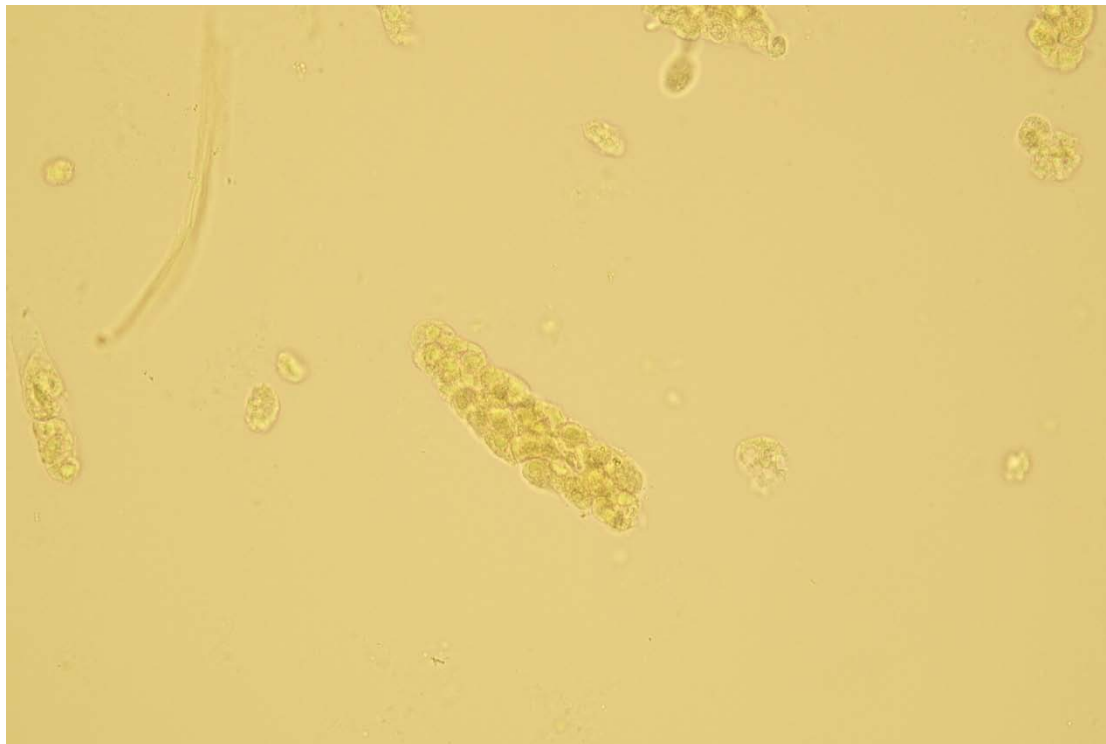**WBC casts-Microscopic picture of stained sediment**

- a) Renal epithelial cell casts are also known as epithelial cell casts, containing renal tubular epithelial cells. Typical cells have tile arrangement with various sizes. Epithelial cell casts do not appear in the urine of healthy people. These casts suggest renal tubular lesions and degenerated fall-off of renal epithelial cells, common in acute tubular necrosis, acute nephritis, renal amyloidosis, interstitial nephritis and heavy metal or drugs intoxication. Within 3 days after kidney transplantation, renal epithelial cell casts in the urine is one of the rejection signs.

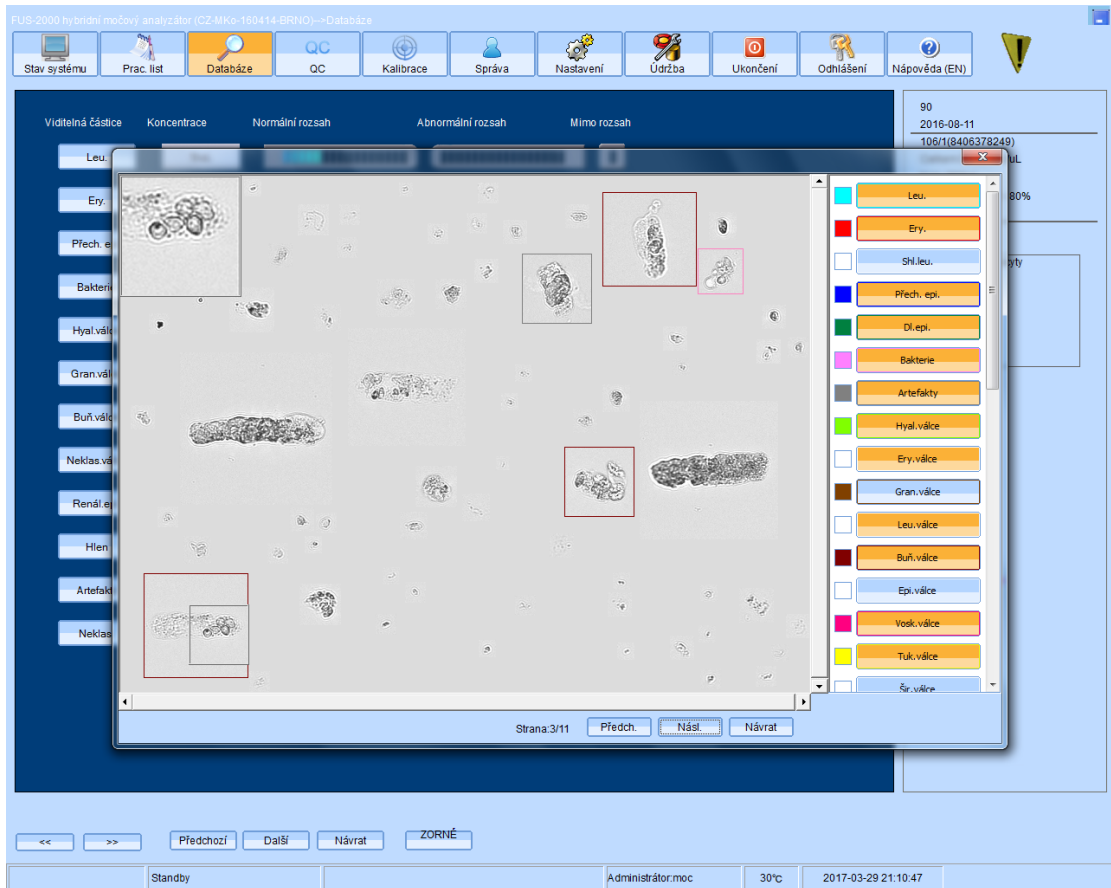
## Renal Epithelial Cell Casts



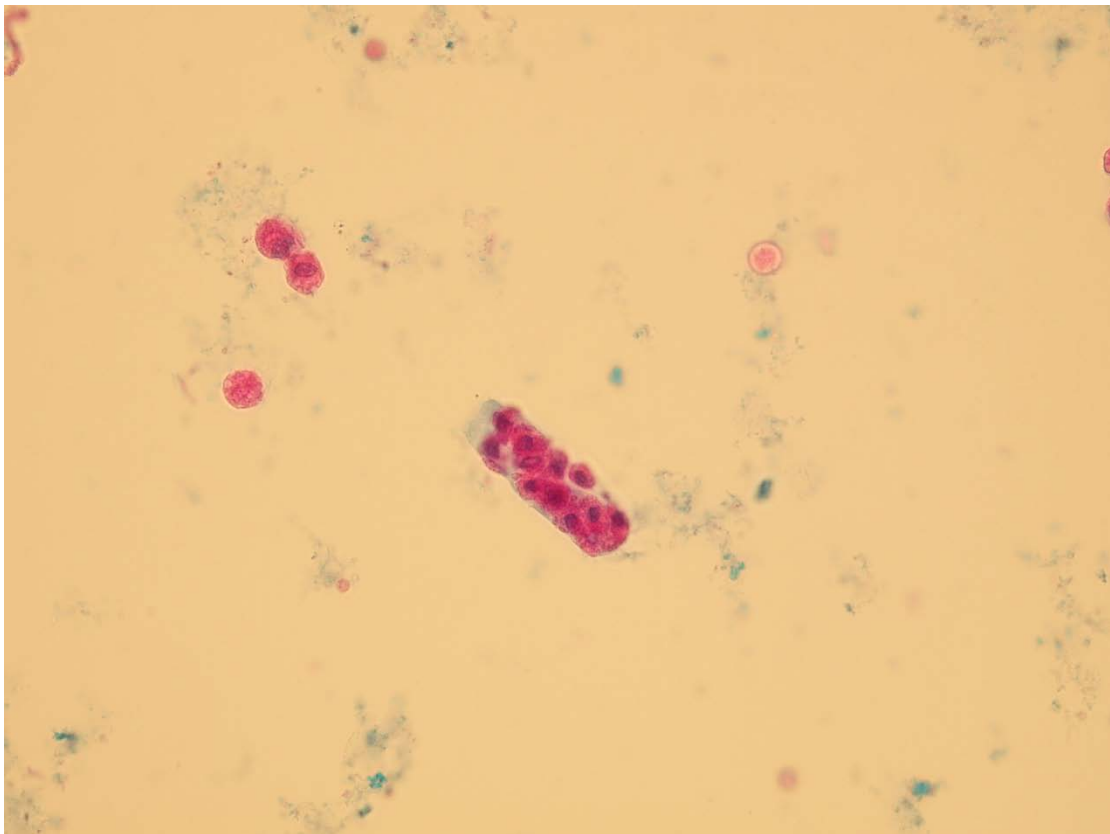
Renal epithelial cell casts - FUS-2000 isolated picture



Renal epithelial cell casts-Microscopic picture of native sediment



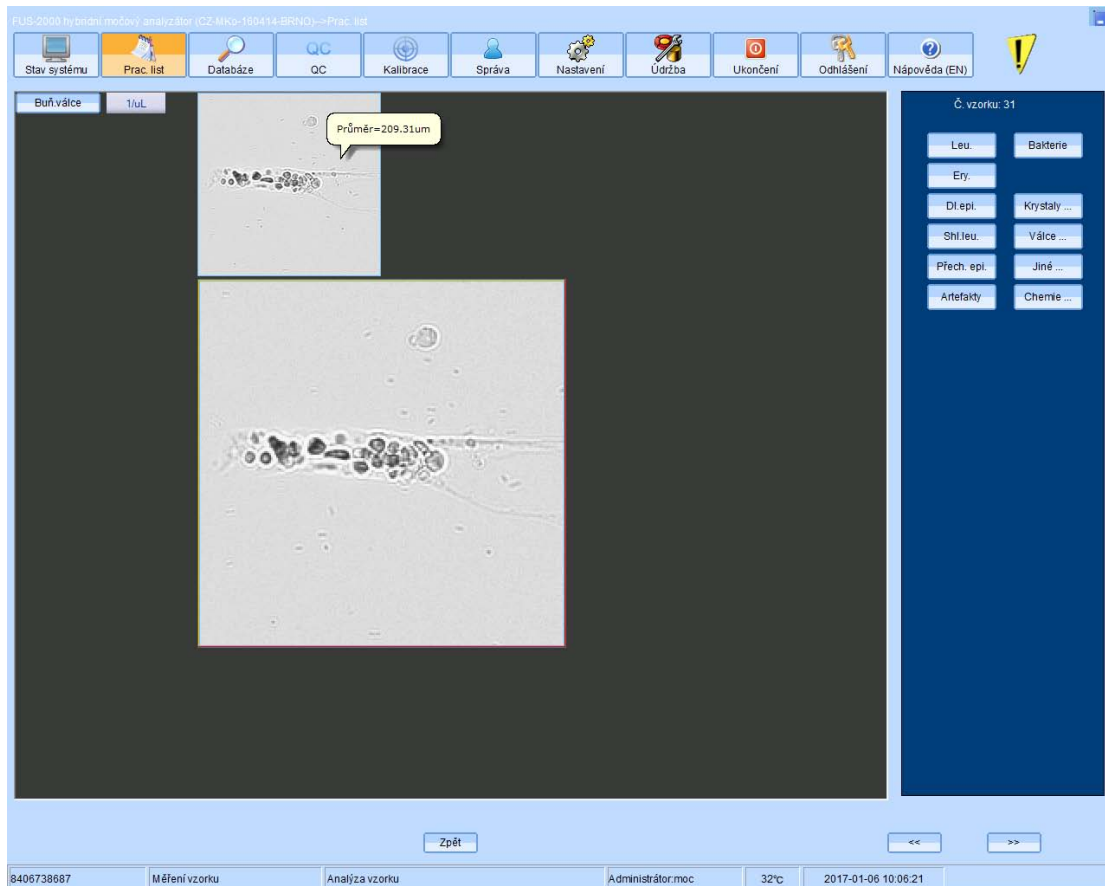
**Renal epithelial cell casts - FUS-2000 big picture**



**Renal epithelial cell casts - Microscopic picture of stained sediment**

- b) Mixed cells casts are casts with two or more types of cells, mainly seen in the active glomerulonephritis, ischemic glomerular necrosis, renal infarction and nephrotic syndrome.

## Mixed Cells Casts



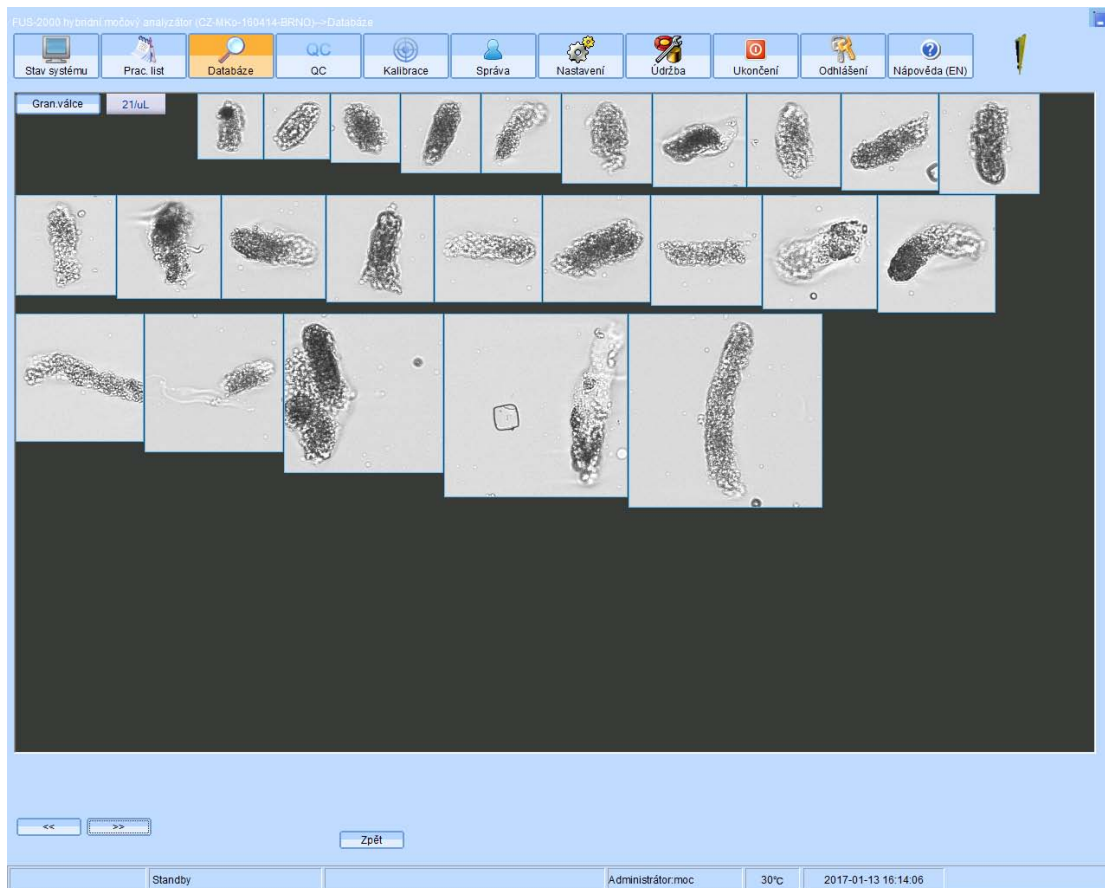
**RBC+WBC cast- FUS-2000 isolated picture**



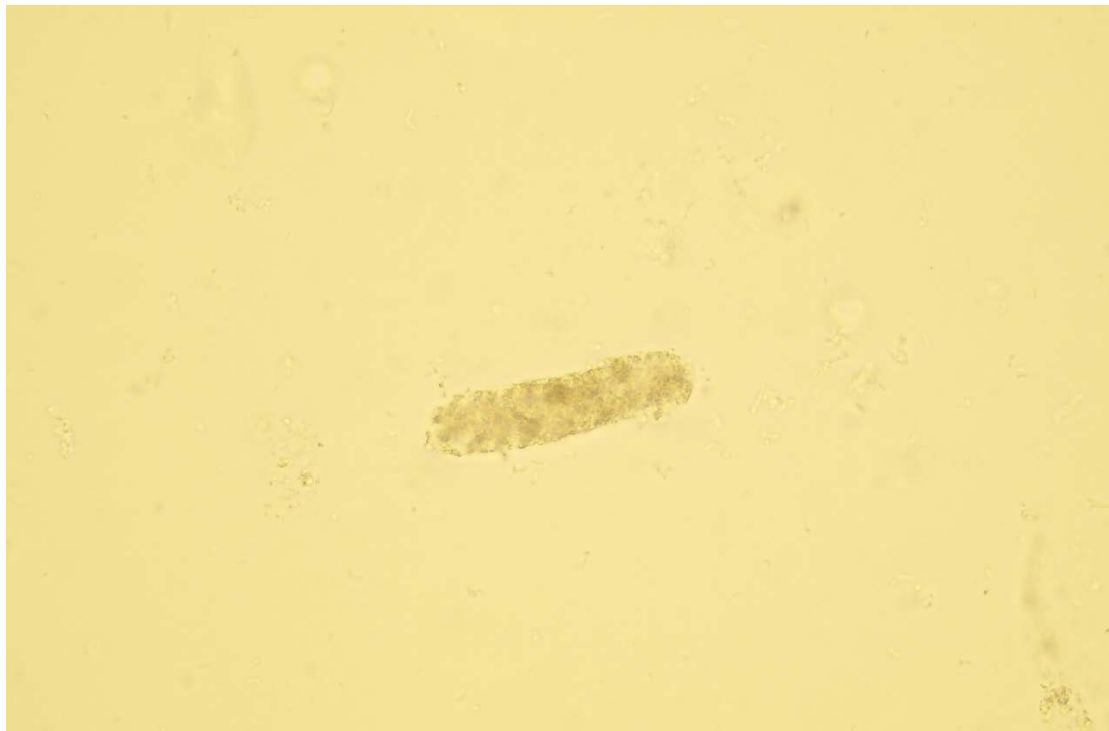3. Granular casts contain granules inside, taking up more than 1/3 of the volume. The granules are from cell fragments, plasma proteins and other substances. Granular casts are shorter and wider than hyaline casts, easy to fracture. The broken ends can be irregular. They are yellowish or brownish black. The granular casts are clearly outlined. Granular casts can be divided into 2 types depending on the size of the granules, coarse granular cast and fine granular cast. Coarse granular casts are full of coarse particles, often in dark brown. Fine granular casts contain a lot of small and fine granulars, non-transparent, in grey or light yellowish.

There are usually no granular casts in healthy people urine. Thin granular casts are present in urine after intense physical activities, dehydration and fever. Granular casts and hyaline casts often appear together. Proliferation of granular casts suggests substantive diseases of the kidney, such as acute or chronic nephritis, nephrotic syndrome, renal tubular sclerosis, chronic pyelonephritis, serious infection and renal arteriosclerosis. In early stage of polyuria caused by acute renal failure a large number of granular casts in urine can be seen. In advanced stage of chronic nephritis, the appearance of granular casts suggests poor prognosis.

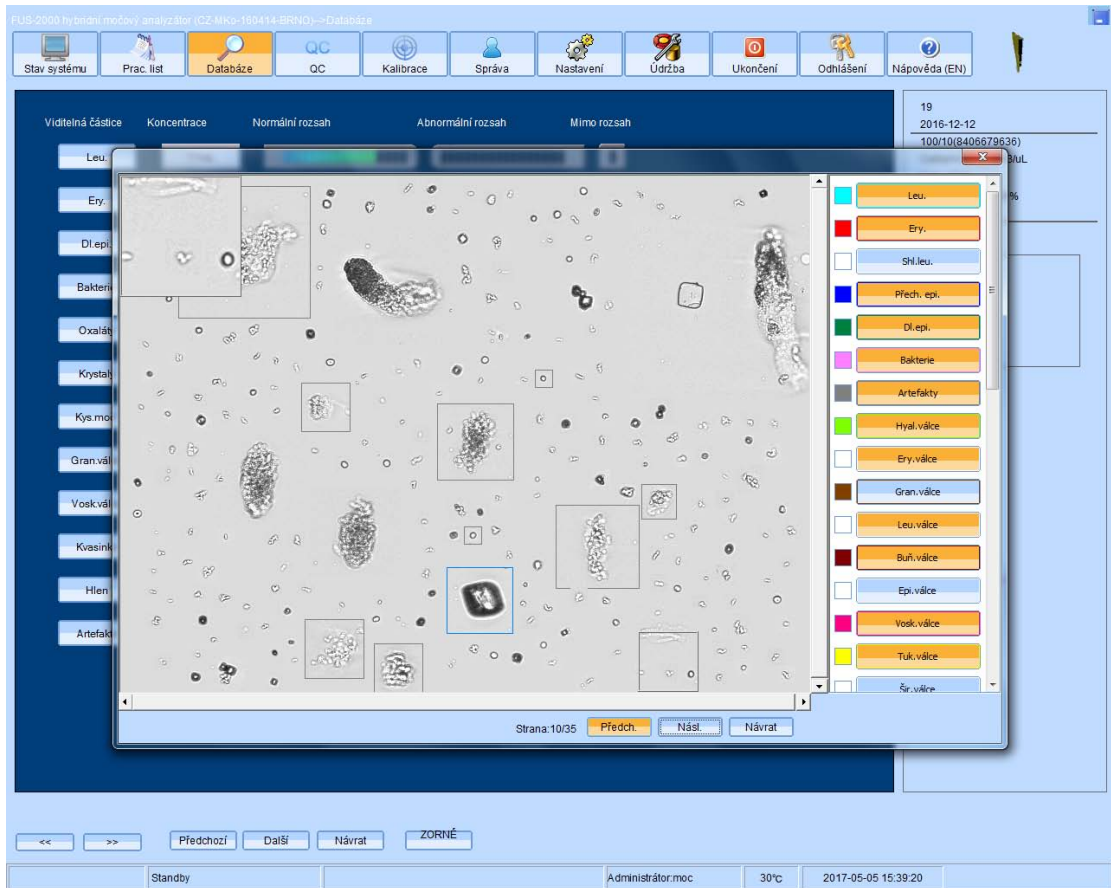
## Granular casts



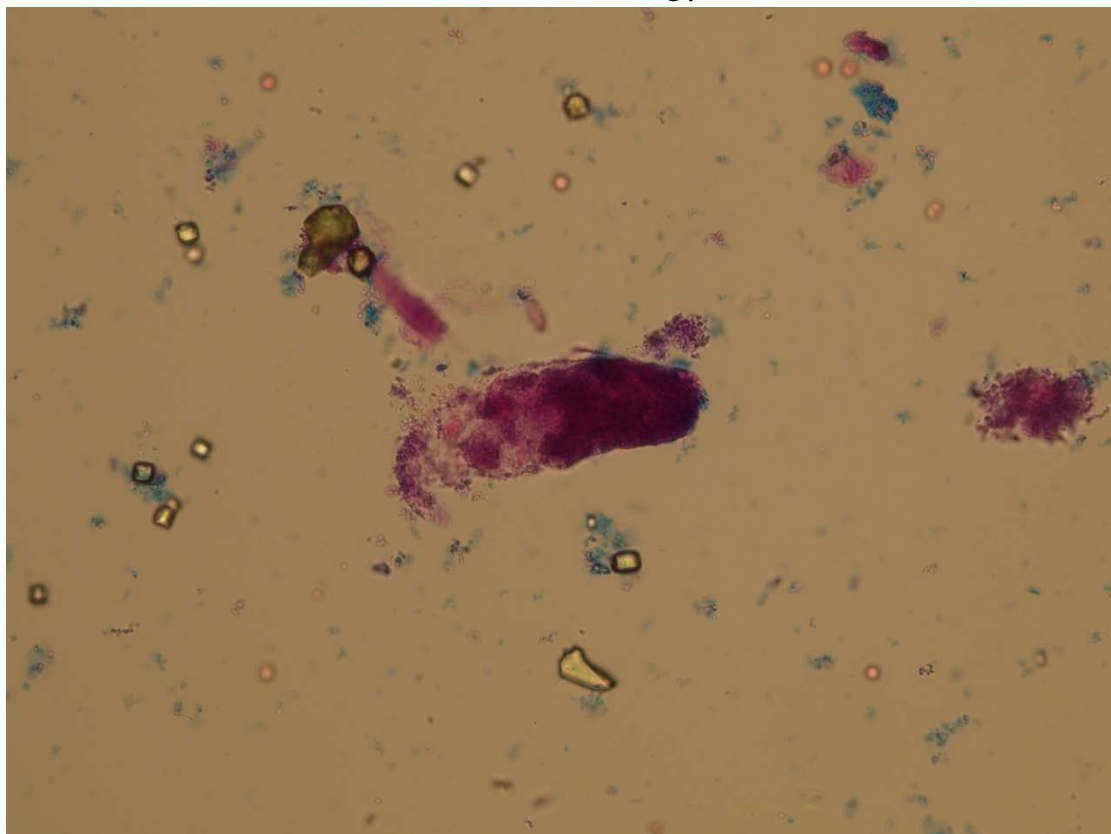
**Granular casts - FUS-2000 isolated picture**



**Granular casts-Microscopic picture of native sediment**



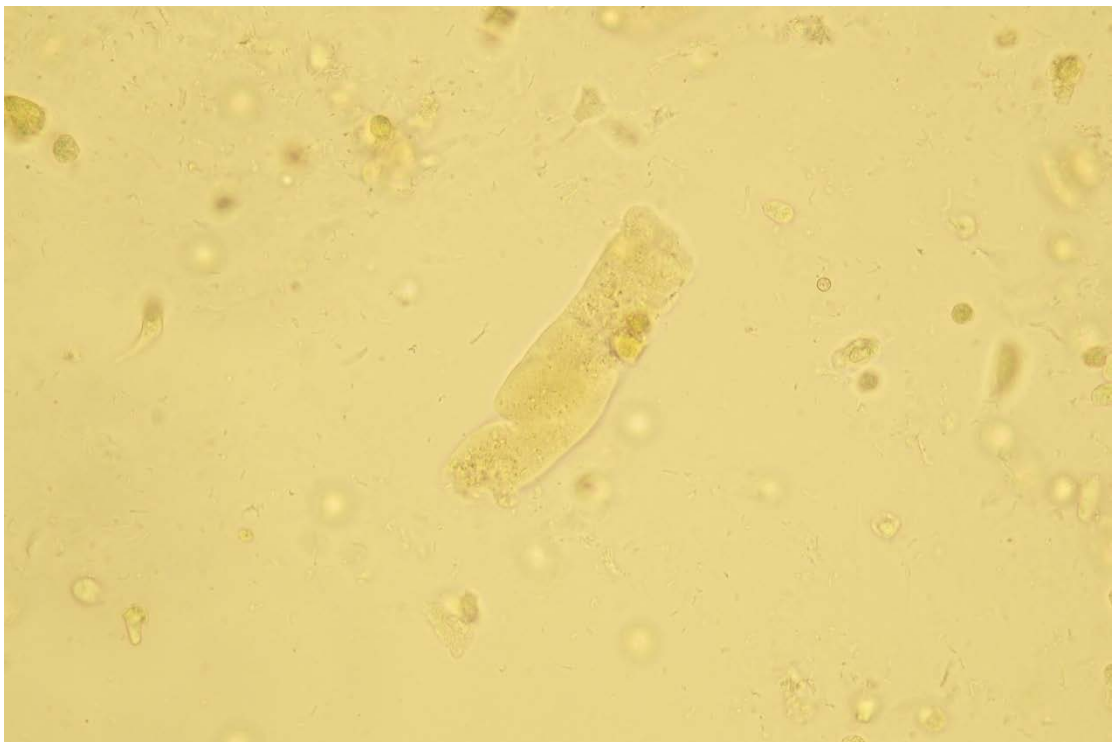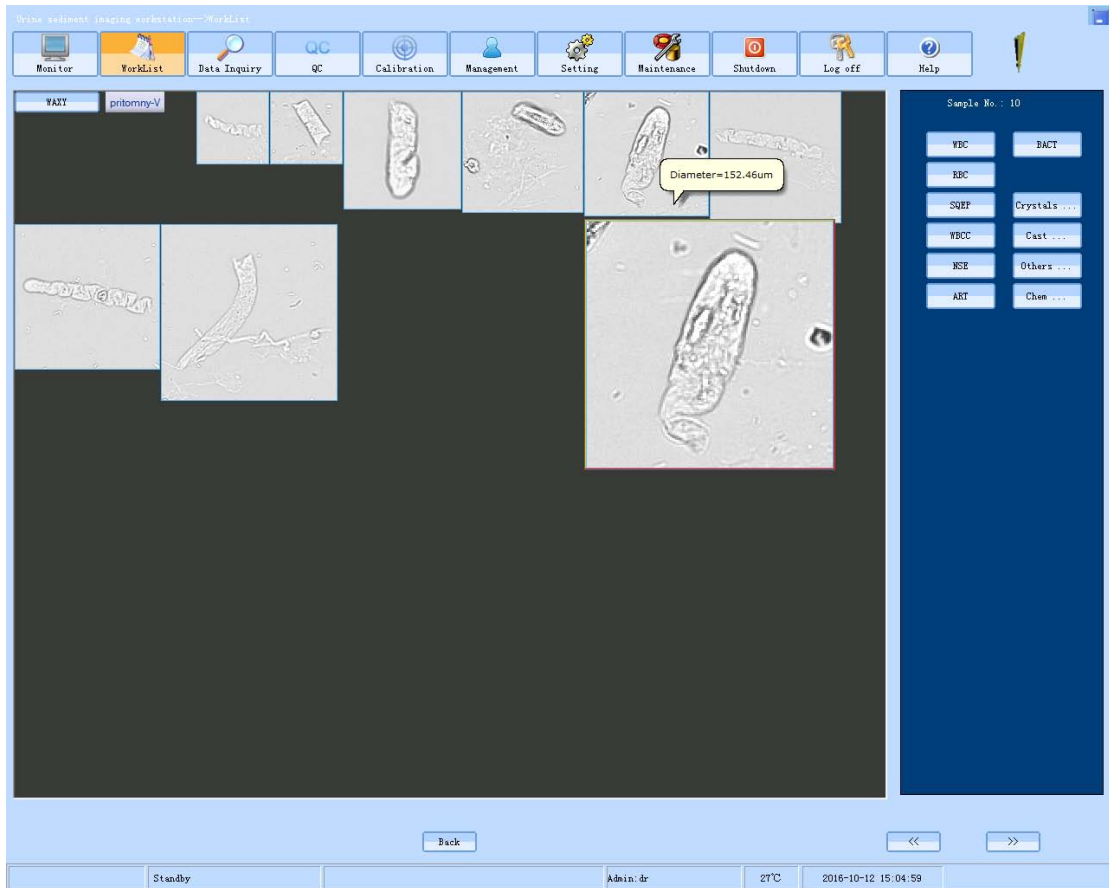
**Granular casts - FUS-2000 big picture**



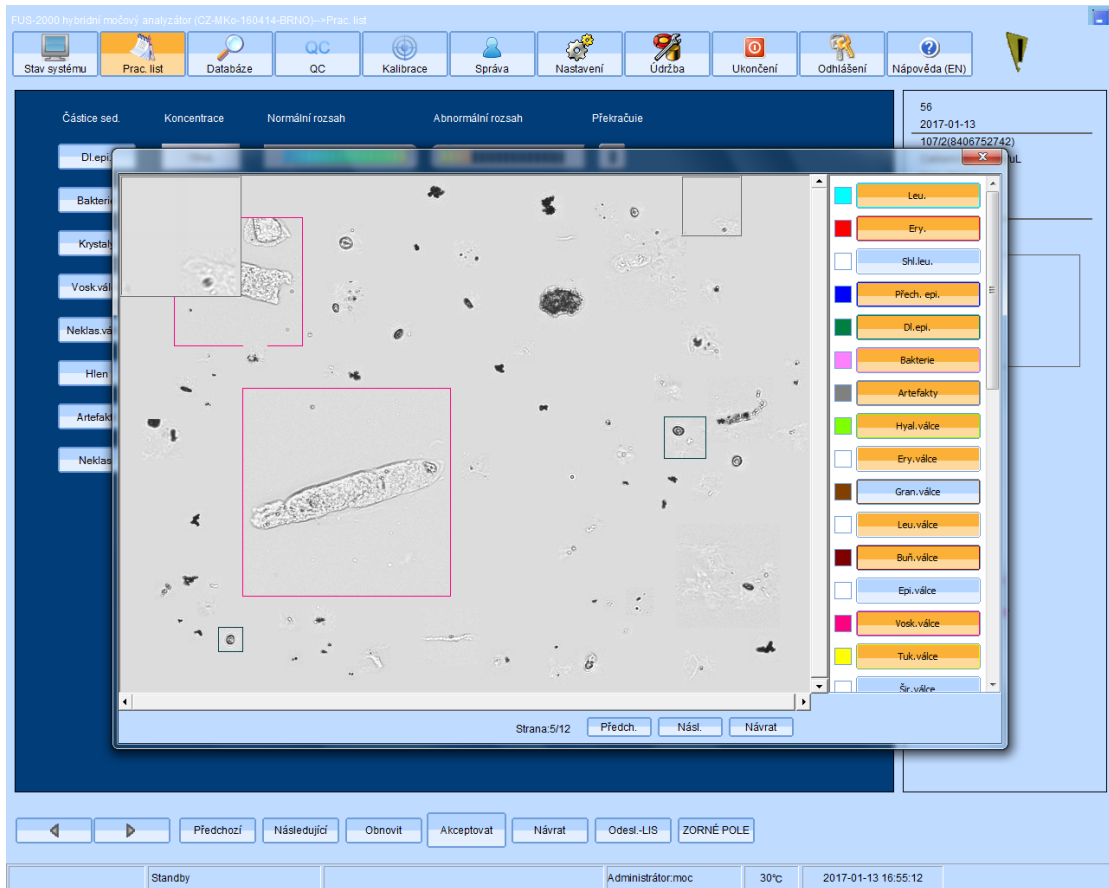
**Granular casts-Microscopic picture of stained sediment**

4. Waxy casts are derived from granular casts, or gradually formed casts from dissolved amyloidosis epithelial cells, or may be evolved from hyaline casts by stopping in the renal tubules for too long time. Waxy cast looks like hyaline casts, in light grey or light yellow with strong refraction. They have thick texture with notches and are short, thick and easy to brittle. The casts are usually slightly bent with ragged ends. They would not dissolve in hypertonic solution, water and different pH mediums. No waxy casts are found in urine of healthy people. Waxy casts detected in urine suggest severe lesions of renal tubules with poor prognosis. Waxy casts are seen in renal tubule inflammation and degeneration, kidney transplant rejection, severe liver diseases. Glycogen degeneration of renal tubular epithelial cells in diabetic nephropathy and nephrotic syndrome patients would cause removal of glycogen and fat to get smoother waxy casts.

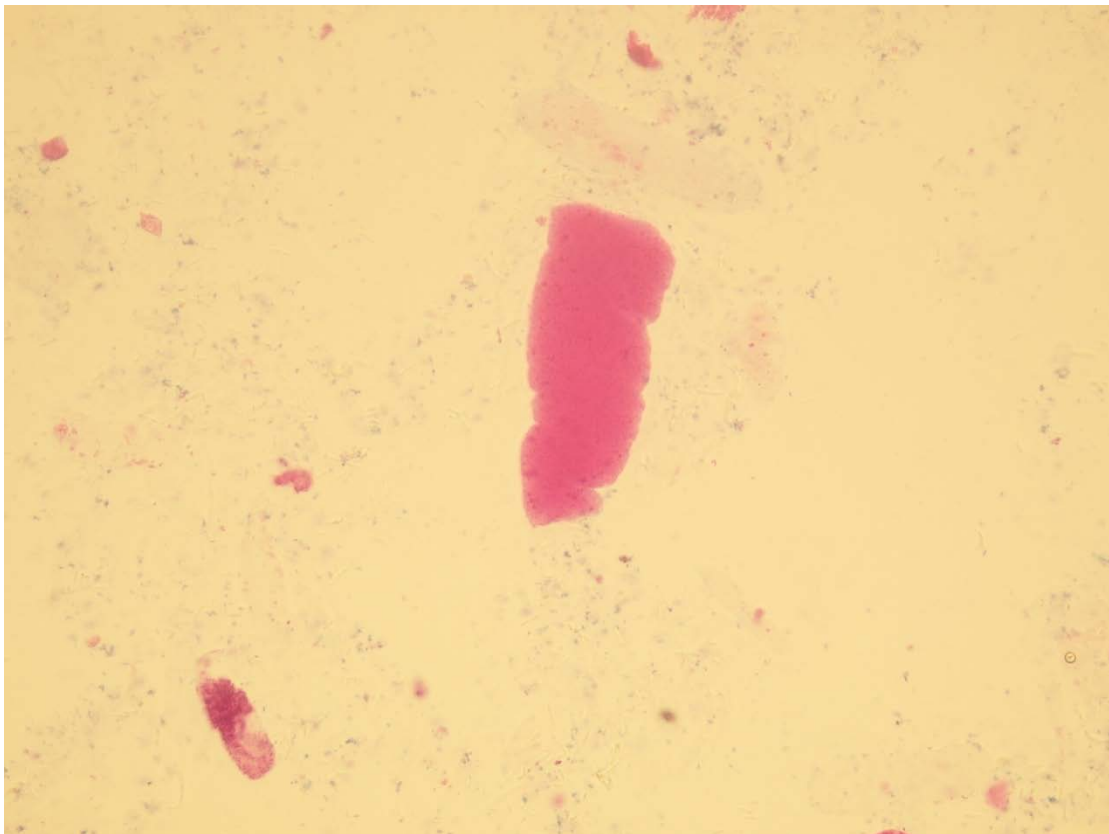
## Waxy casts



Waxy casts-Microscopic picture of native sediment



**Waxy casts - FUS-2000 big picture**

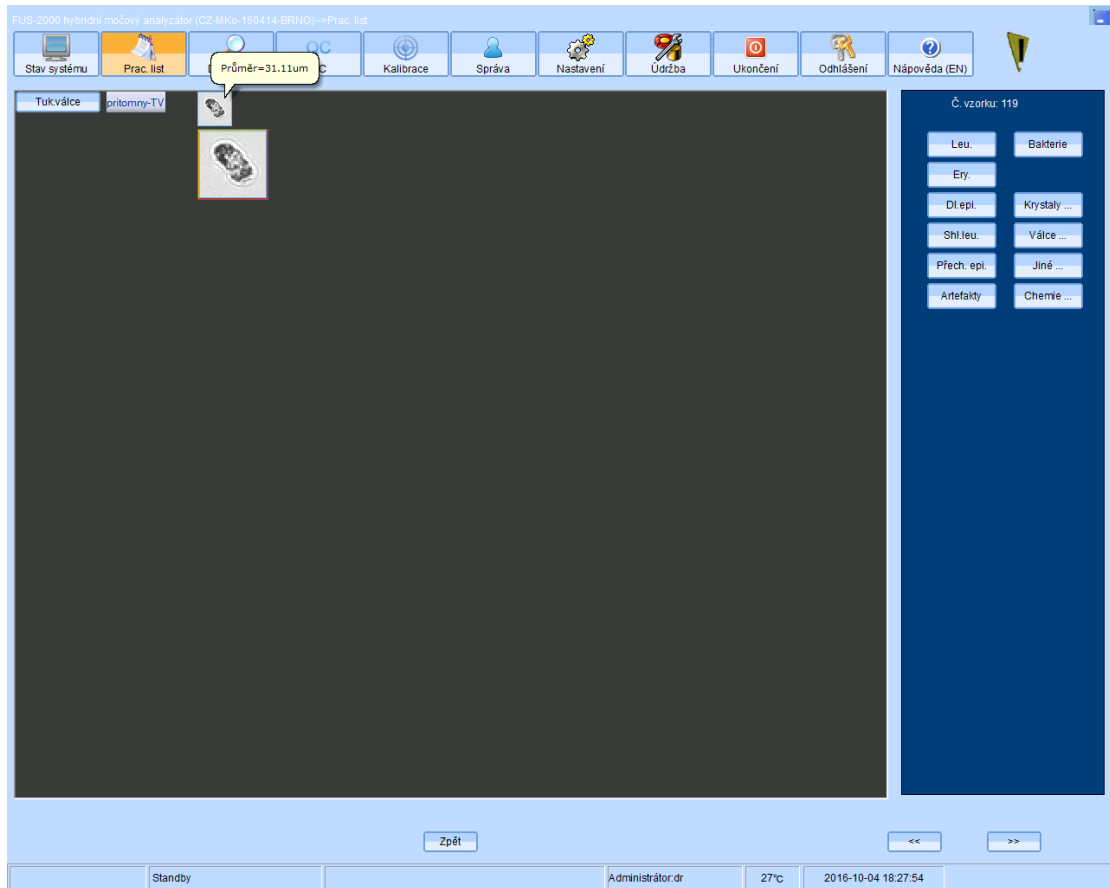


**Waxy casts-Microscopic picture of stained sediment**

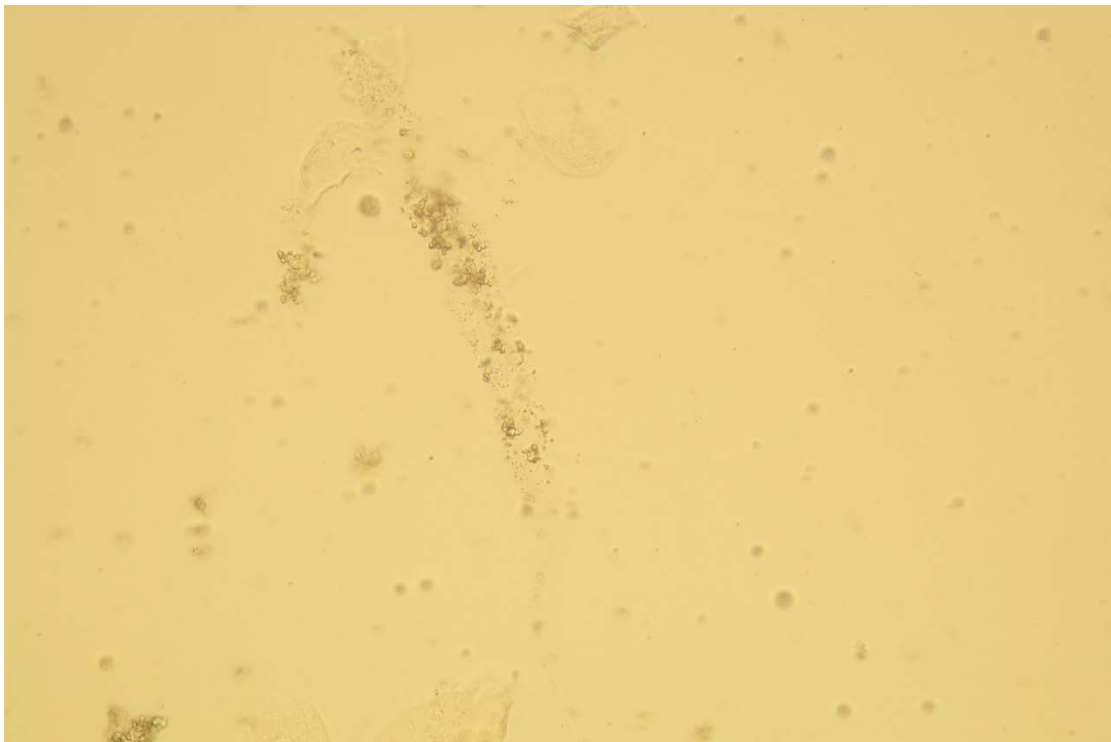
5. Fatty casts contains fat droplets taking up more than 1/3 volume of the casts. They are formed by fatty degeneration or decomposition of renal tubular epithelial cells when a large number of fat droplets go into the casts. In the casts are varied sizes of fat droplets with high refraction. Fatty casts are not present in healthy people urine. Fatty casts are related to kidney tubule lesions and fatty degeneration of renal tubular epithelial cells, found in sub-acute glomerulonephritis, chronic glomerulonephritis, and toxic nephropathy and are especially common in nephrotic syndrome.



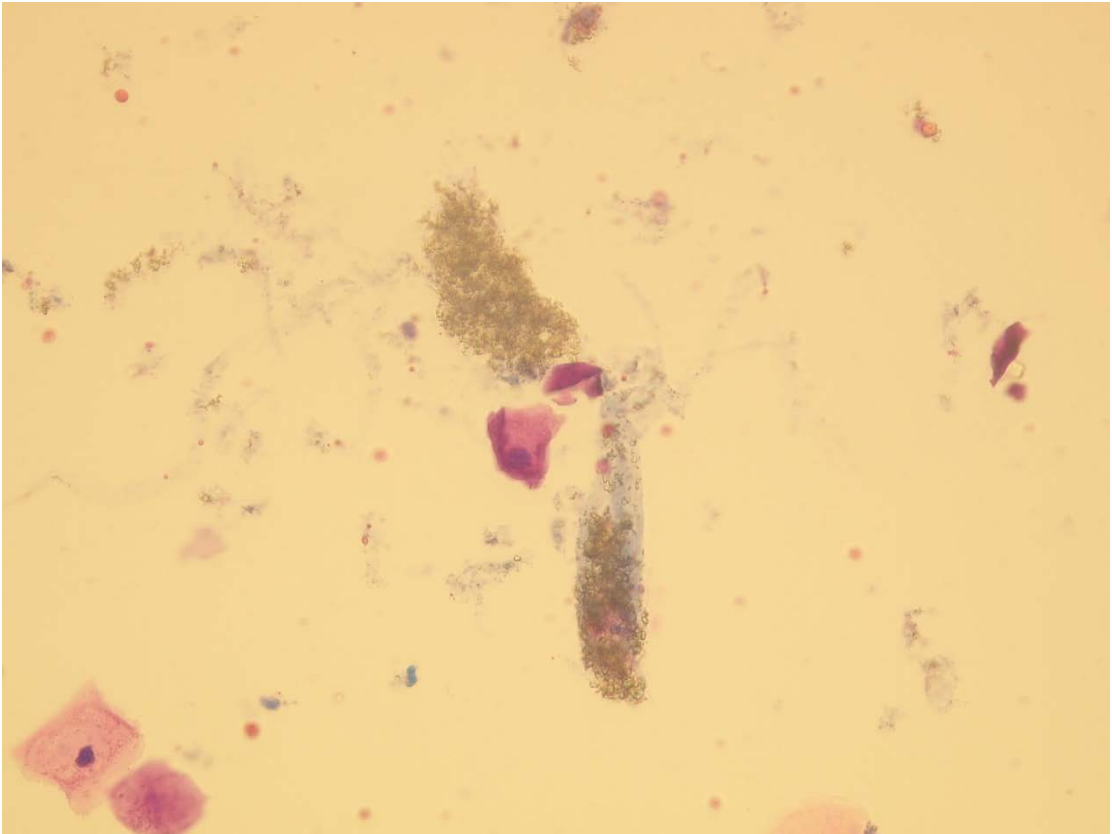
## Fatty casts



Fatty casts - FUS-2000 isolated picture



Fatty casts-Microscopic picture of native sediment

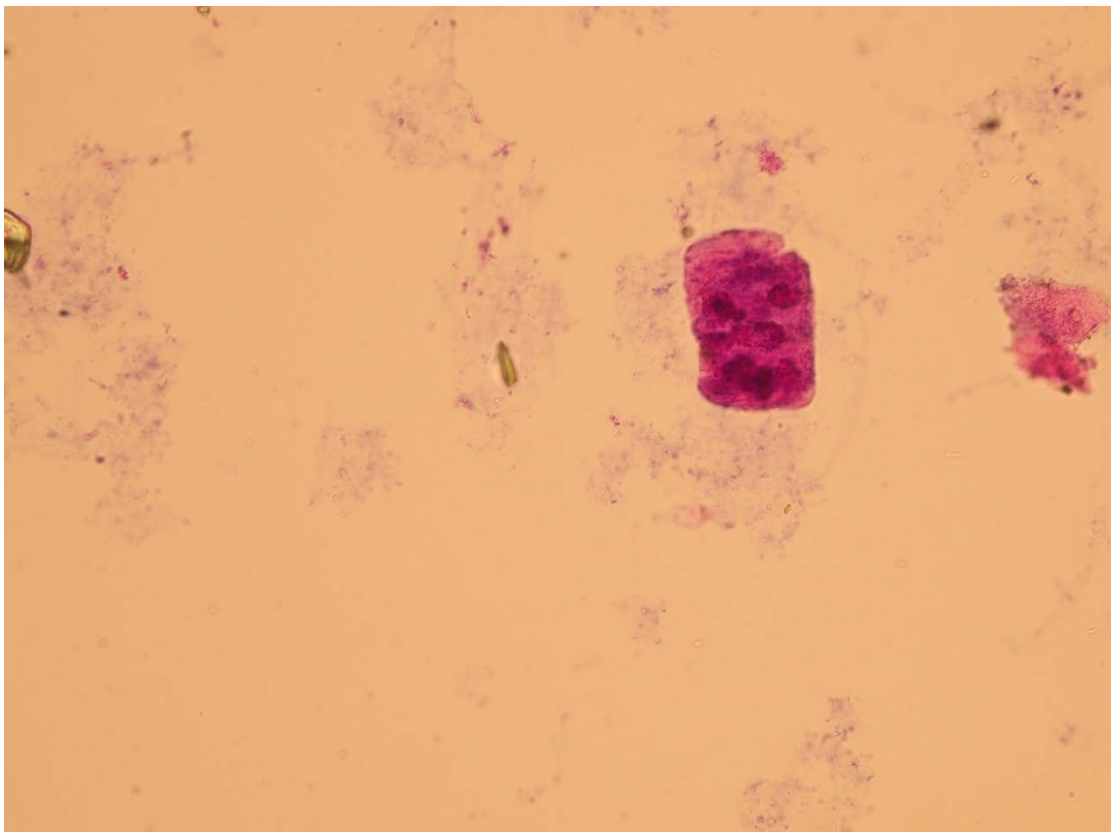


**Fatty casts-Microscopic picture of stained sediment**

6. Renal failure casts are also called broad cast, originating from damaged and expansive kidney tubules, collecting tubules or papillary ducts. Most are evolved from granular casts and waxy casts. The width can reach more than 50  $\mu\text{m}$ , generally 2-6 times of normal casts, irregular in shape, easy to brittle and sometimes in distorted shape.

Broad casts can be divided into 3 types depending on the transverse diameter, small width broad casts (diameter of 1-2 RBCs), medium width broad casts (diameter of 3-4 RBCs), and big width broad casts (diameter of 5 RBCs or more). Renal failure casts are the signs of severe renal lesions. Early polyuria in acute renal failure patients is implied by a large number of broad casts, which would decrease gradually and disappear as the renal function is improved. Uremia in advanced chronic nephritis results in renal failure casts, which often signifies poor prognosis. In urine of patients with acute renal failure caused by hemolysis after transfusion from different blood types are seen brown broad hemoglobin casts. In urine of patients with acute renal failure caused by renal extrusion or extensive burns are seen pigment myohemoglobin casts.

## Broad Cast

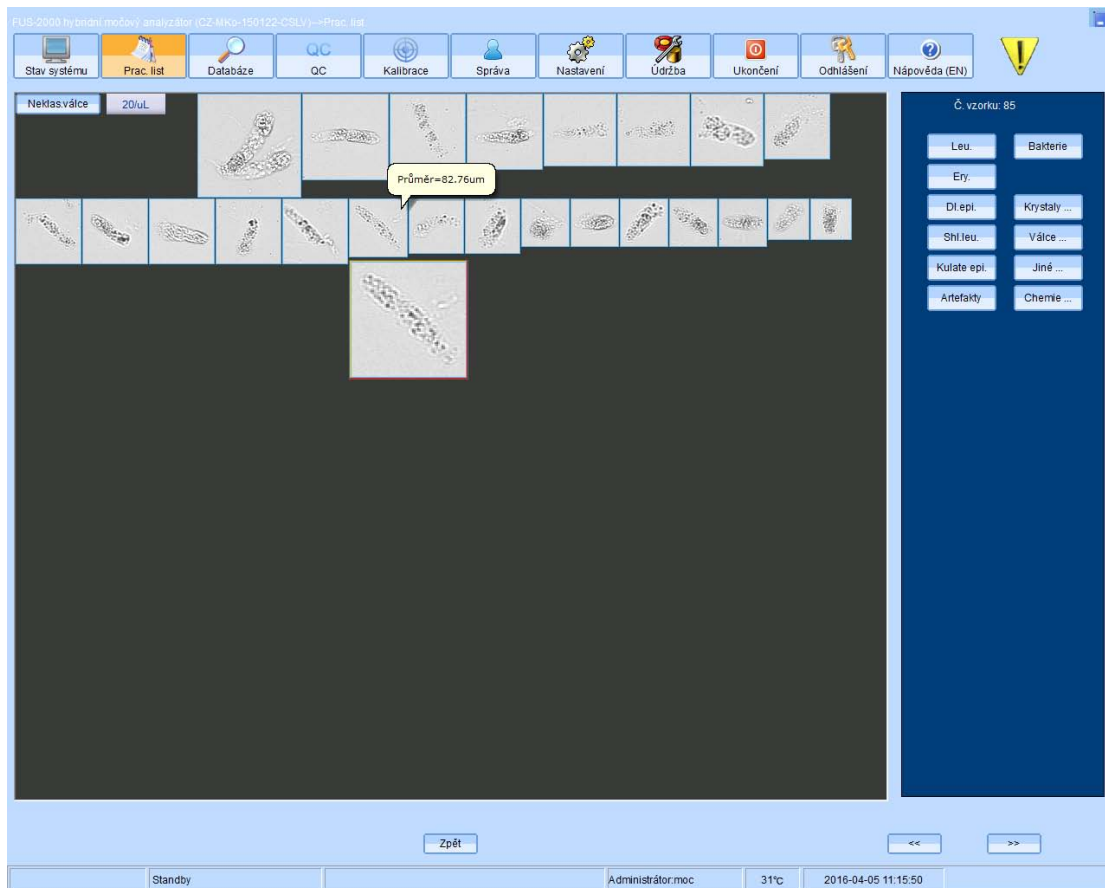


**Broad casts-Microscopic picture of stained sediment**

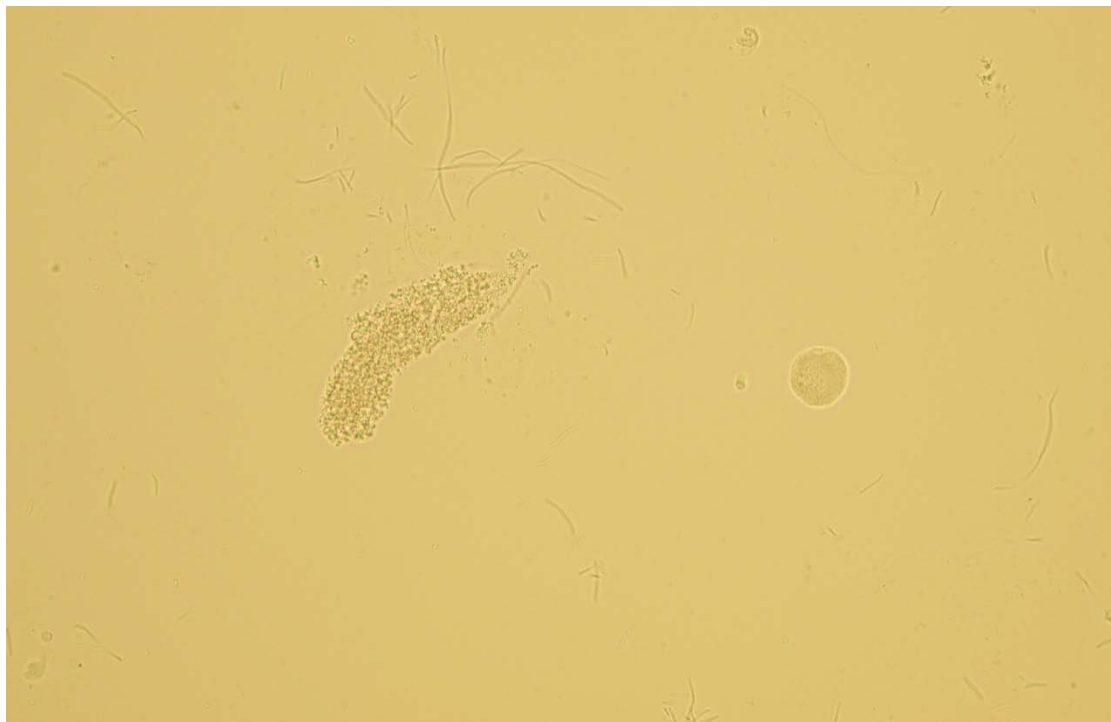7. Other casts: in some pathological cases, there would be some rare casts appearing in the urine.

- a) Bacterial casts are filled with bacteria, indicating renal parenchyma infected by bacteria, commonly seen in pyogenic infection of the kidney.
- b) Bilirubin casts are filled with golden bilirubin particles, found in severe hepatitis.
- c) Nested casts are casts nested with other casts, indicating long stay of urine in tubules.

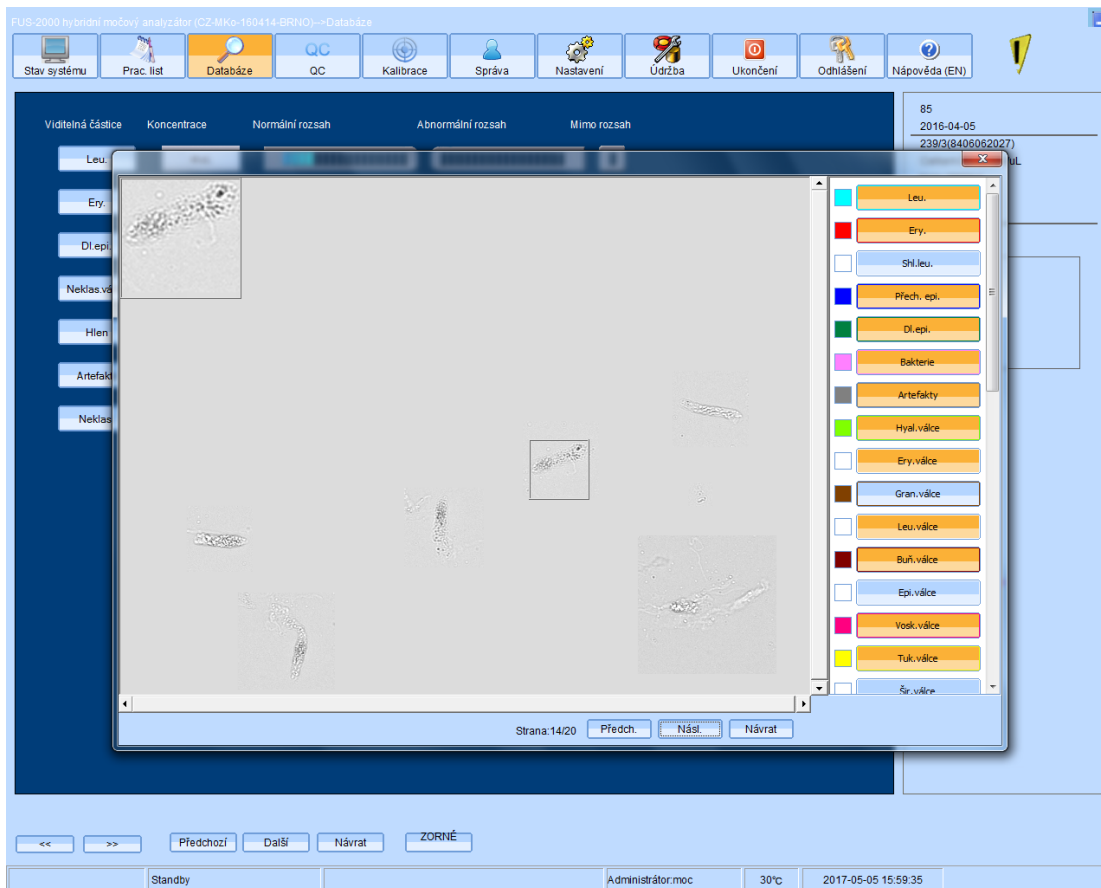
## Bacterial Casts



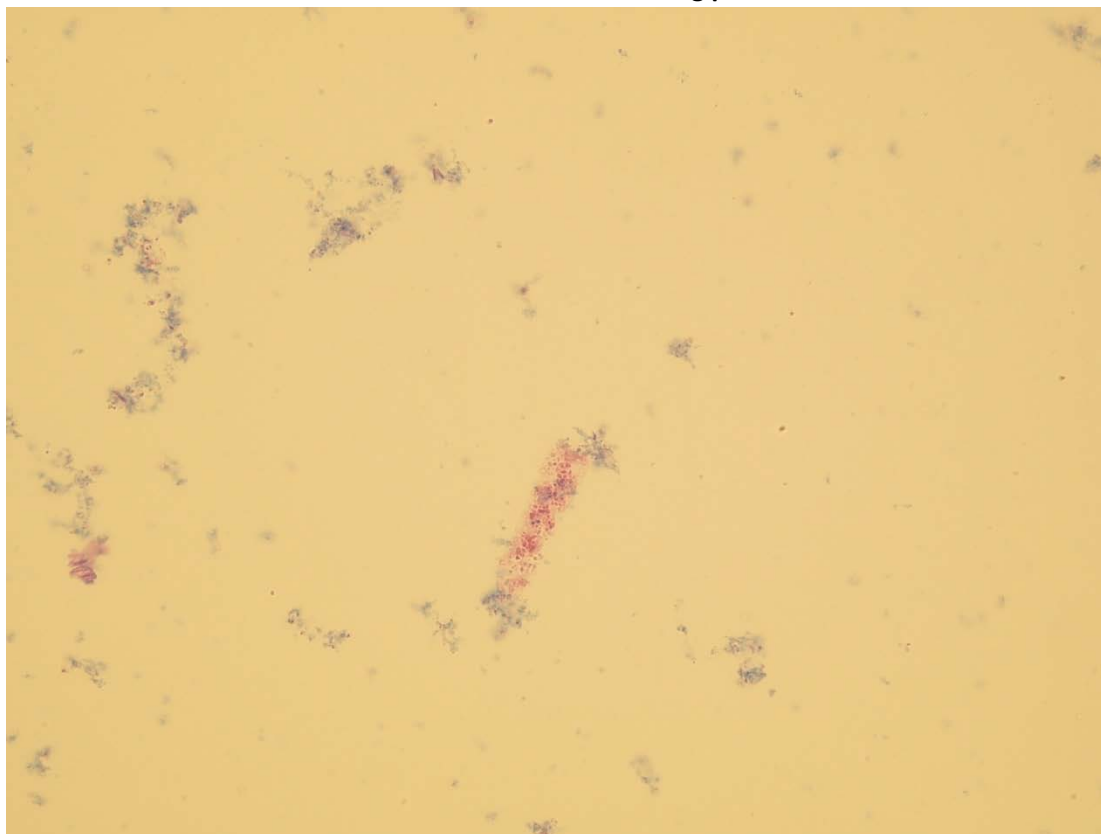
**Bacterial casts - FUS-2000 isolated picture**



**Bacterial casts-Microscopic picture of native sediment**

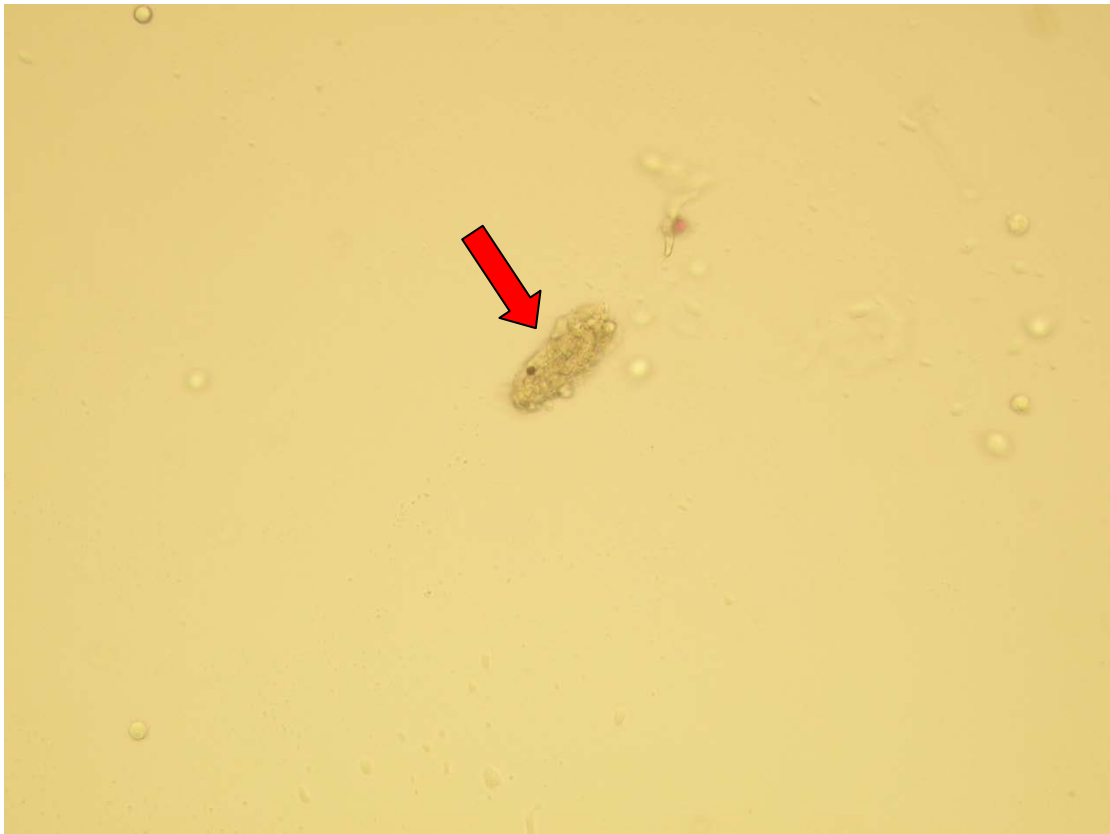


**Bacterial casts - FUS-2000 big picture**

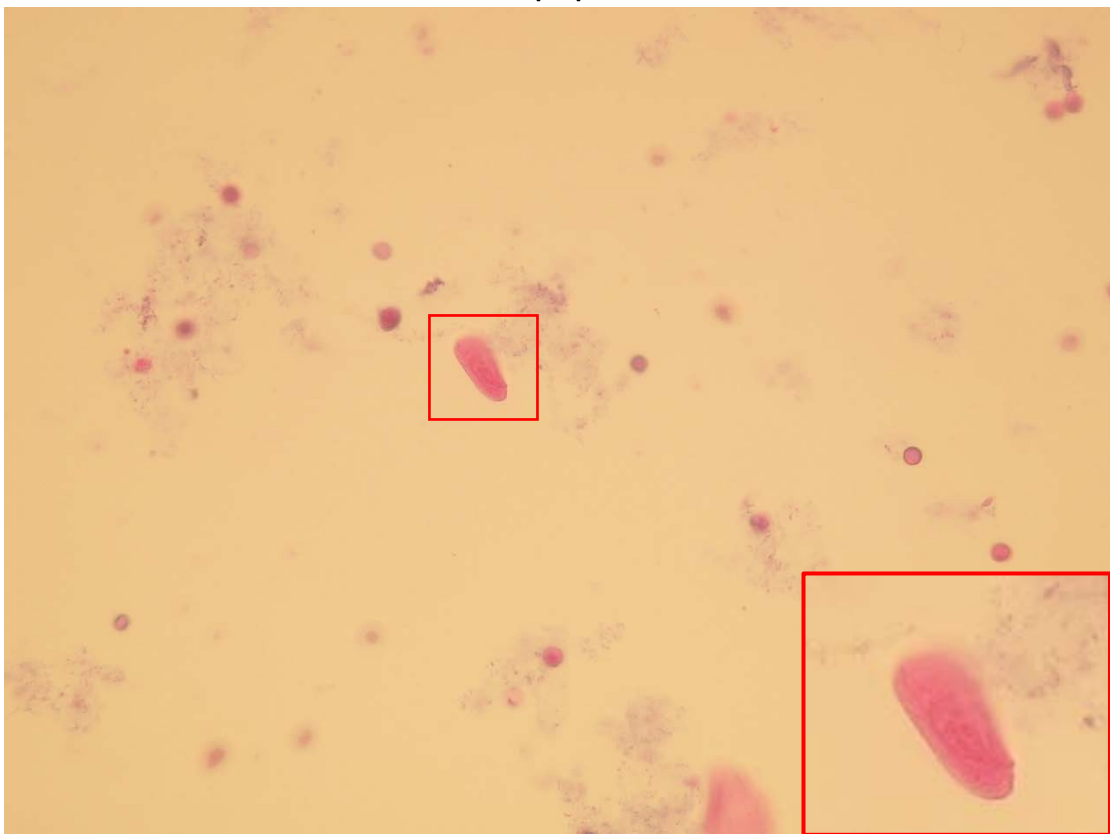


**Bacterial casts-Microscopic picture of stained sediment**

## Nested Casts



Nested casts-Microscopic picture of native sediment



Nested casts-Microscopic picture of stained sediment



## 8. Pseudocasts

Pseudocasts are structures of aggregates that resemble and may be mistaken for casts because of their shape. They are without diagnostic significance. Artifacts don't belong in this category.

- a) Mucus is like long threads, irregular with varied thickness, blurring edges and tapering curly branched ends. They are present in healthy people urine, especially women's. A large number of mucus signifies urethral irritation or inflammation. Mucus can make the dry chemistry results positive as mucus contains protein. Cell aggregates that may or may not be entrapped in mucus are similar to cellular casts.
- b) Pseudo-cylinders are similar to hyaline casts, in spiral curls with one end or both ends tapered. It may be mucus generated in collecting tubules or might be hyaline casts that are not yet formed, often coexisting with hyaline casts. They are commonly seen in renal blood circulation disorders.

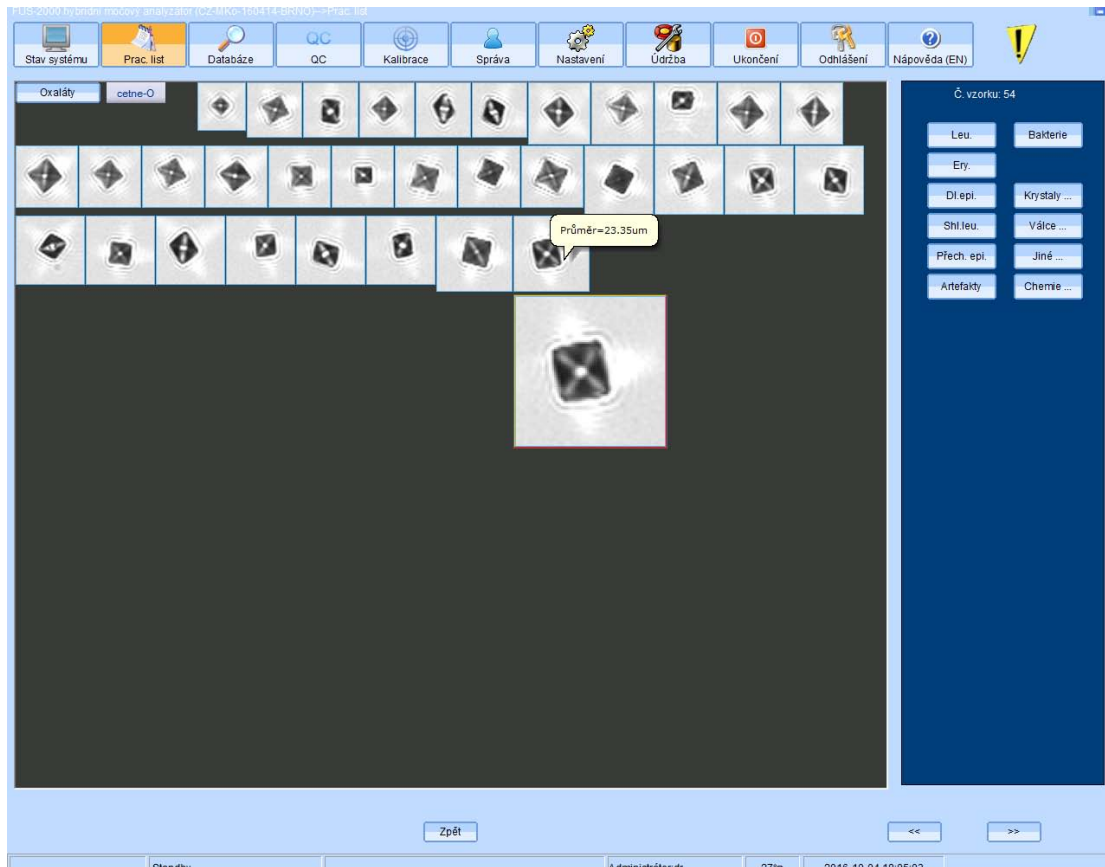
# Crystals

## A. Features of normal crystals

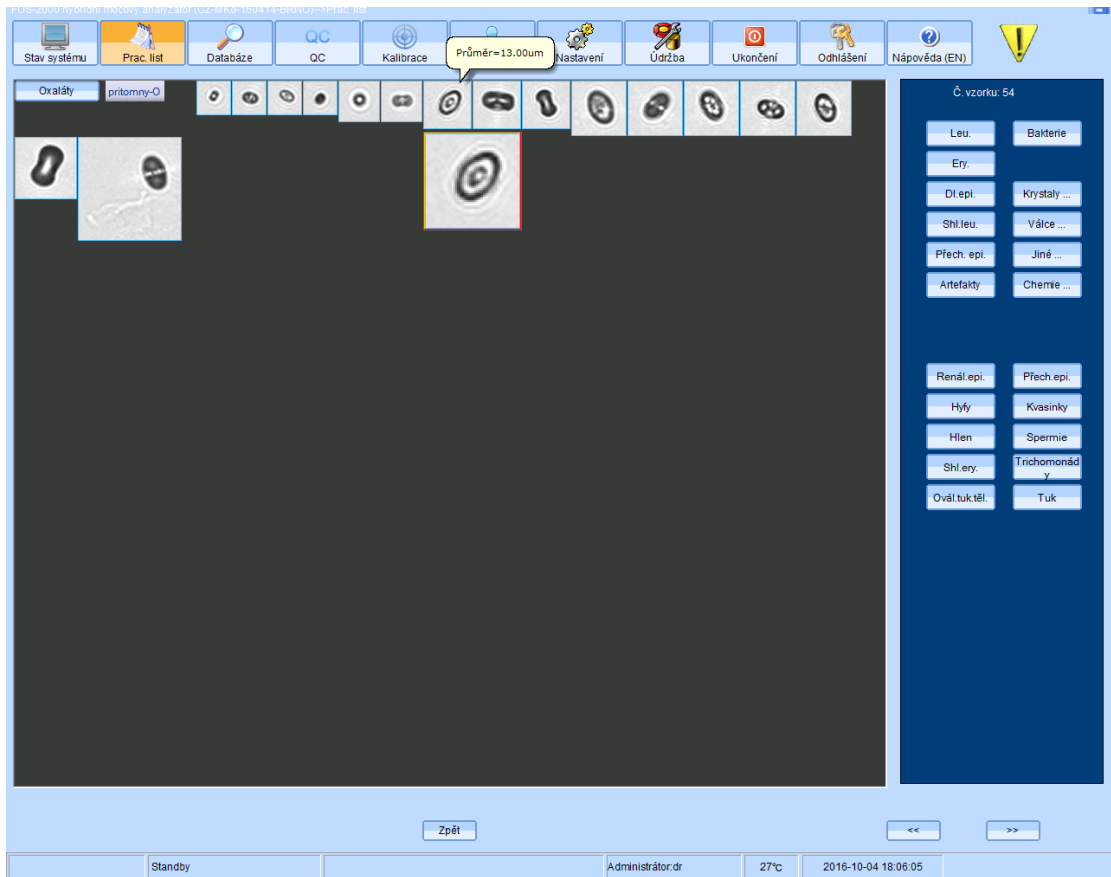
Normal crystals originate mostly from food and the body's metabolism, usually without any clinical significance. But some crystals, such as calcium oxalate crystals, appear in the urine of healthy people due to taking vegetable food, are one of the diagnoses of urinary tract stones when presenting in sustained large amount.

1. **Calcium oxalate crystals** are mostly colorless, square octahedron with strong refraction. They can be divided into two categories: Calcium oxalate dihydrate - highlighting diagonals crossed (envelope-shaped) and calcium oxalate monohydrate crystals - in dumbbell-shaped ("8" shape), oval or circular form. Oval and circular calcium oxalate crystals are similar to RBCs. (Identification method: oxalate crystals are soluble in hydrochloric acid but insoluble in acetic acid and sodium hydroxide. To differentiate from RBCs, add acetic acid to dissolve RBCs while calcium oxalates remain unchanged. ) They have low solubility, easy to precipitate in the urine. If appearing in fresh urine in large number accompanied with RBCs and there are irritation symptoms in kidney or bladder, it is mostly signs of kidney or bladder stones. About 90% of urinary stones are calcium oxalate crystals, sometimes mixture of calcium oxalate and calcium phosphate, which is related to the facts that phosphate crystals are easy to precipitate in alkaline urine.

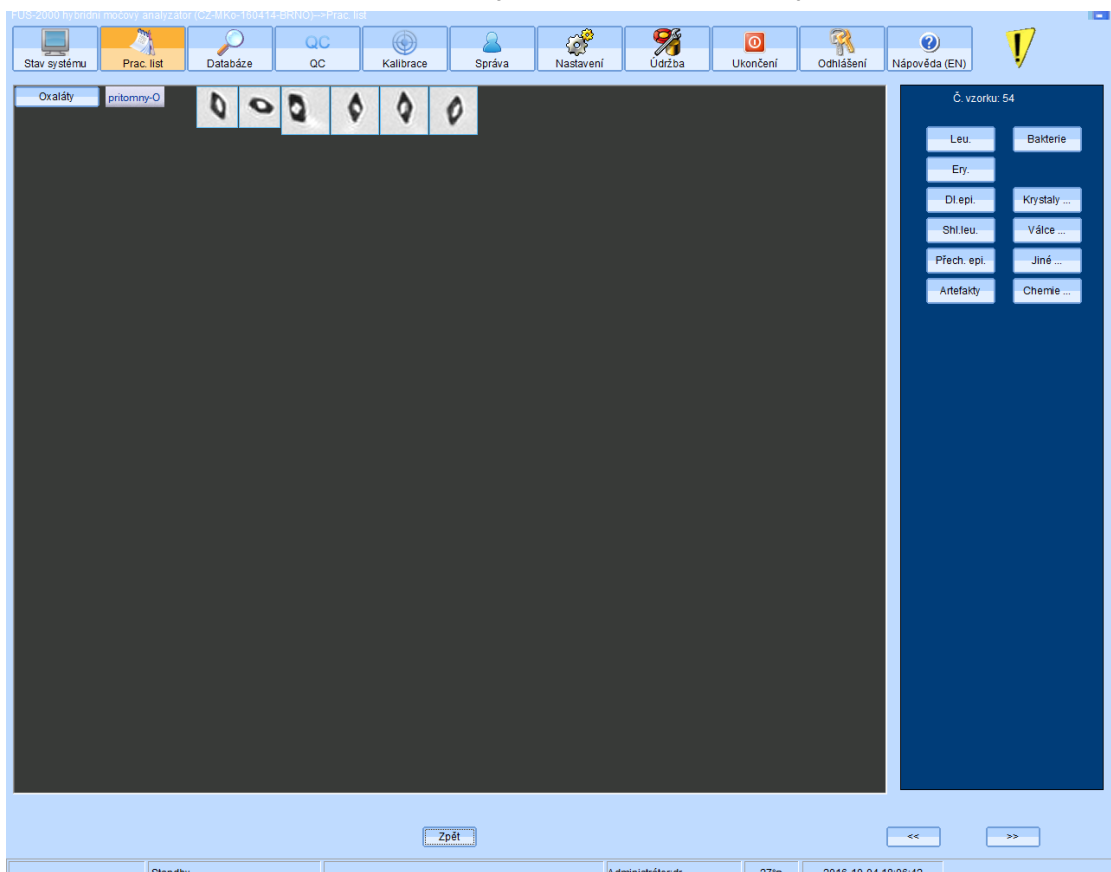
## Calcium oxalate crystals



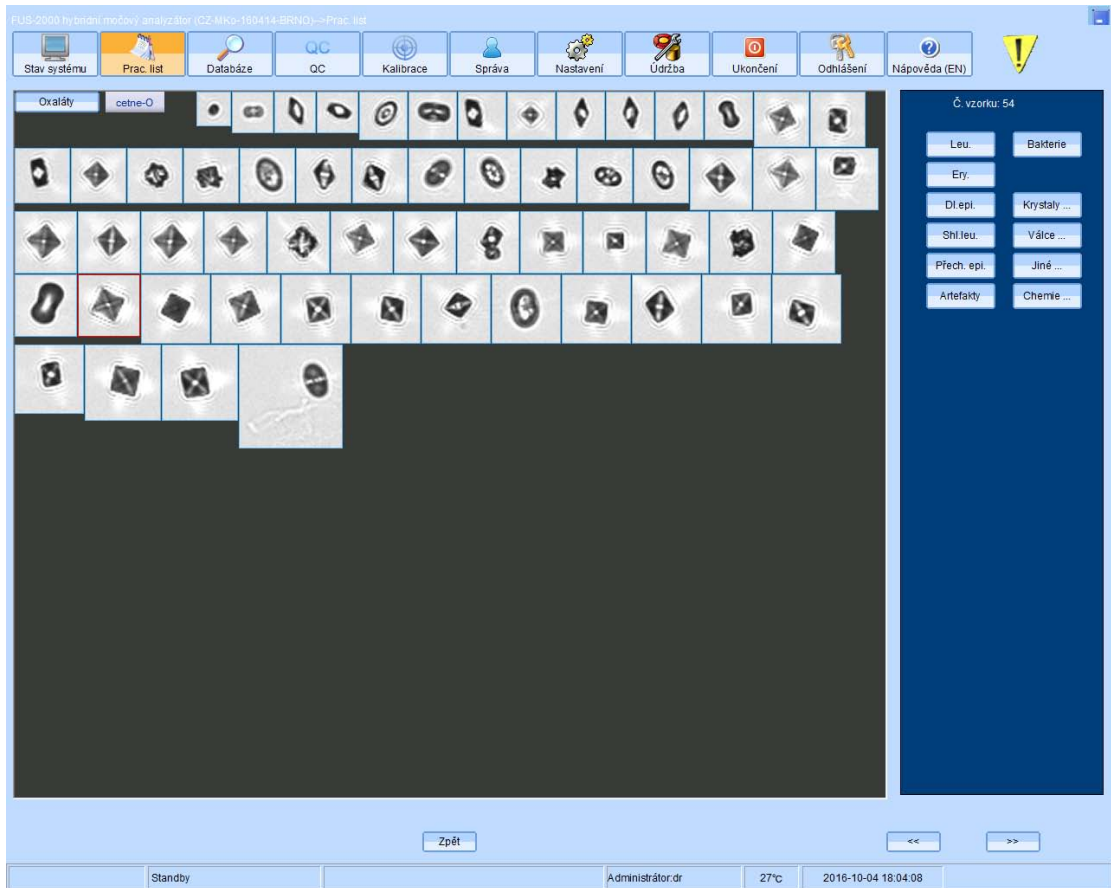
Calcium oxalate crystals - FUS-2000 isolated picture



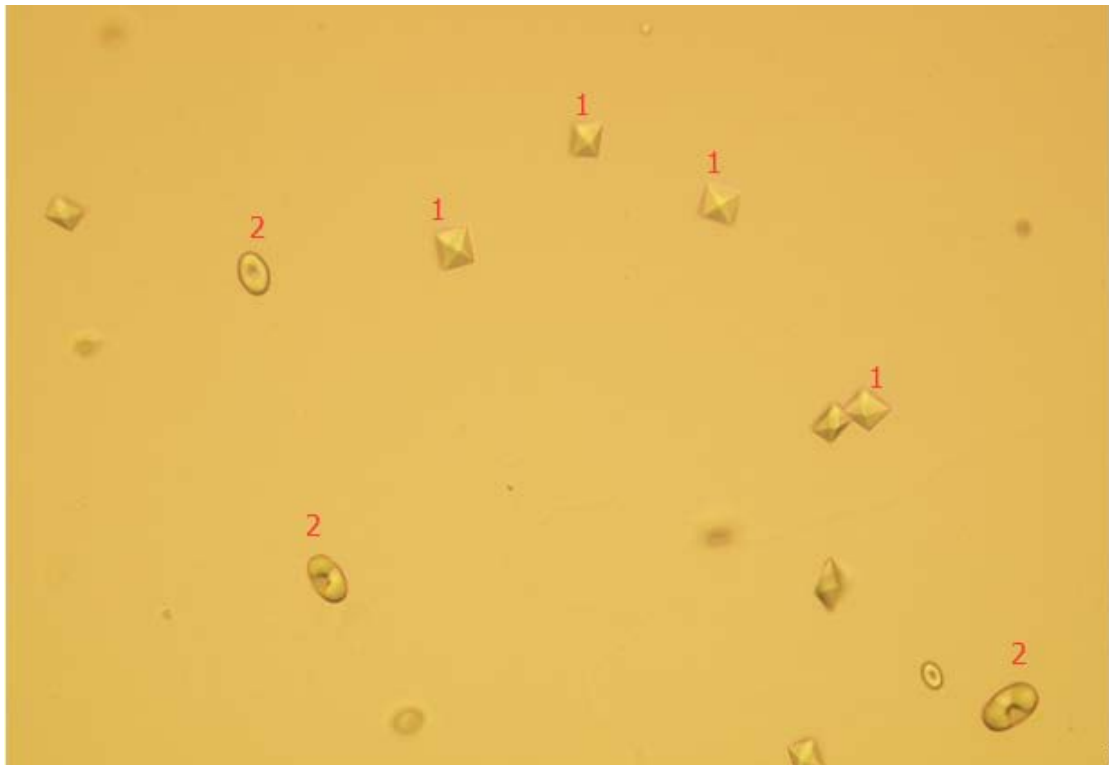
Calcium oxalate crystals - FUS-2000 isolated picture



Calcium oxalate crystals - FUS-2000 isolated picture

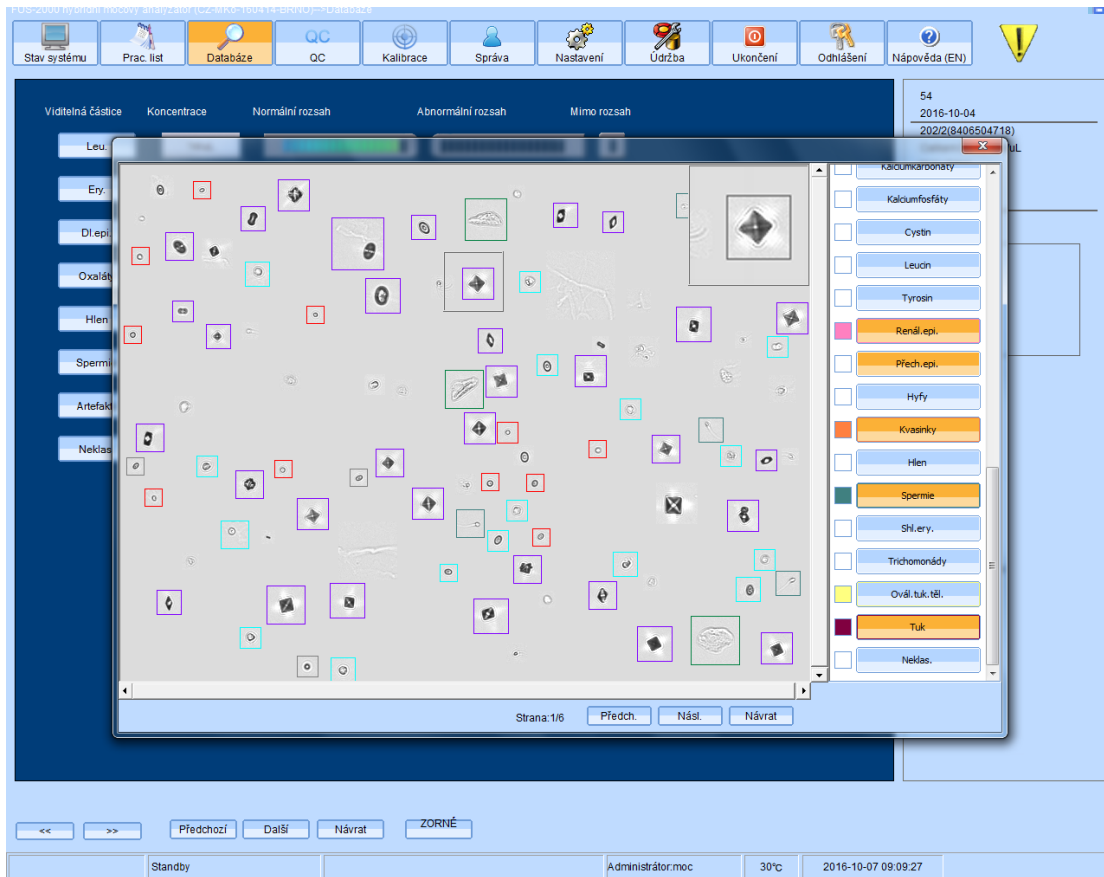


Calcium oxalate crystals - FUS-2000 isolated picture

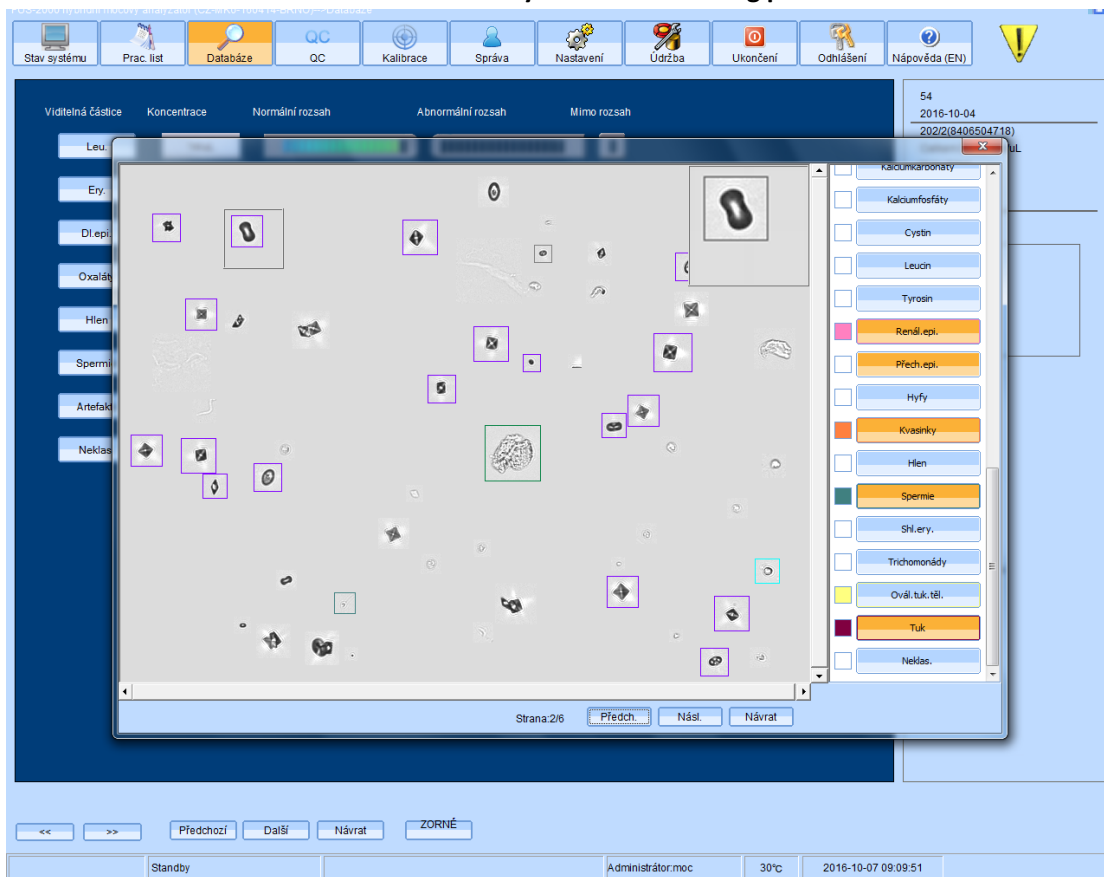


1. Calcium oxalate monohydrate    2. Calcium oxalate dehydrate

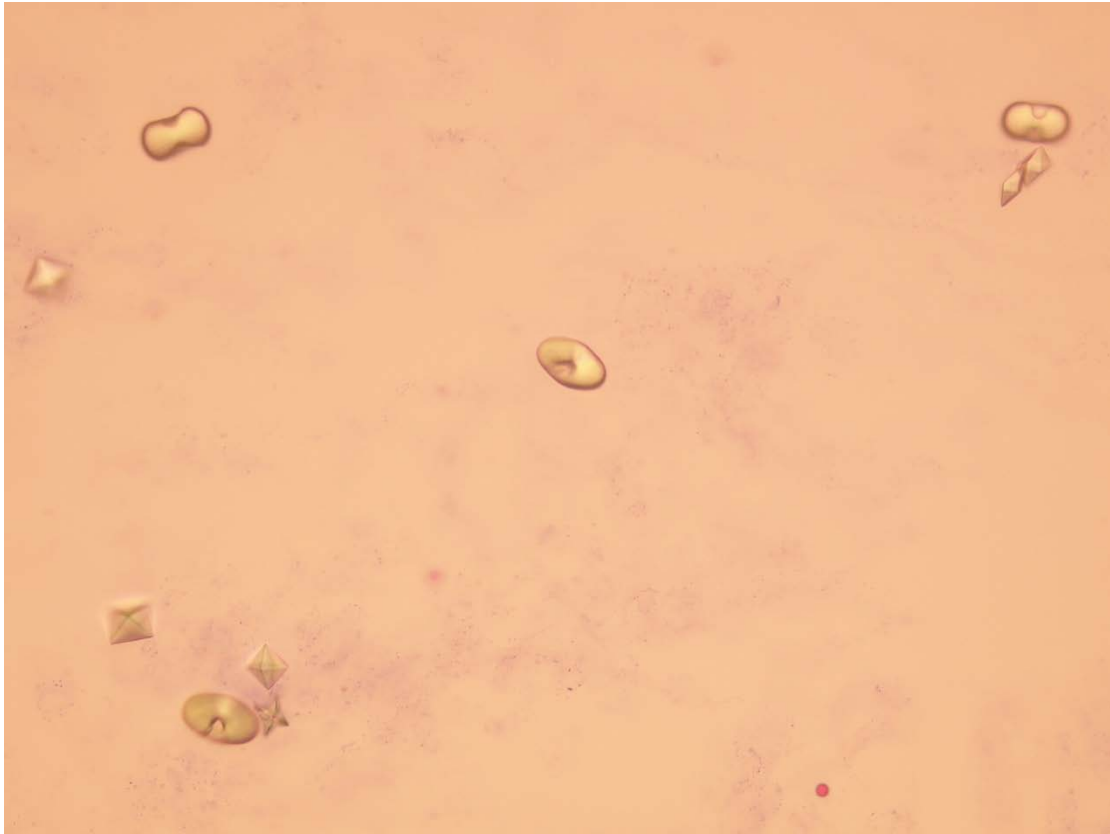
Microscopic picture of native sediment



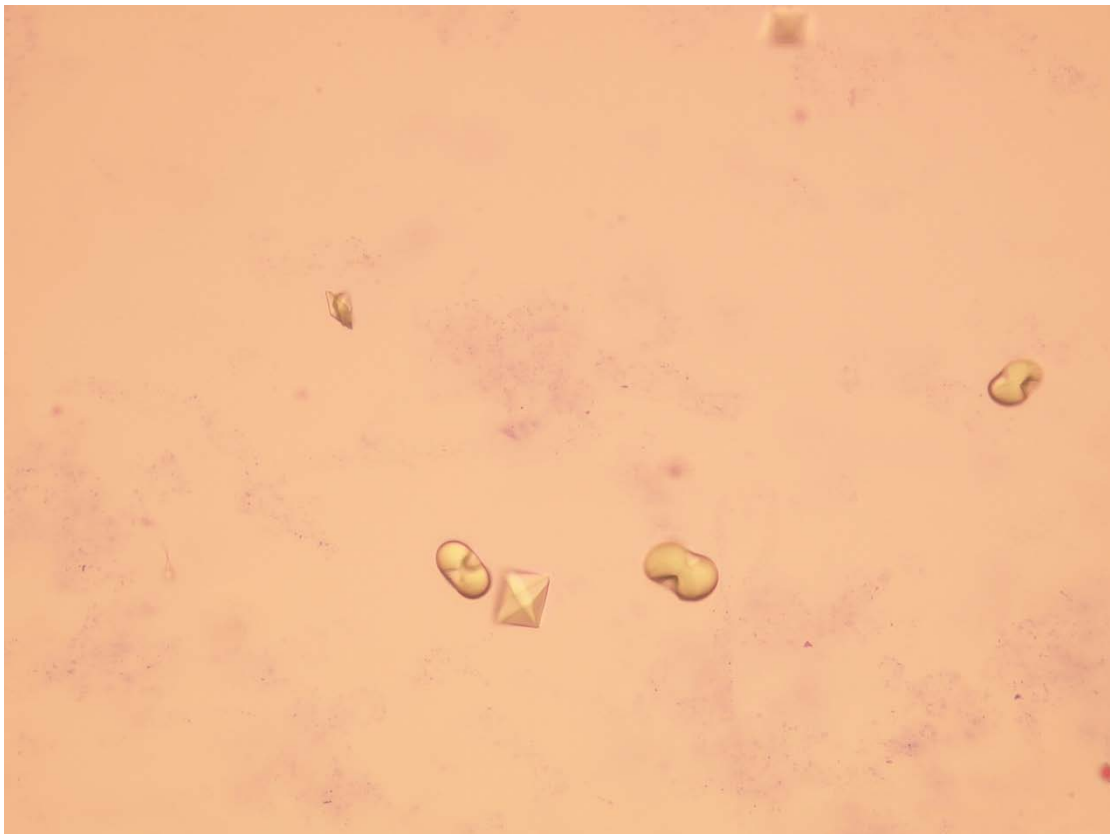
Calcium oxalate crystals - FUS-2000 big picture



Calcium oxalate crystals - FUS-2000 big picture



**Calcium oxalate crystals - Microscopic picture of stained sediment**

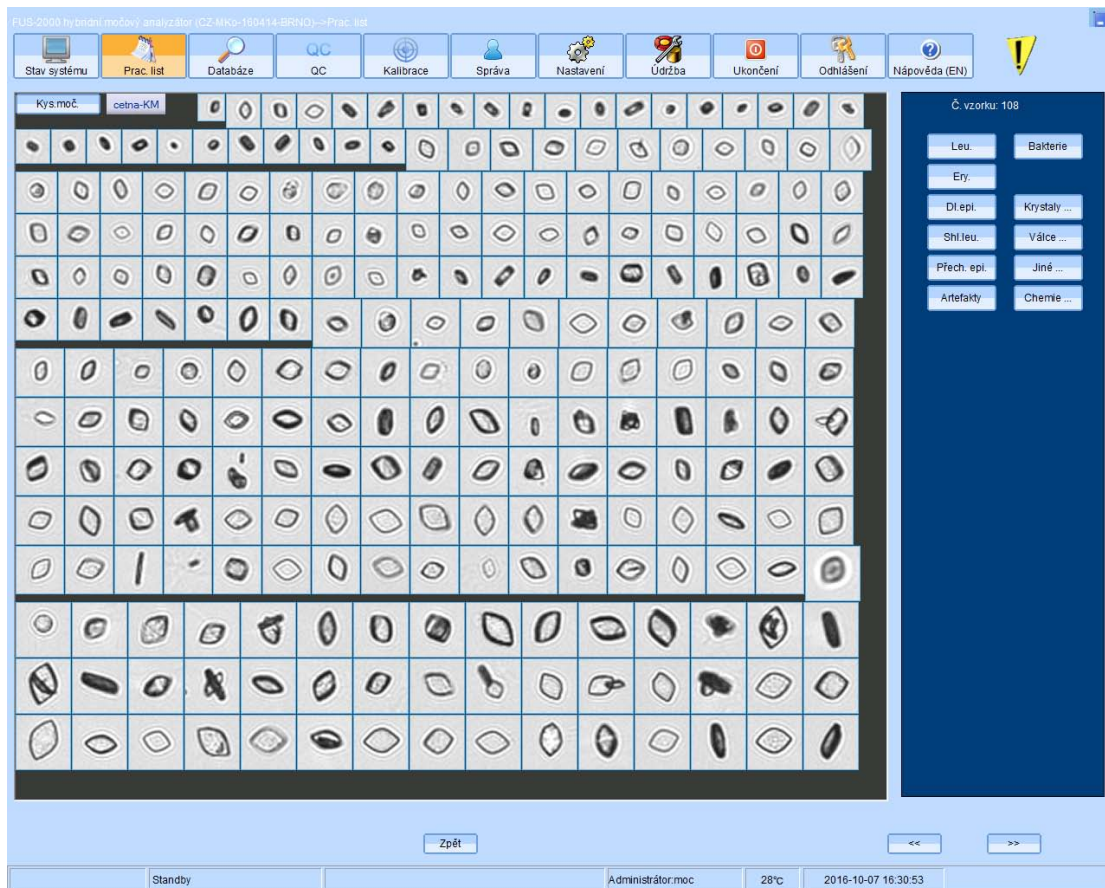


**Calcium oxalate crystals - Microscopic picture of stained sediment**

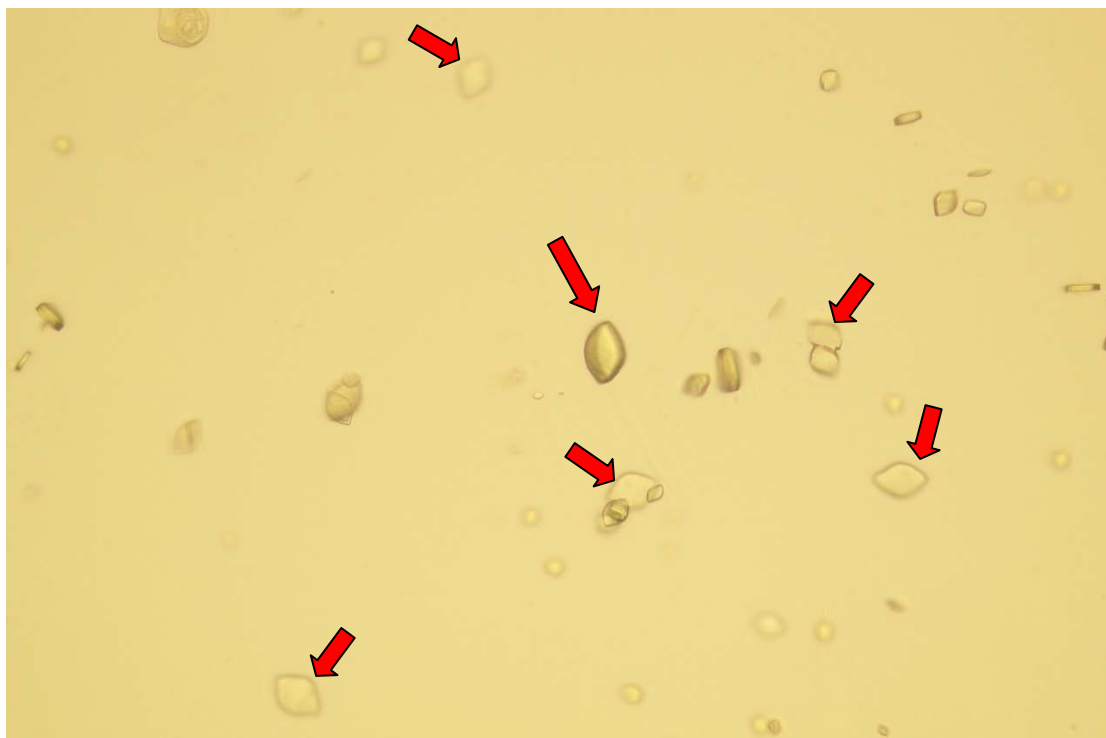


**2. Uric acid crystals:** uric acid is a metabolism product of purine basis and its derivatives, excreted as uric acid or urate, often occurring in acidic urine. Uric acid crystals in urine are colorless, light yellow or yellow-brown. Sometimes they are stuck together by mucus to form a cast shape. Uric acid crystals have diversified shapes and sizes, commonly in triangular prism, rhomboid, dumbbell-shaped, lemon-shaped, butterfly-shaped (petal-shaped), barrel-shaped and "x"-shaped and so on. (Identification method: uric acid crystals are soluble in sodium hydroxide solution but insoluble in acetic acid or hydrochloric acid; Dissolved after adding ammonia to form ammonium urate crystals.) Eating too many animals offal containing purine would cause the increase of uric acid and uric acid crystals in urine. Uric acid crystals appear often in the urine of patients with gout, leukemia and lymphoma. A lot of uric acid deposition in the renal tubules and their interstitium can lead to high uric acid nephropathy and uric acid stones, causing renal tubular blocking and renal tubule interstitial lesions. Impairment of renal tubular re-absorption leads to urine with high urate concentration, which can cause renal failure. High uric acid can be seen in acute gout, acute fever of children, chronic interstitial nephritis. If uric acid crystals increase in patients during chemotherapy, it is the sign that purine metabolism speeds up indicating increased cell damage. Various kinds of uric acid crystals appearing in large amount sustainably is likely to cause above diseases.

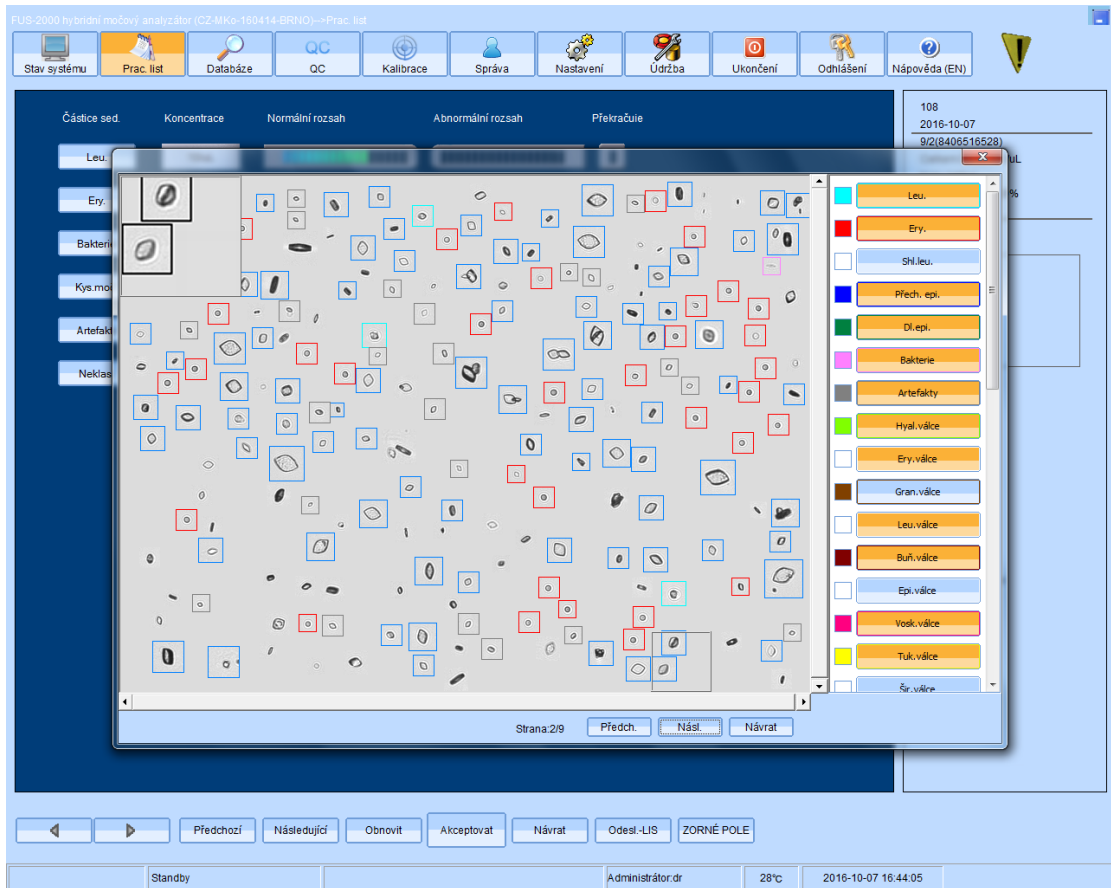
## Uric acid crystals



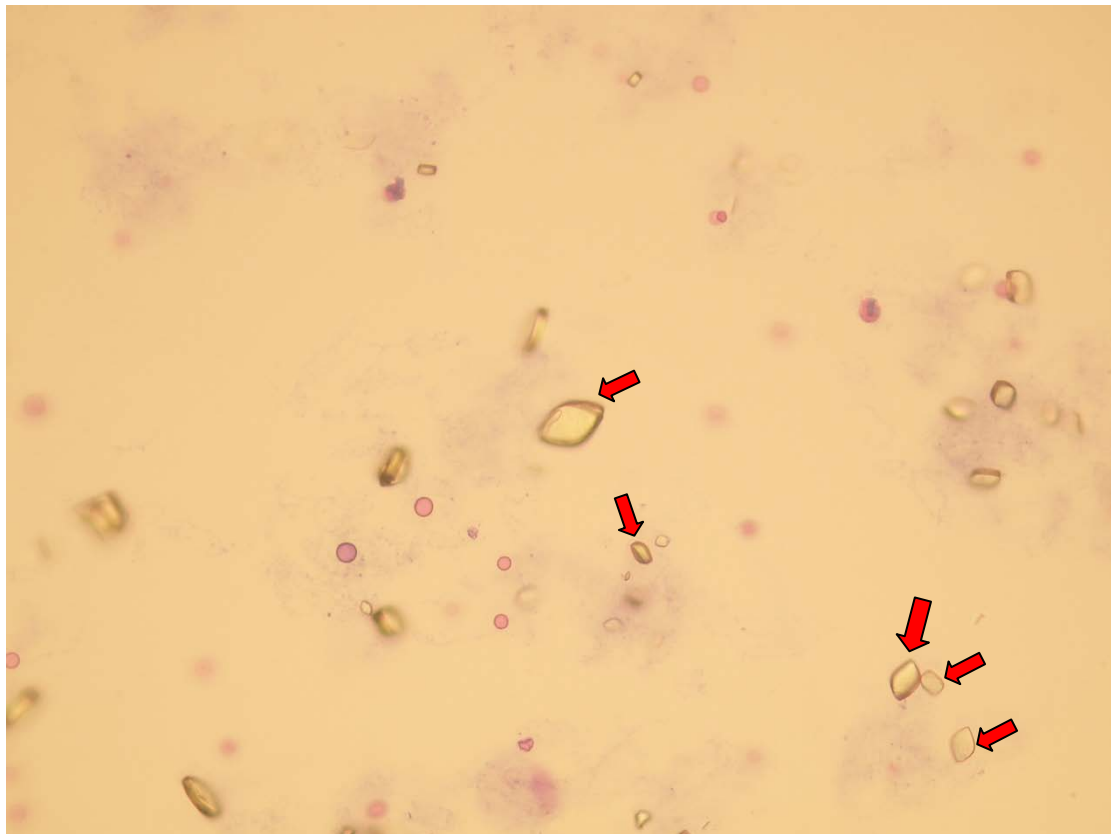
Uric acid crystals - FUS-2000 isolated picture



Uric acid crystals - Microscopic picture of native sediment



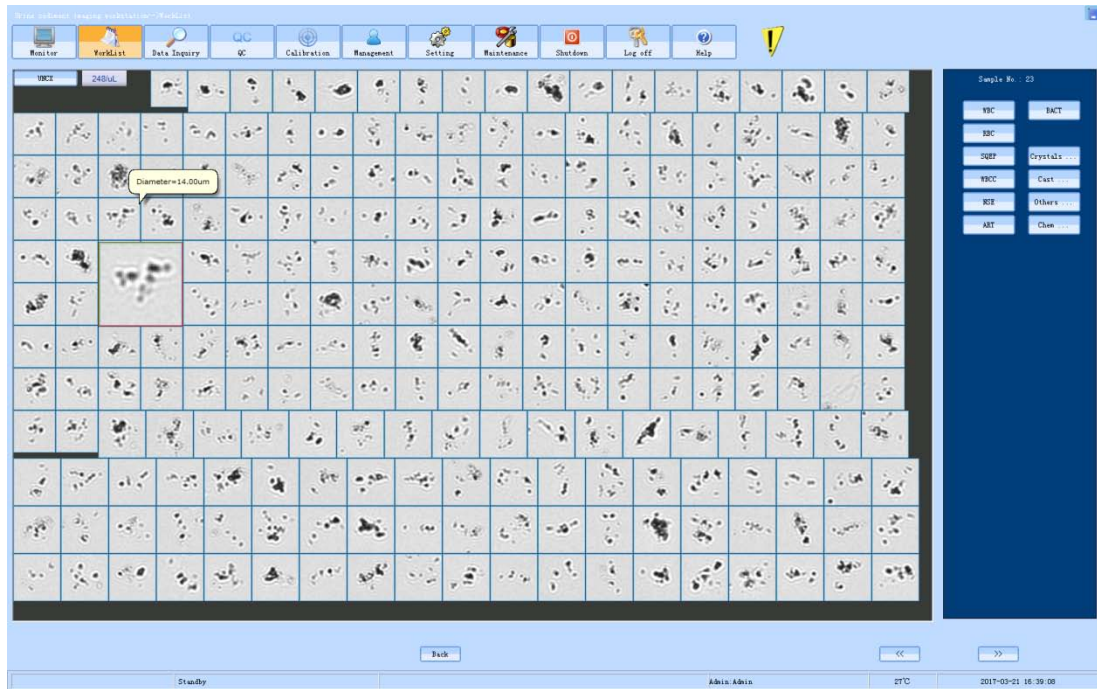
**Uric acid crystals - FUS-2000 big picture**




**Uric acid crystals - Microscopic picture of stained sediment**

- 3. Amorphous urates** are mainly mixtures of sodium urate, potassium urate, calcium urate and magnesium urate microcrystals. When urine is at low temperature, in concentrated or strong acidic condition, it is easy to precipitate the non-crystal urate. Calcium urates are in pale yellow, in ball or rhombic shape encircled with thorn-like protrusions and dissolved in heat and acid condition. They are commonly seen in newborns' or alkaline urine, usually without any clinical significance. (Identification method: dissolve by heating. Dissolve by adding acetic acid then to reform uric acid crystals).

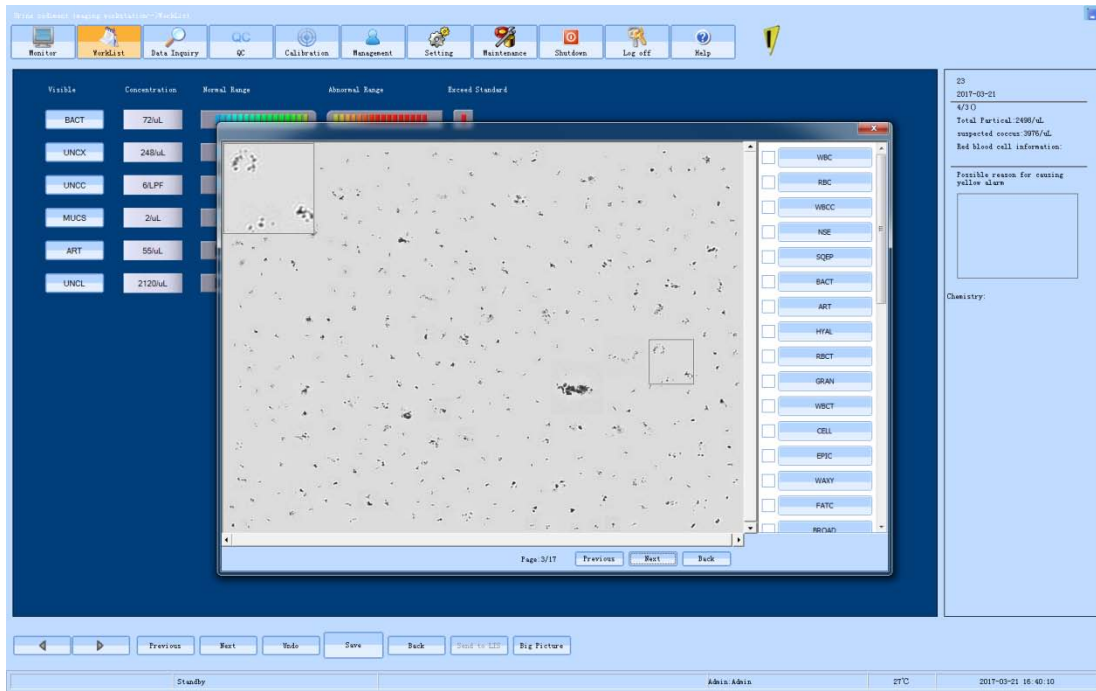
## Amorphous urates



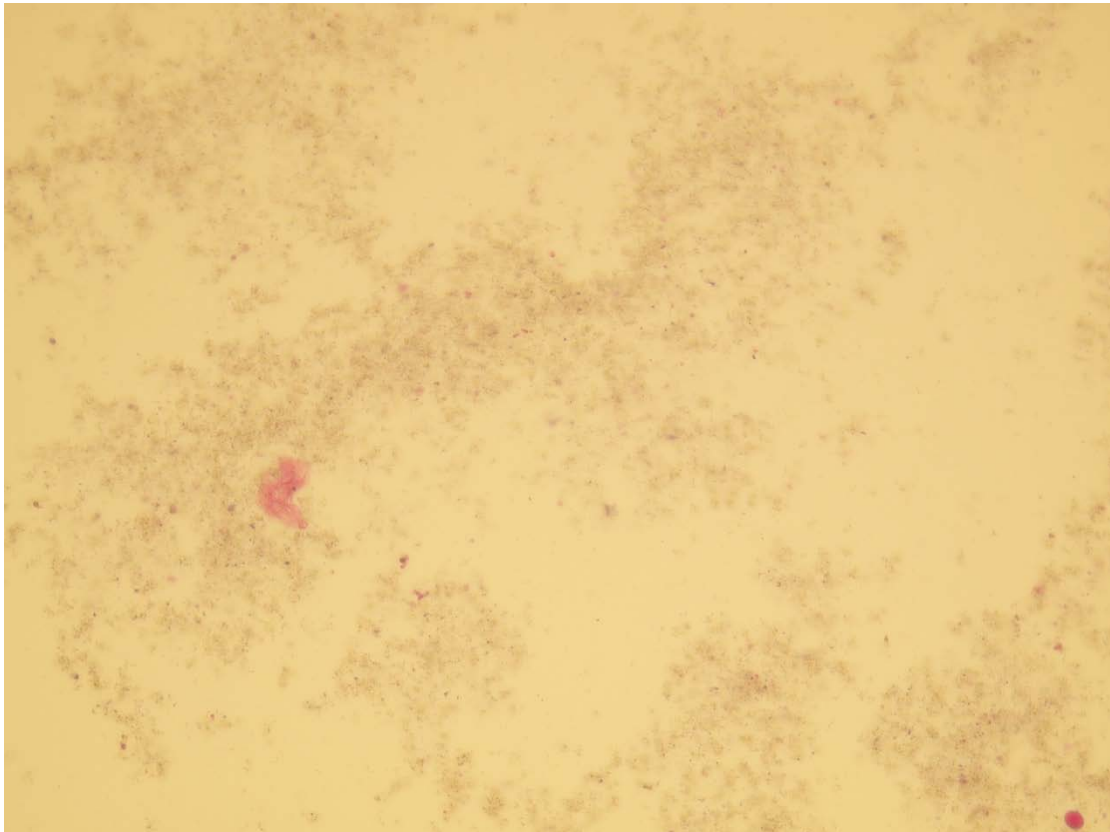
**Amorphous urates - FUS-2000 isolated picture**



**Amorphous urates - Microscopic picture of native sediment**



**Amorphous urates - FUS-2000 big picture**



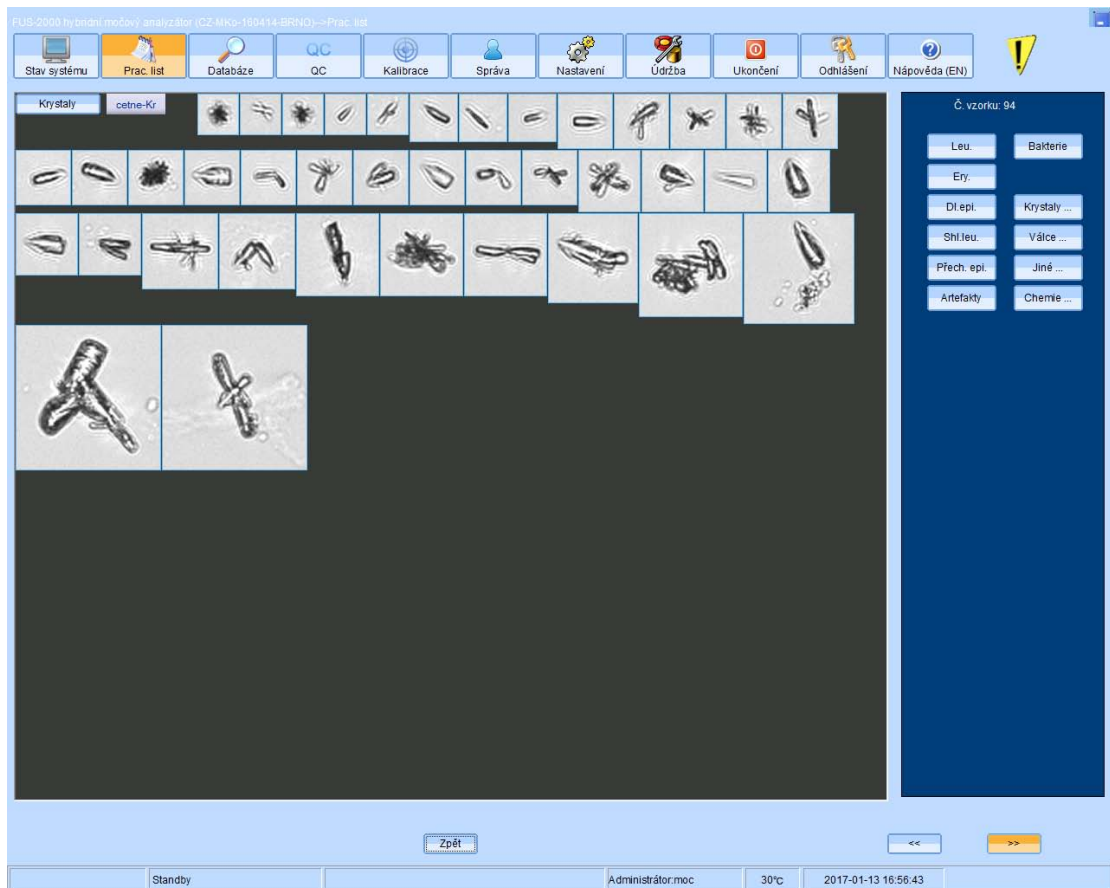
**Amorphous urates - Microscopic picture of stained sediment**

- 4. Hippuric Acid crystals** are normal composition in human and herbivore urine, more in herbivore urine, combination products of benzoic acid and glycine. The morphology is related to the crystallization velocity, including needle shape, plate shape, rhombic prism shape or triangular prism shape. There is often color in the urine with no clinical significance. (Identification method: heating to dissolve and soluble in hydrochloric acid, potassium hydroxide.) Appear only in acidic urine and occasionally when people eat many vegetables.

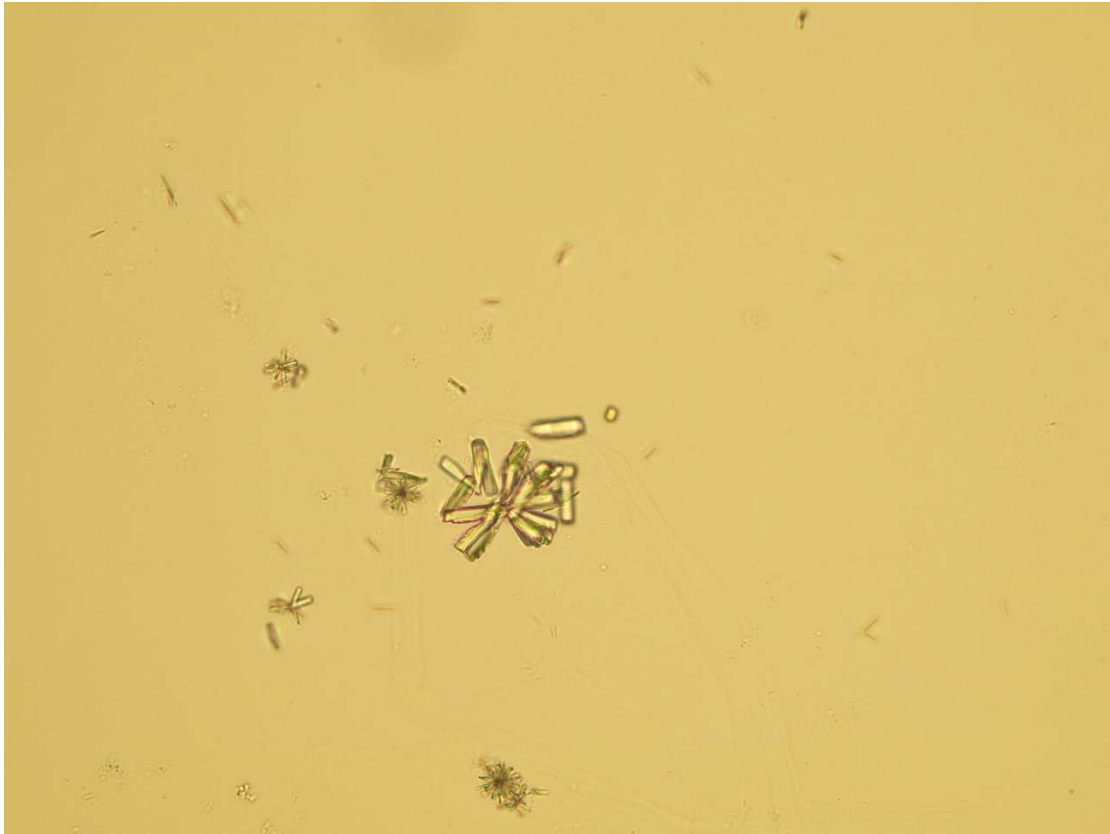


5. **Phosphate crystals** include calcium phosphate, triple phosphate, amorphous phosphate, and so on. Often seen in alkaline urine or neutral urine, they originate from food and metabolic tissue decomposition products, normal constituents in urine. Prolonged presence of phosphate crystals suggests the possibility of formation of phosphate stones.
- a) **Calcium phosphate crystals** are common in alkalescent urine. They are colorless or pale gray and mostly in amorphous, flake, columnar, granular, and triangular shapes arranged in star or bundles form. They are found floating on the surface of the urine. These crystals are similar to tyrosine crystals, calcium sulfate crystals, hippuric acid crystals and easily confused. (Identification method: calcium phosphate crystals dissolve in acetic acid and hydrochloric acid, but not in potassium hydroxide; Hippuric acid crystals are not soluble in acetic acid, but soluble in potassium hydroxide, and appear only in acidic urine.) Long-term presence of a lot of calcium phosphate crystals in the urine should be taken into account of the diseases of hyperparathyroidism, renal tubular acidosis, bedridden bone decalcification.
- b) **Triple phosphate crystals** are one the most common crystals in urine. The crystals are double salts, in shape of square column, roof or envelope. They are colorless and have high refraction. It is very easy to identify. (Identification method: heating does not dissolve them but acetic acid and hydrochloric acid do.) The triple phosphate crystals are easily found in the urine of patients with chronic urinary tract infection, which can lead to obstruction of the urinary tract causing urinary calculi.
- c) **Amorphous phosphates** are common in alkaline and neutral urine. They are grey and non-crystal granules. They generally belong to the normal metabolites with no clinical significance.

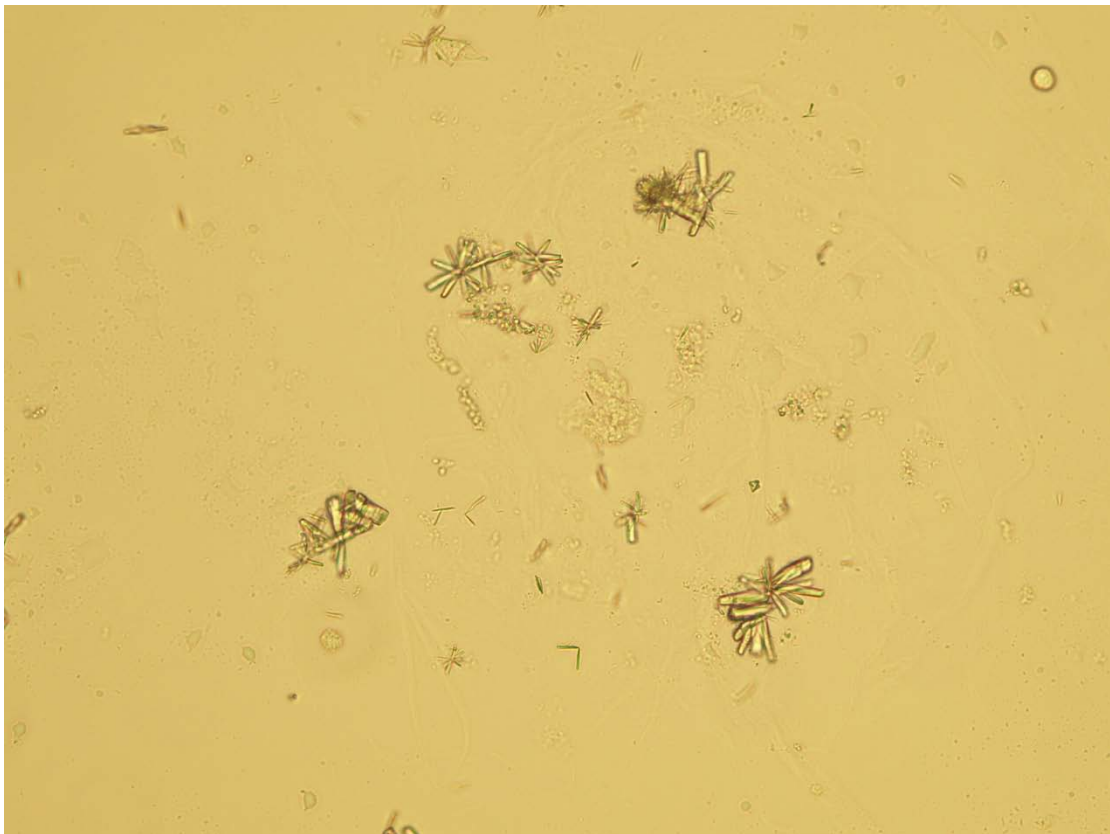
## Calcium Phosphate Crystals



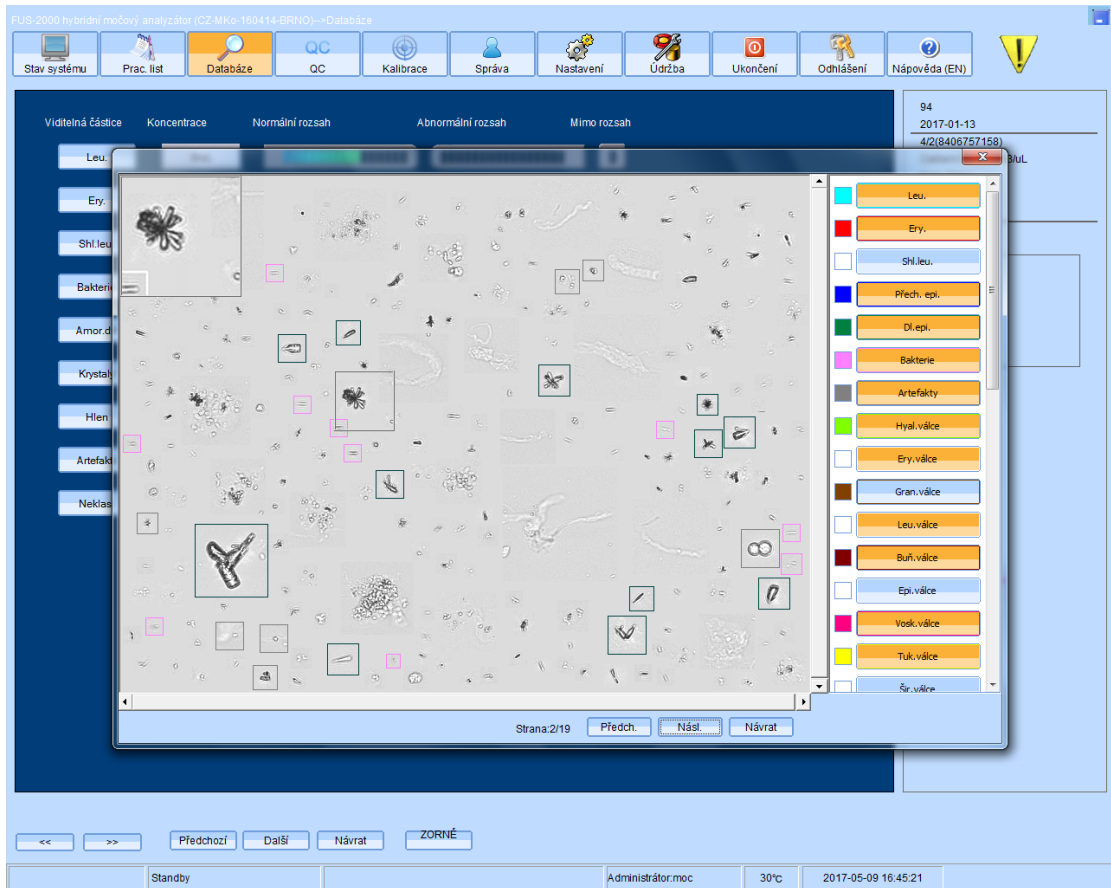
Calcium phosphate - FUS-2000 isolated picture



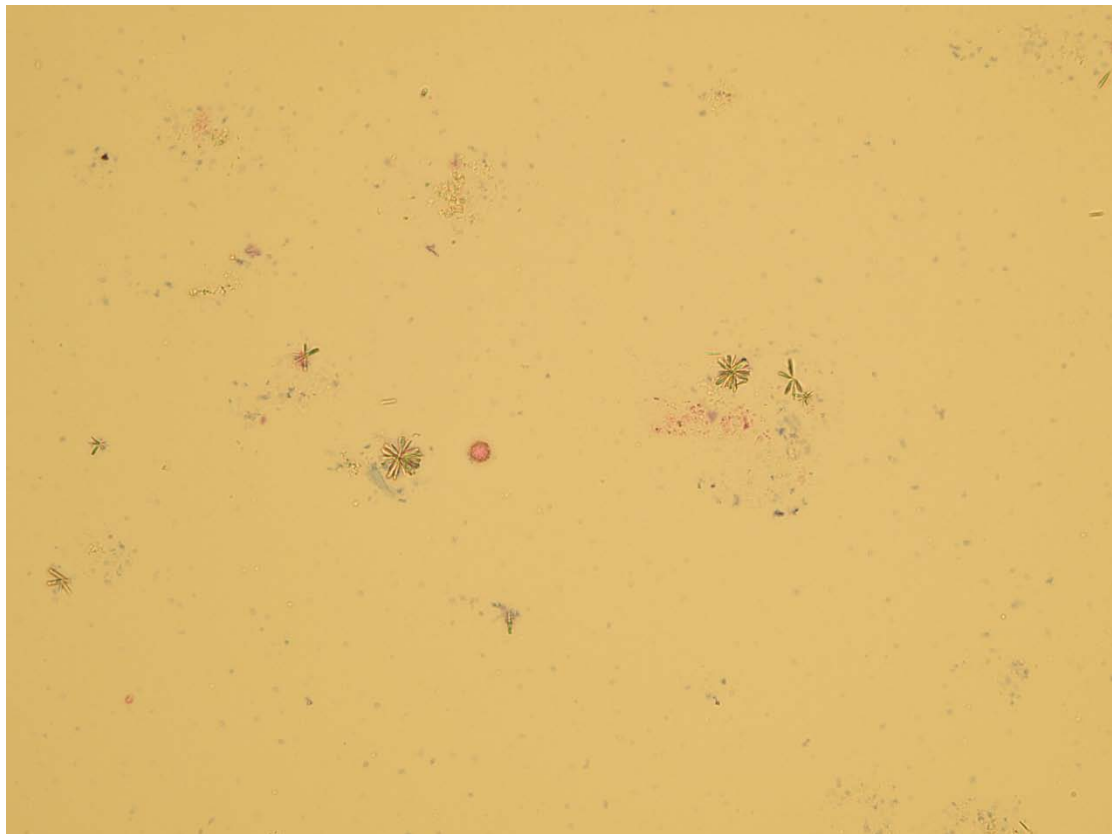
**Calcium phosphate - Microscopic picture of native sediment**



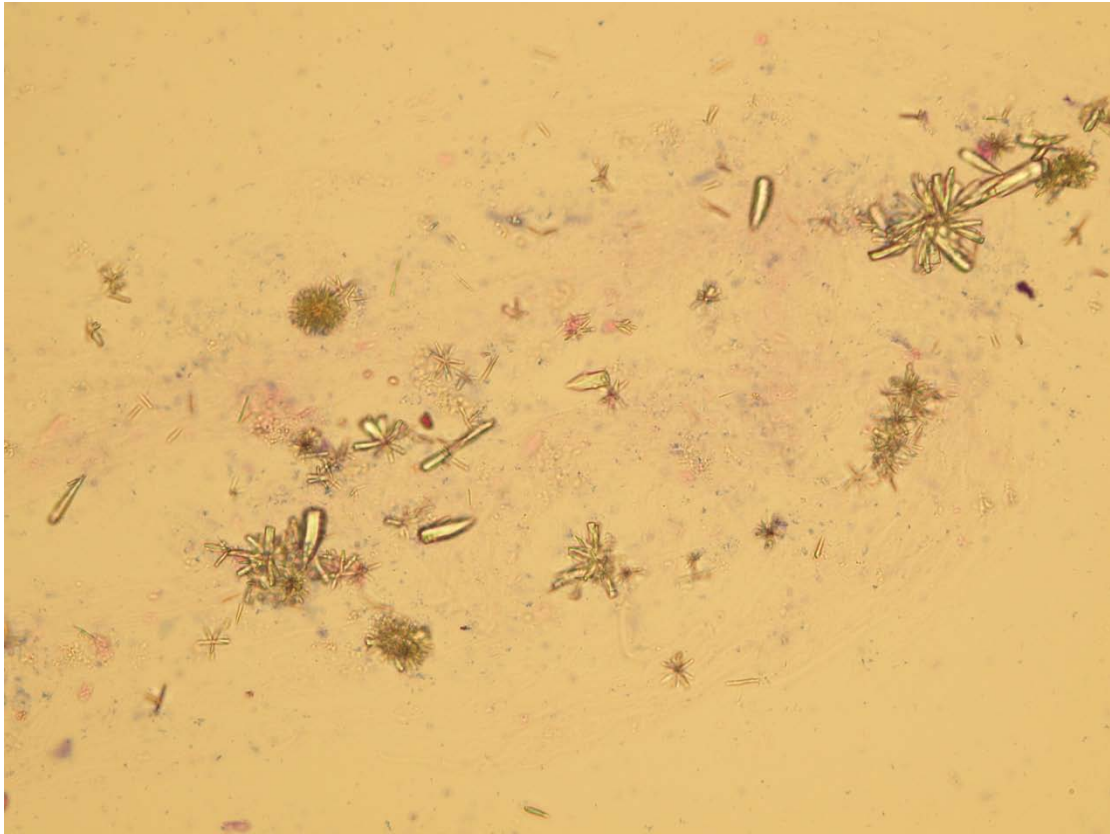
**Calcium phosphate - Microscopic picture of native sediment**



**Calcium phosphate - FUS-2000 big picture**

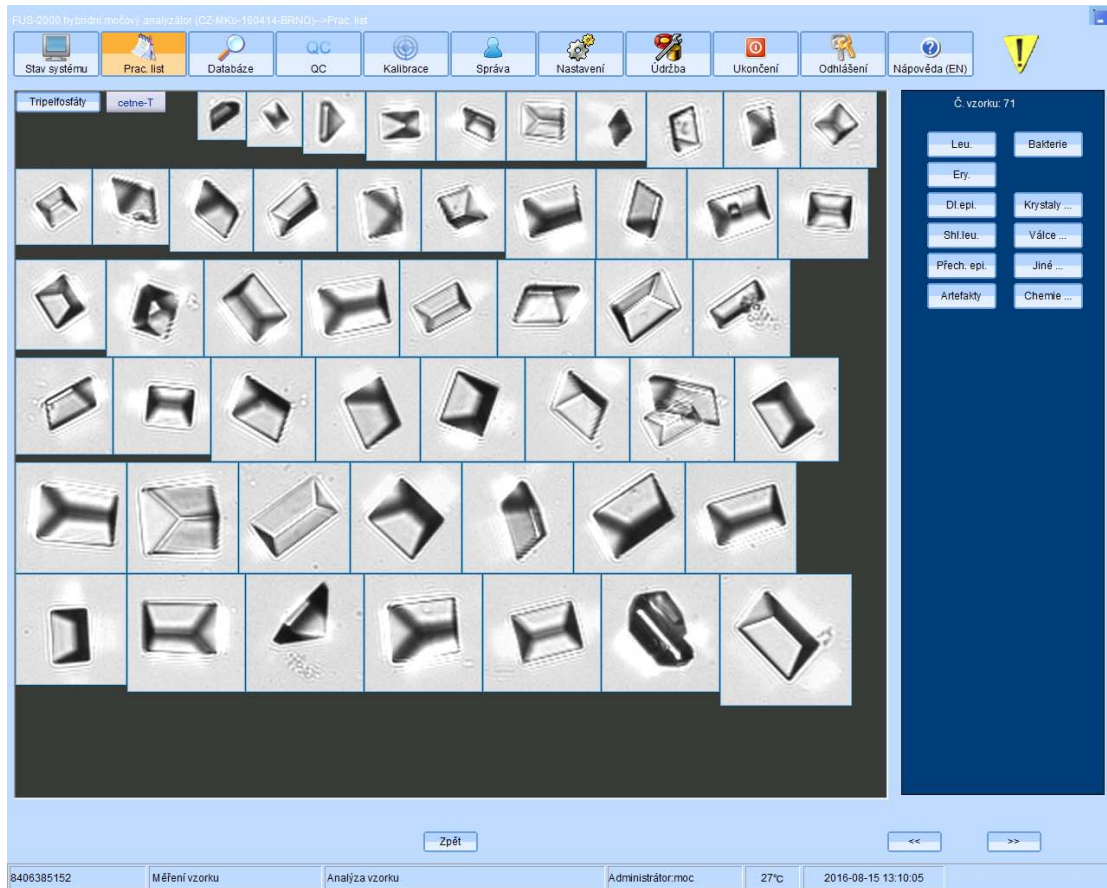


**Calcium phosphate - Microscopic picture of stained sediment**

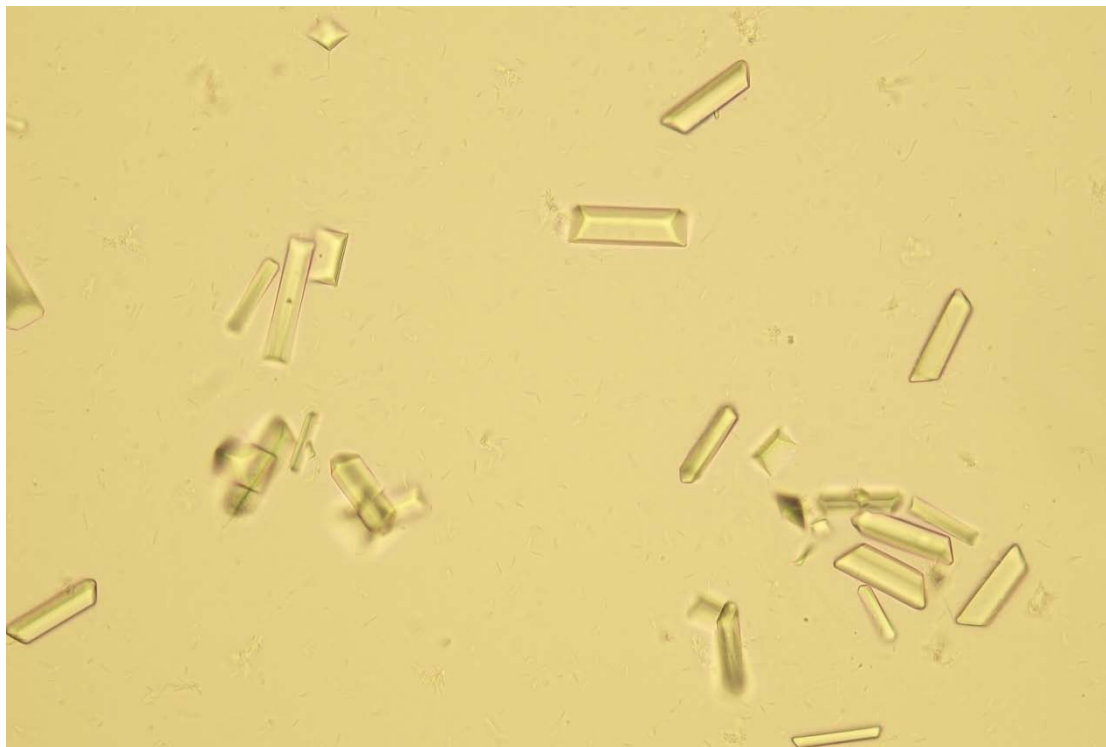

**Calcium phosphate - Microscopic picture of stained sediment**

# Triple Phosphate Crystals

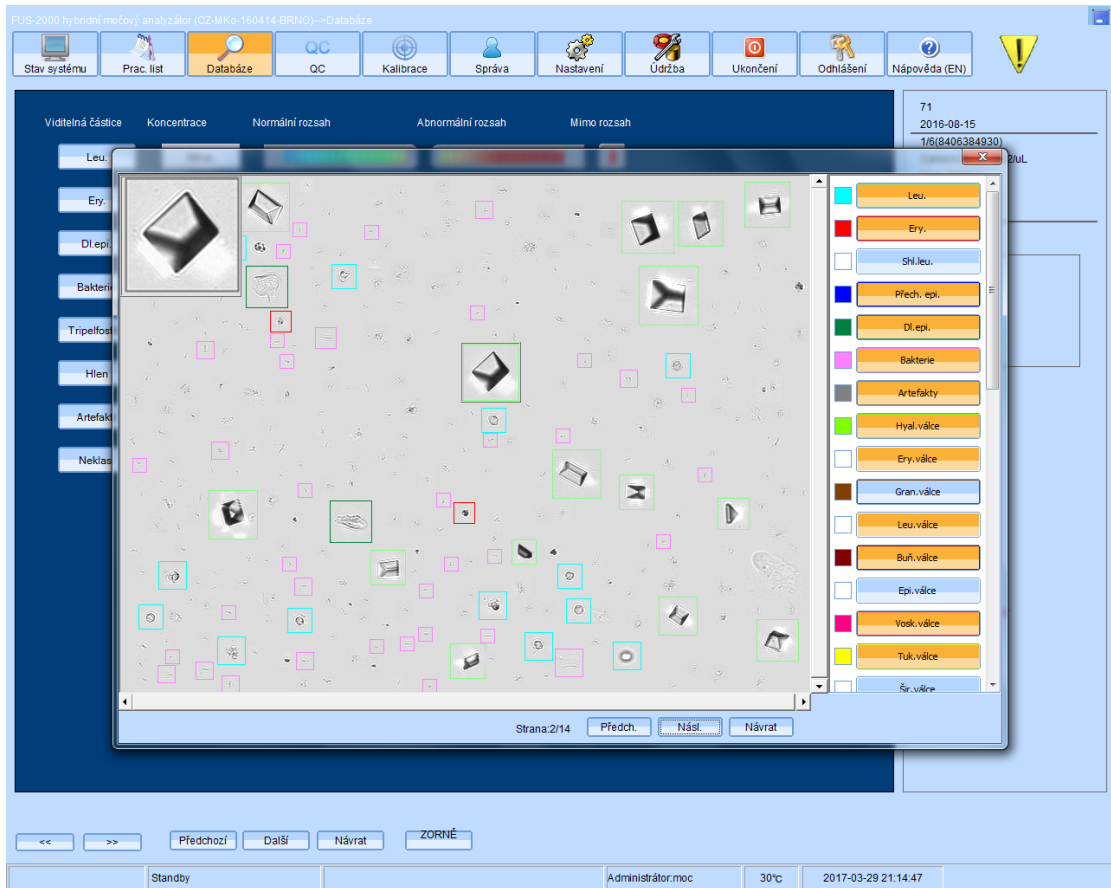


**Triple phosphate crystals - FUS-2000 isolated picture**

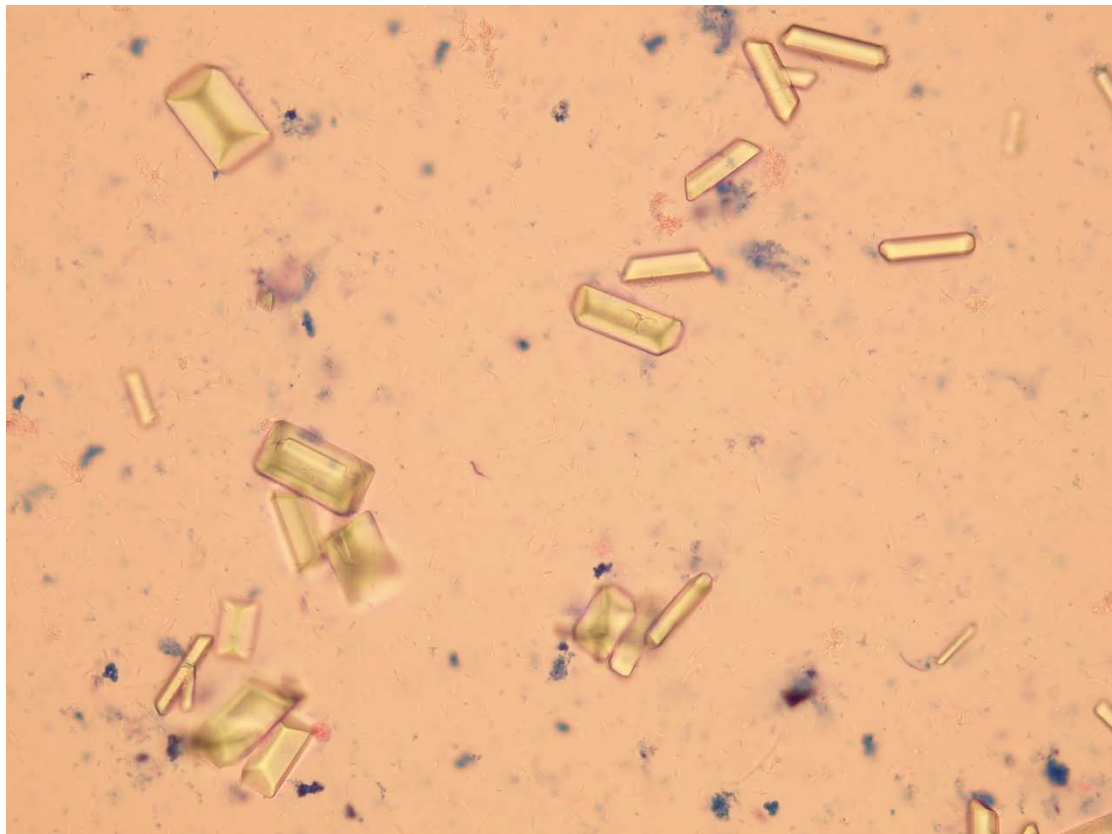


**Triple phosphate crystals - Microscopic picture of native sediment**





**Triple phosphate crystals - FUS-2000 big picture**

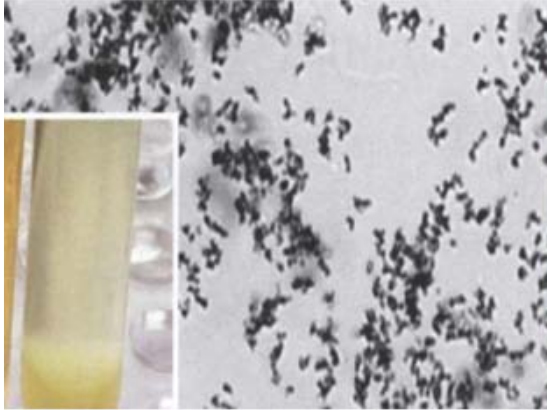


**Triple phosphate crystals - Microscopic picture of stained sediment**



**Amorphous phosphates**

Comparison pictures of amorphous phosphates and amorphous urates. It is nearly impossible to differentiate them under microscope.



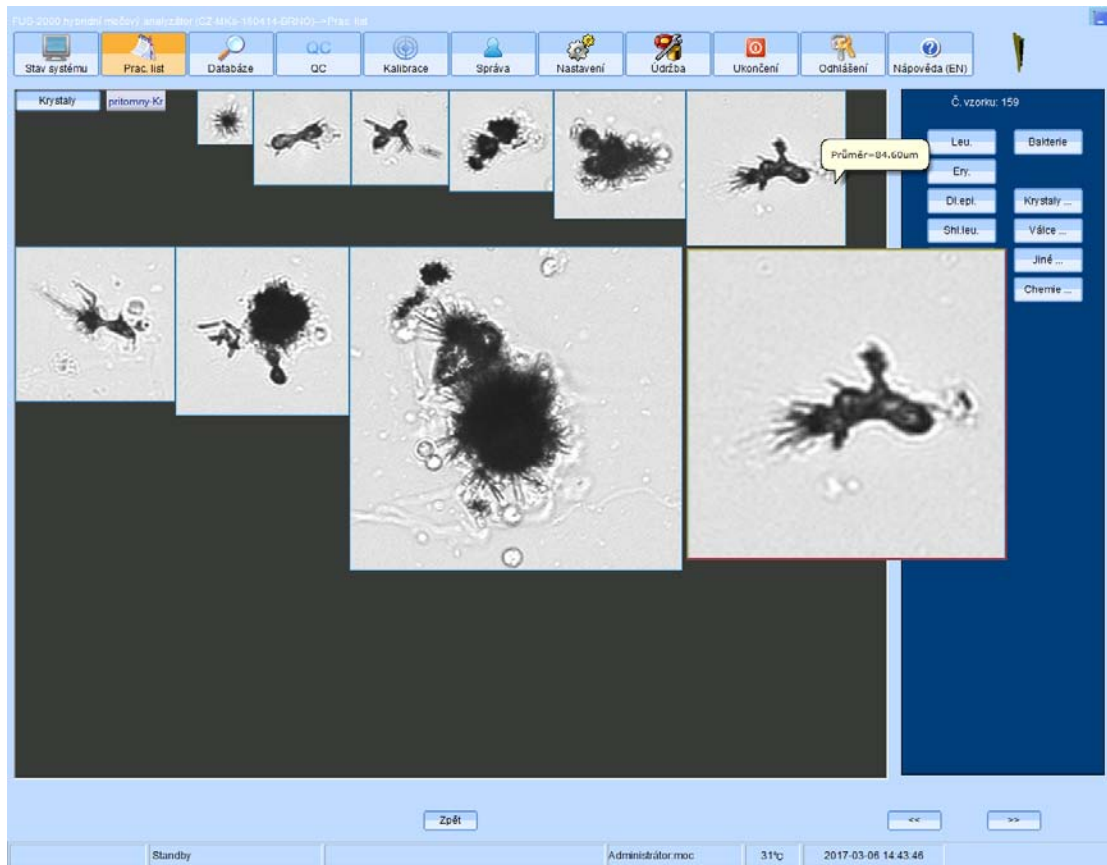
**Amorphous Phosphates-Internet**



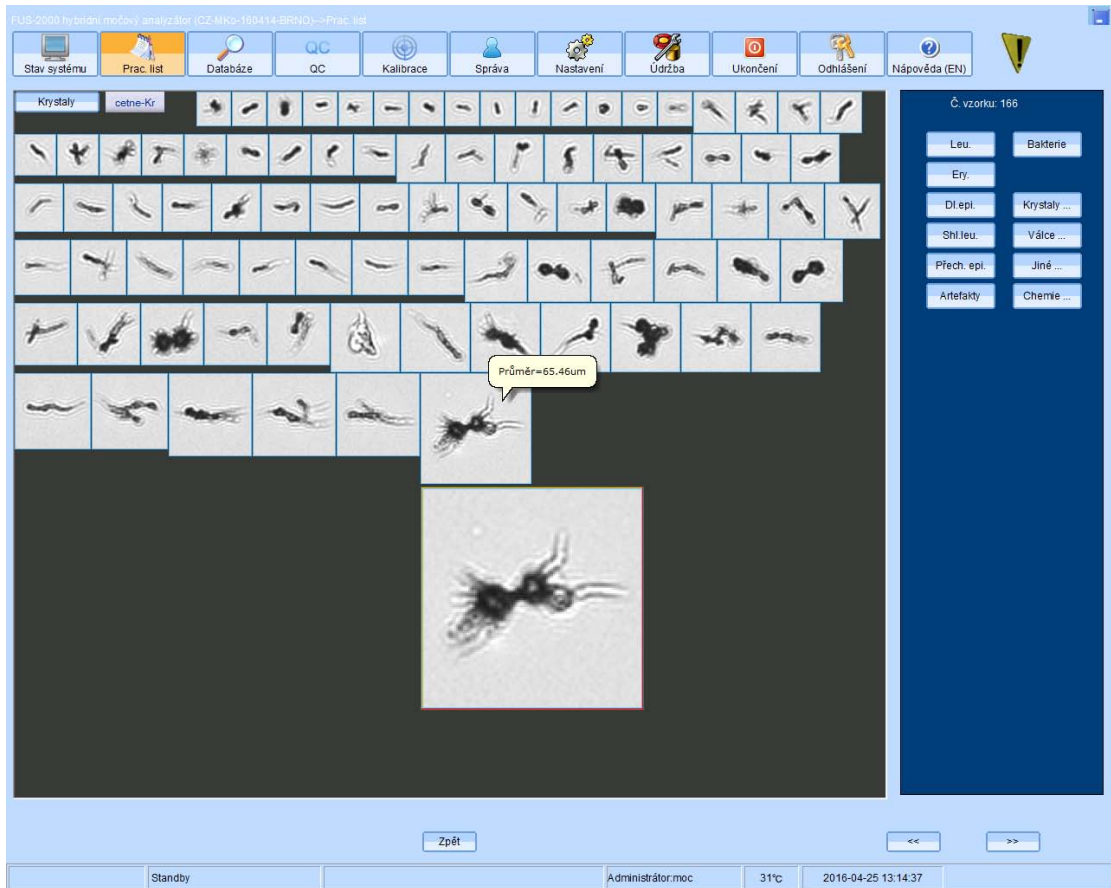
**Amorphous Urates-Internet**

- 6. Ammonium urate crystals** are the only kind of urate crystals in alkaline urine, product of uric acid and free ammonium. Most are yellowish-brown opaque crystals. The typical feature is shape of root or the spine ball, and sometimes dumb-bell shape. (Identification method: Heating acetic acid, hydrochloric acid and potassium hydroxide can all dissolve the ammonium urate crystals.) If a lot of ammonium urate crystals seen in fresh urine, it suggests bacterial infection of bladder.

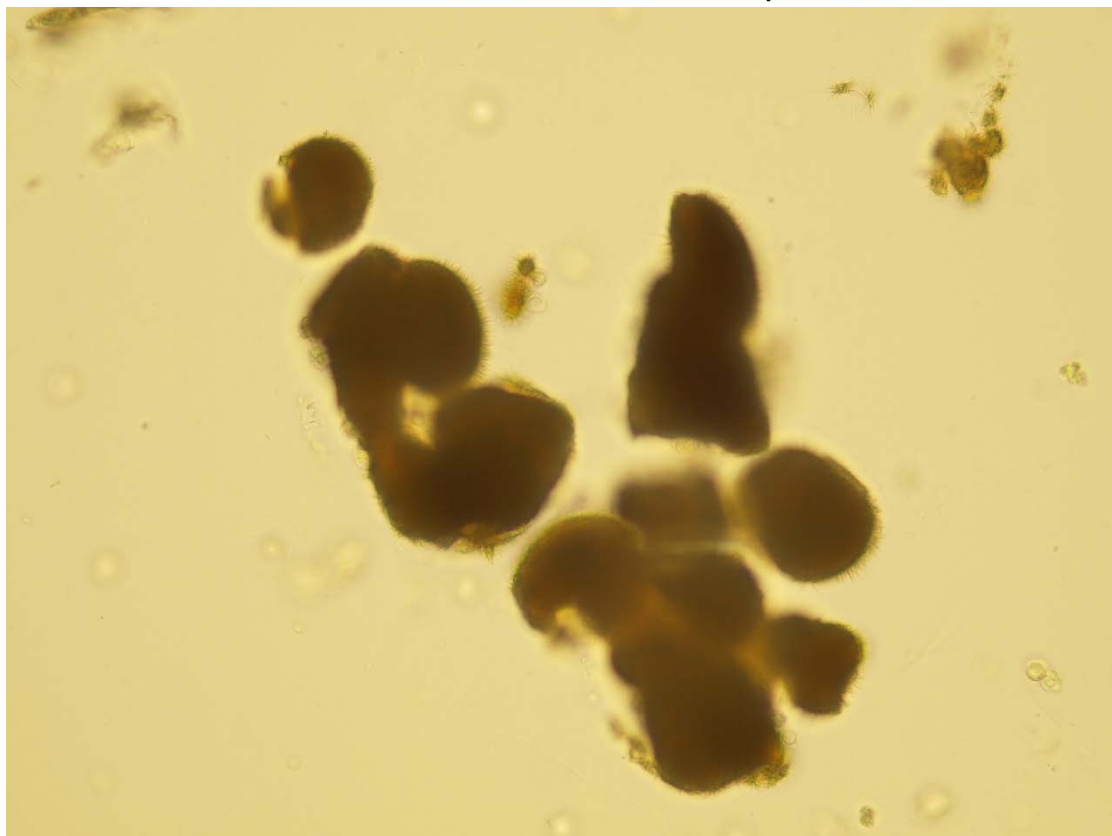
# Ammonium Urates



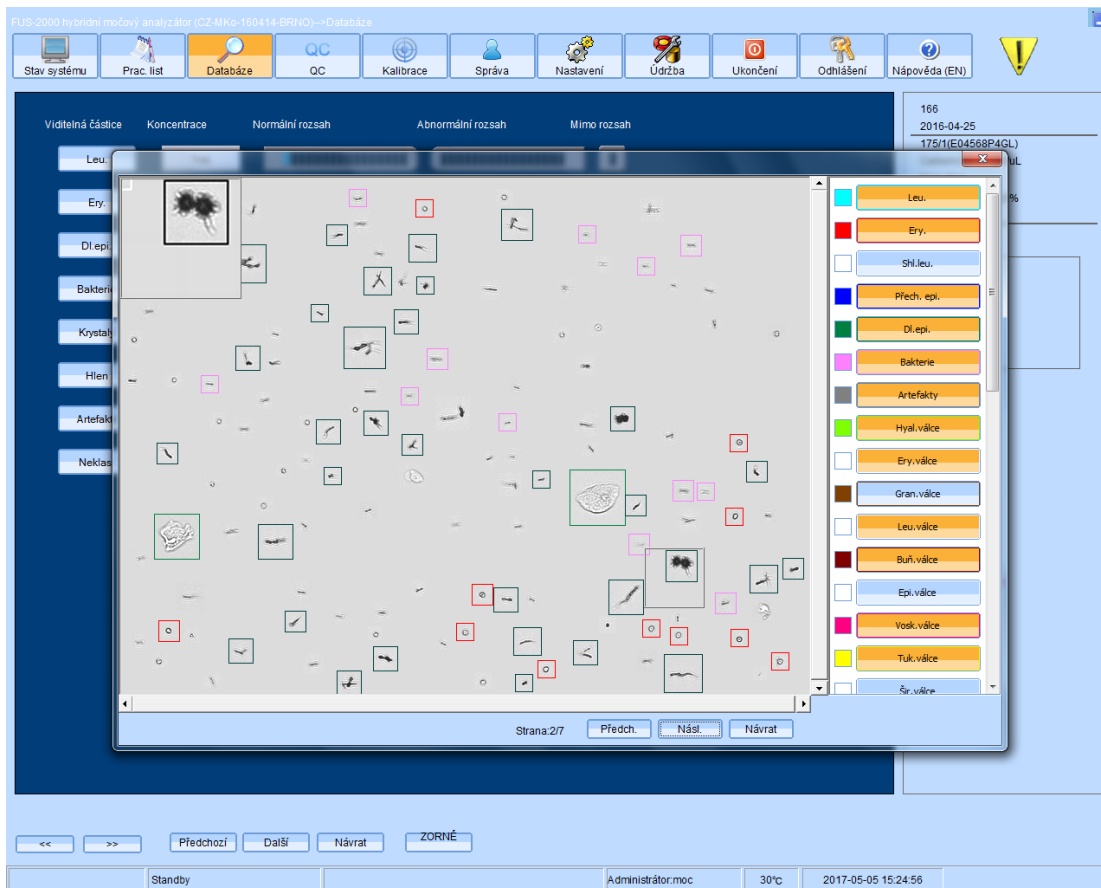
Ammonium urates - FUS-2000 isolated picture



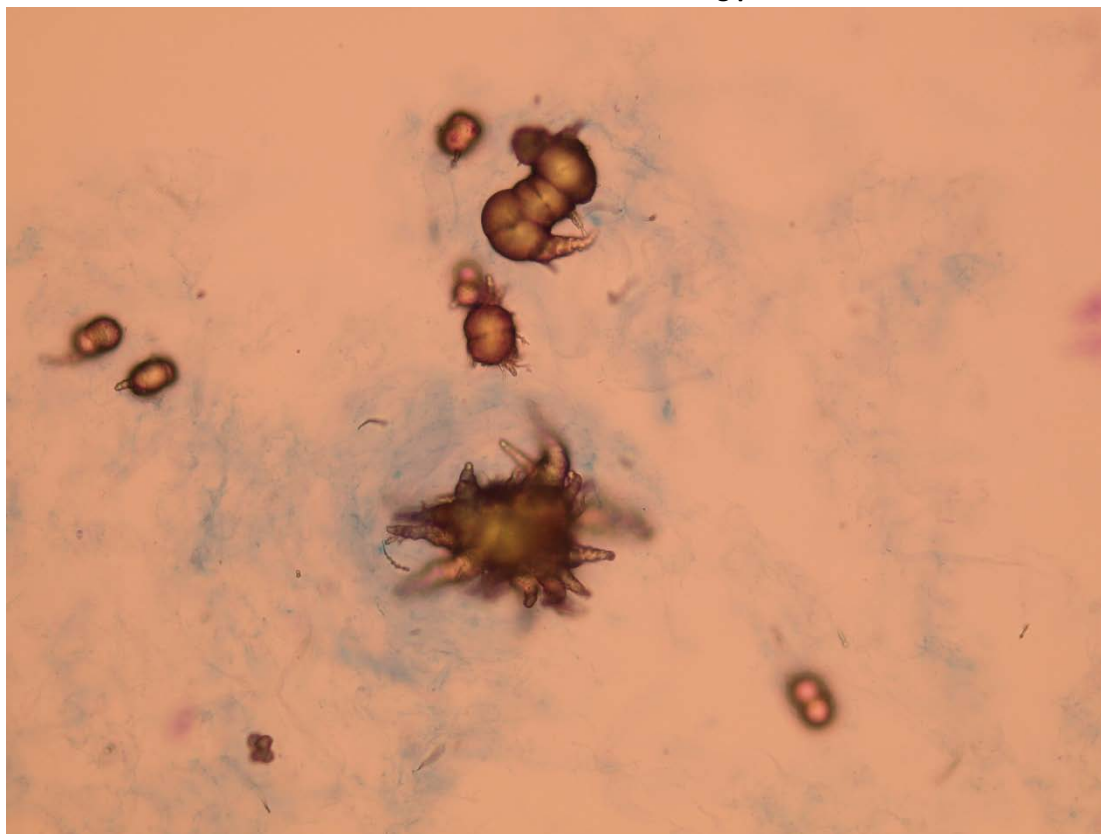
**Ammonium urates - FUS-2000 isolated picture**



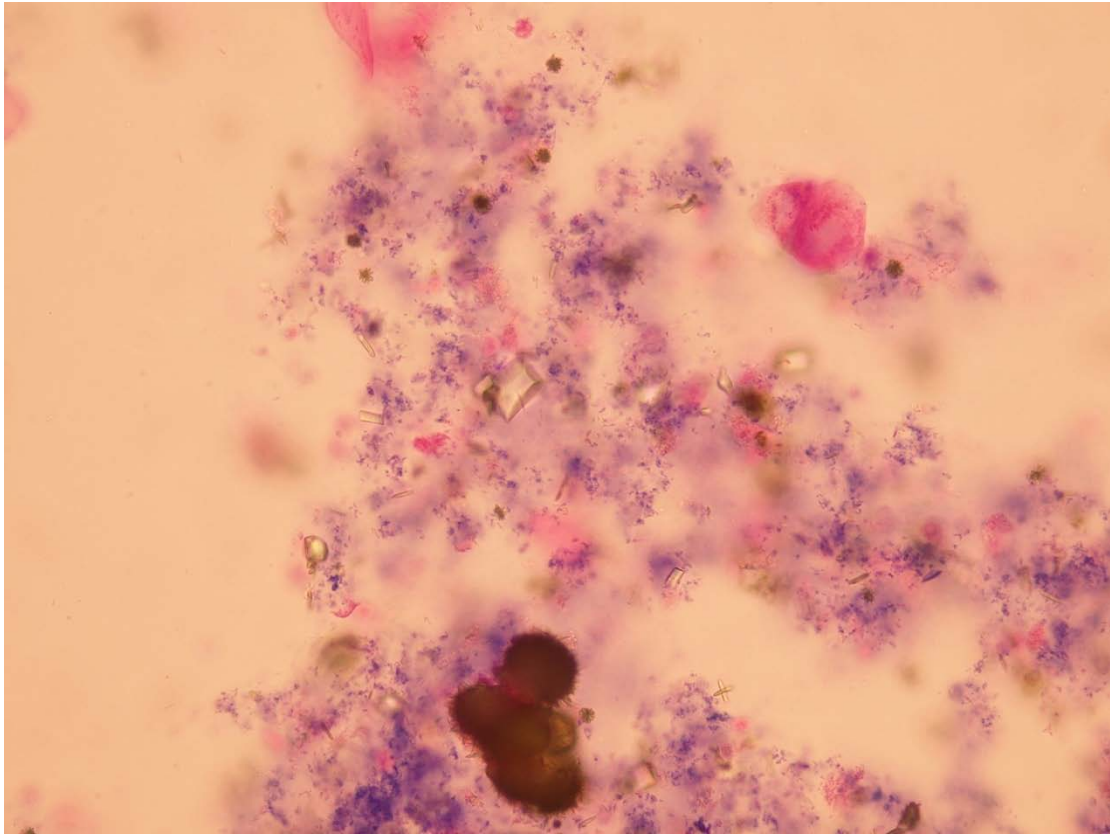
**Ammonium urates - Microscopic picture of native sediment**



**Ammonium urates - FUS-2000 big picture**



**Ammonium urates - Microscopic picture of stained sediment**



**Ammonium urates - Microscopic picture of stained sediment**

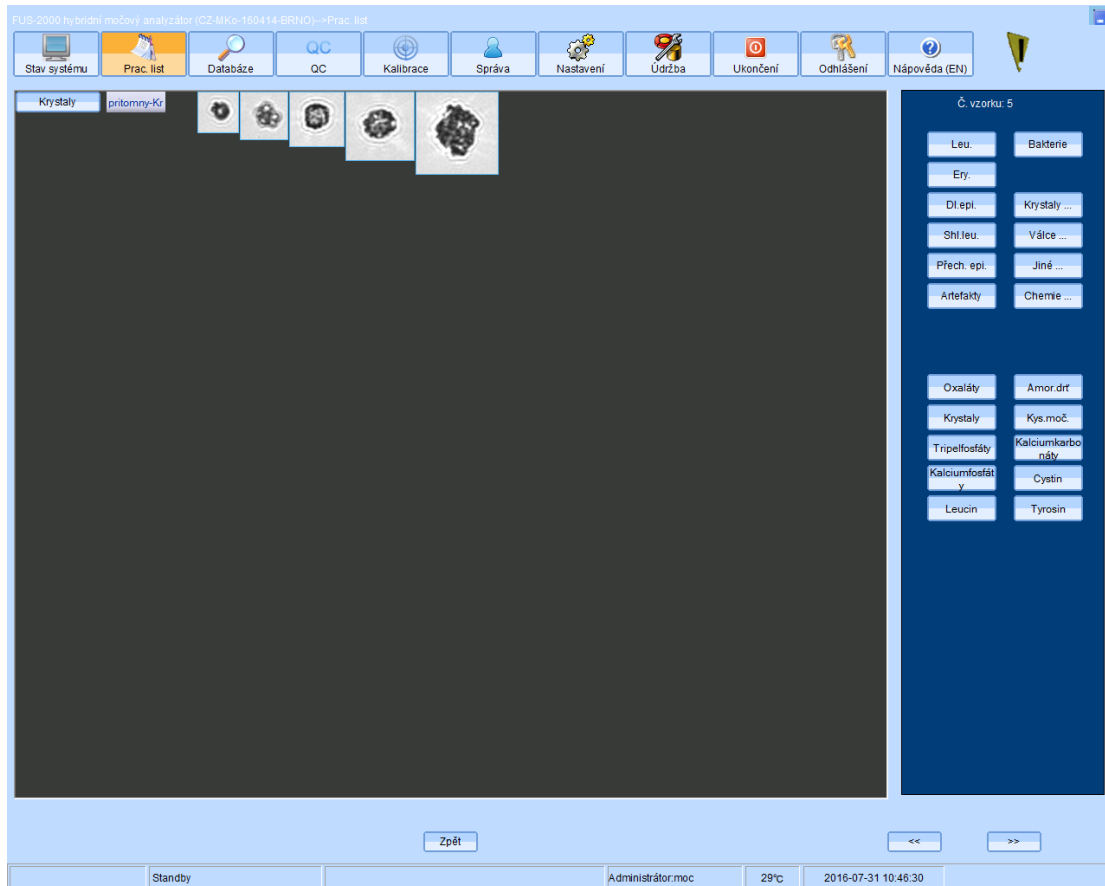
## B. Features of abnormal crystals

Abnormal crystals of metabolic origin in the urine are related to various diseases abnormal in vivo metabolism..Pathological crystals should be promptly reported.

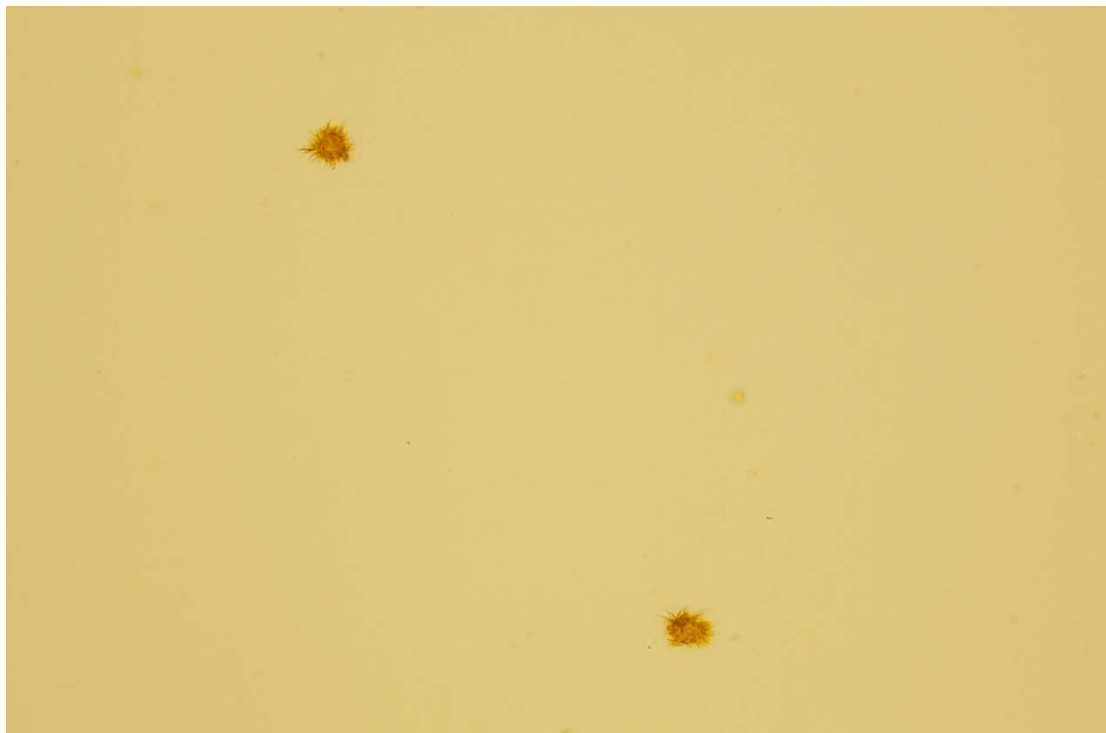
1. Bilirubin is the product of hemoglobin metabolism, therefore presence in can be considered as pathological factors. These crystals are in shape of a bunch of needles or small blocks, sometimes attached to the surface of WBCs and epithelial cells orphagocytosed by WBCs. They are in yellow red, sometimes in non-crystal pigment granules due to oxidation. (Identification method: after adding nitric acid, the crystals are oxidized to green biliverdin to appear green. The crystals are soluble in sodium hydroxide or chloroform.) Bilirubin crystals are seen in patients with various kinds of jaundice, such as jaundice liver atrophy, hemolytic jaundice, liver cancer, cirrhosis and organic phosphorus poisoning and so on.
2. Cystine is decomposition product of protein. The form is colorless hexagonal flake with clear edge and strong refraction. (Differential method: cystine crystals are not soluble in acetic acid but soluble in hydrochloric acid; can quickly dissolve in ammonia but reappear by adding acetic acid.) Large amount is the signs of kidney or bladder stones. Although the primary cause of this finding is hereditary cystinuria, in rare cases cystynuria may occur in patients treated for syphilis, rheumatism and serious liver diseases.
3. Leucine is protein decomposition product, in light yellow with shape of discolored little ball or oil droplet. There are concentric circles or dense radiating stripes. The refraction is strong. (Identification method: leucine crystals are not soluble in hydrochloric acid, but soluble in acetic acid and potassium hydroxide. )
4. Tyrosine is protein decomposition product. They are yellowish needles crystals bunched into groups or feathery. (Identification method: tyrosine crystals are not soluble in acetic acid but soluble in hydrochloric acid and potassium hydroxide. )The presence in urine signifies a bad prognosis, seen in severe liver disease, such as acute liver necrosis; Also found in tissue necrotic diseases, acute phosphorus poisoning, diabetic coma, leukemia, typhoid fever etc; and also metabolic disorders. Tyrosine crystals are often found in the urine of patients with rare high tyrosine aciduria and hereditary tyrosine metabolic syndrome. Leucine and tyrosine crystals usually present together.
5. Cholesterol crystals are featured to be flaky like overlapping displayed broken glass, mostly in rectangular, square and irregular shape lack of corners, colorless and transparent. Due to their lipid properties, these crystals have low density, often floating on the surface of urine. (Identification method: soluble in chloroform and ether. Due to often floating on the surface to form a film, there is a high positive rate by taking surface film for observation.) They can be seen in urine of patients with cystitis, nephropylitis, lymphadenopathy, chylous urine, severe urinary tract infections and nephrotic syndrome, and occasionally found in urine of patients with pyuria.



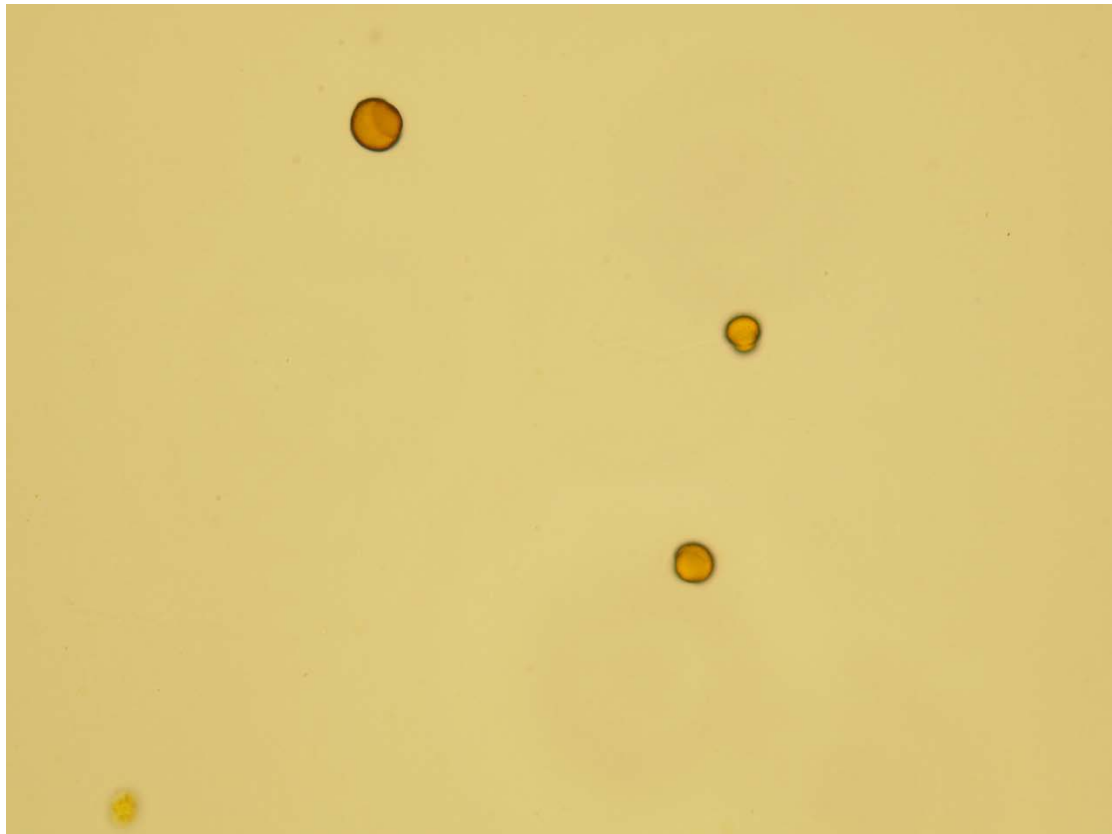
## Bilirubin Crystals



**Bilirubin crystals- FUS-2000 isolated picture**



**Bilirubin crystals- - Microscopic picture of native sediment**

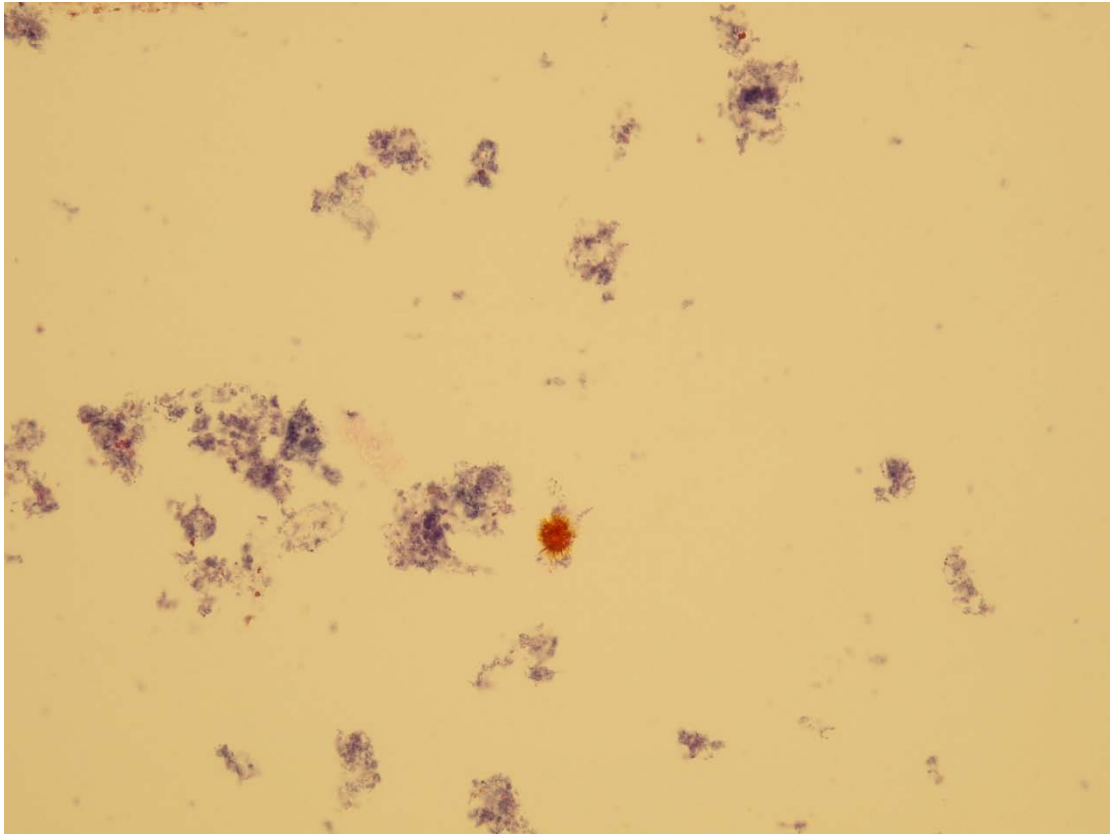


**Bilirubin crystals- - Microscopic picture of native sediment**

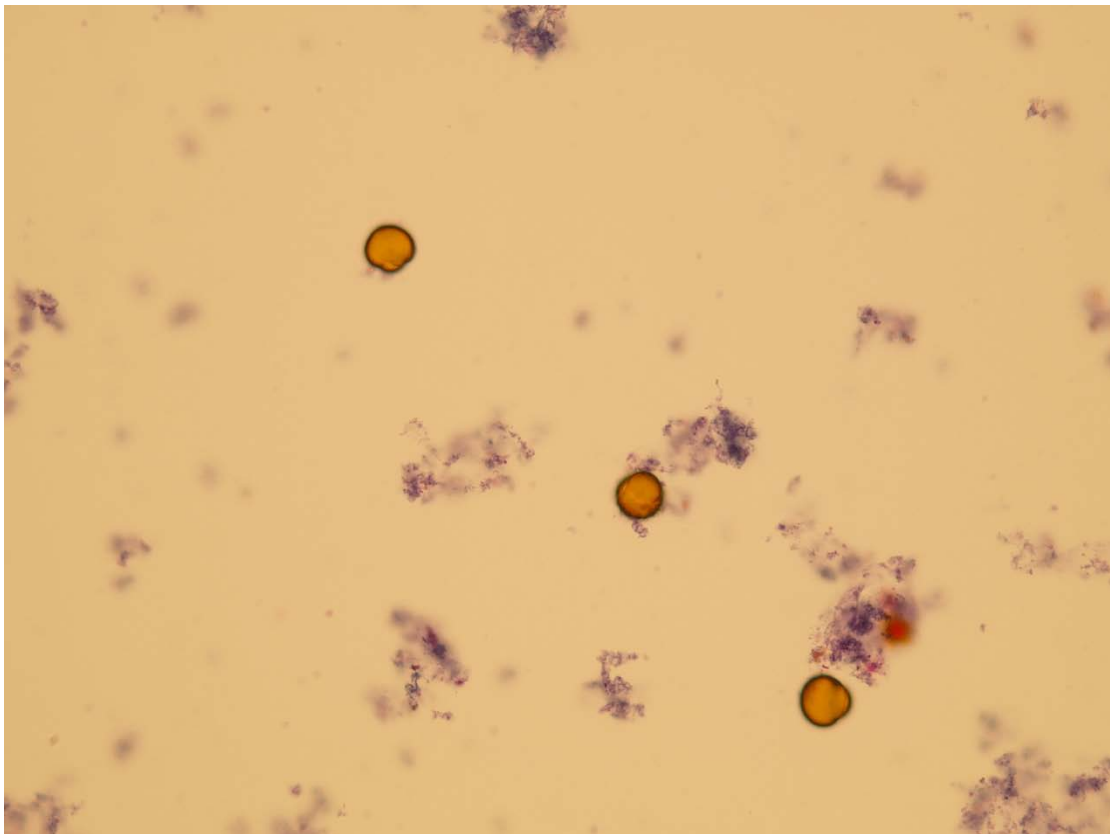
Chemie:

UGG	+1
BL	+3
KEE	++
BLD	-
PRO	-
NIT	+1
LEU	++
GLU	+1
pH	5.5
SG	1.022
COLOR	Dark Orange
TURB	Clear

**Bilirubin crystals- FUS-2000 big picture**

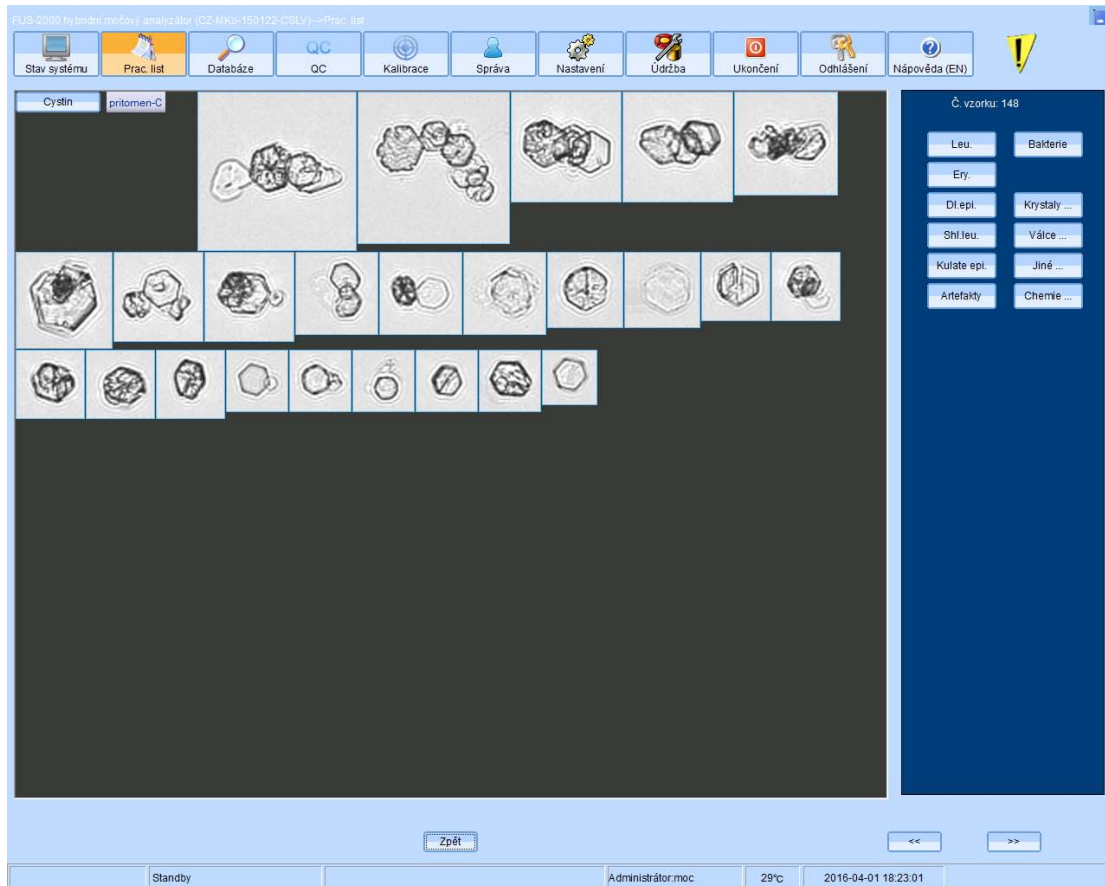


**Bilirubin crystals- - Microscopic picture of stained sediment**

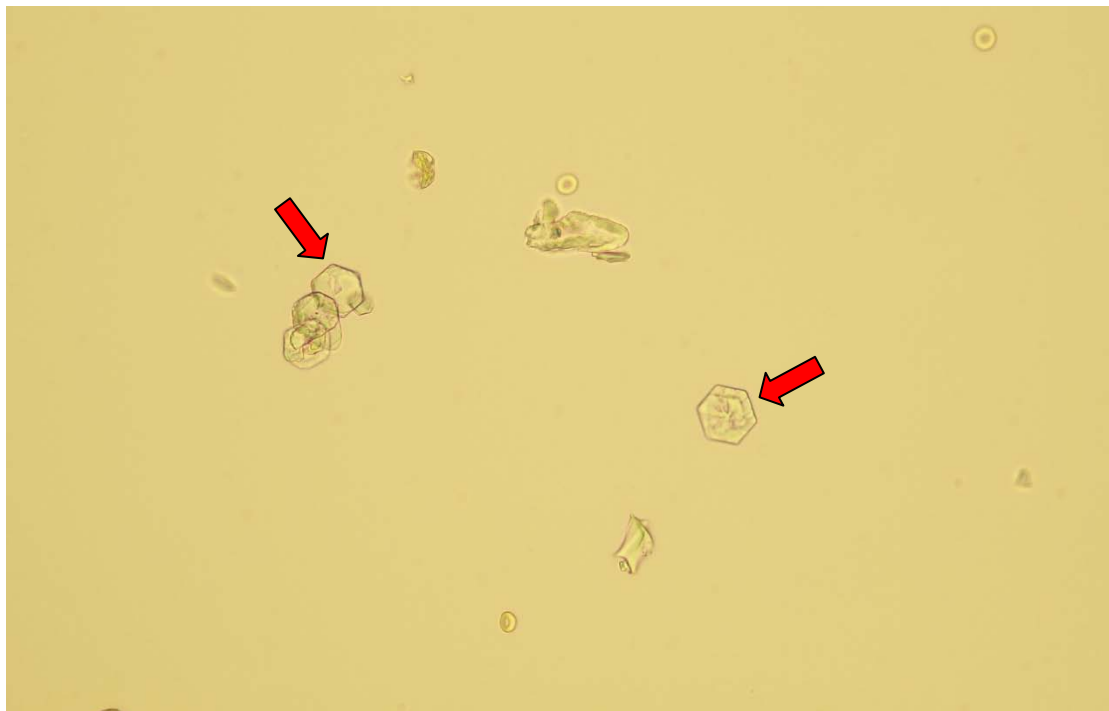

**Bilirubin crystals- - Microscopic picture of stained sediment**


## Cystine Crystals



Cystine crystals- FUS-2000 isolated picture



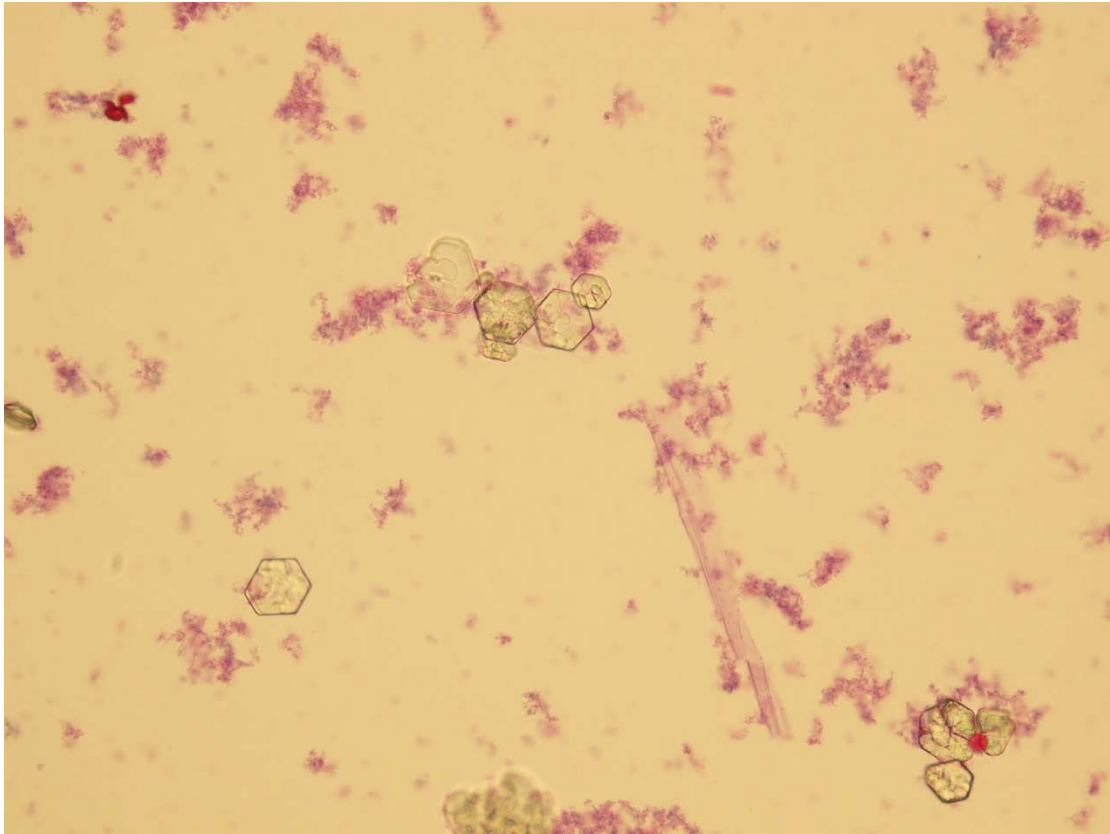
Cystine crystals- - Microscopic picture of native sediment



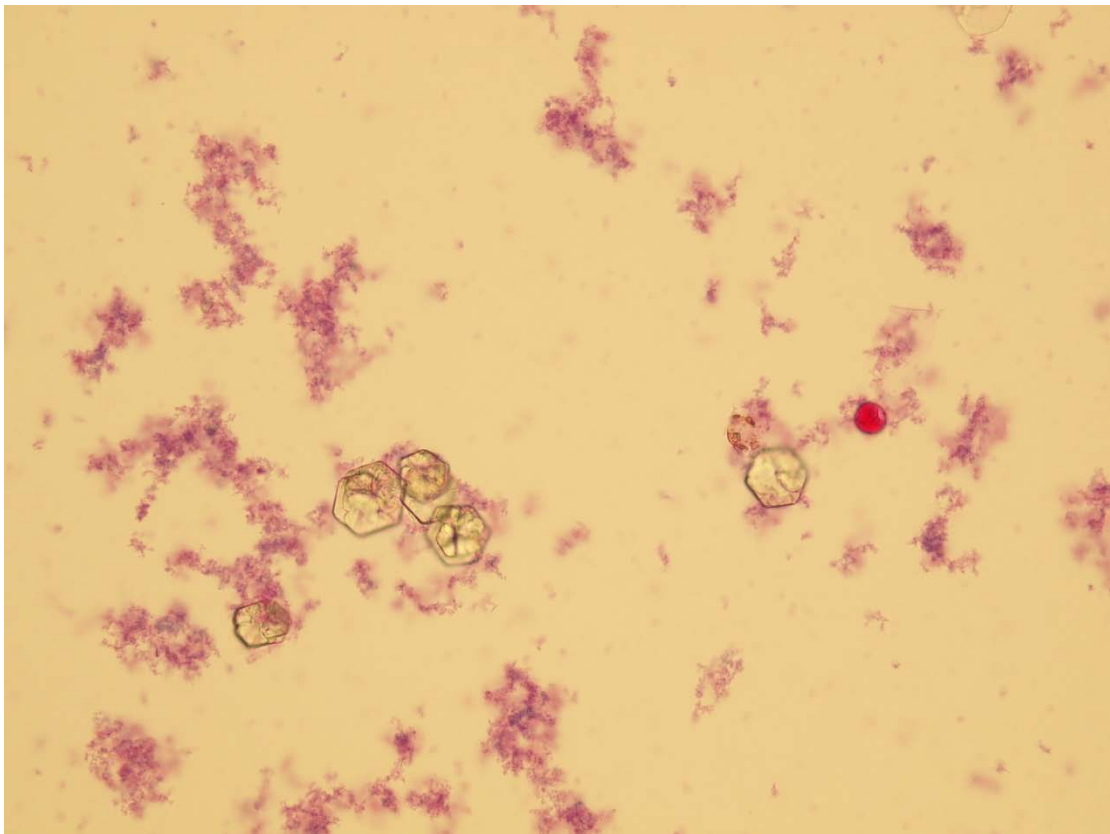
Cystine crystals- - Microscopic picture of native sediment

The screenshot shows the FUS-2000 software interface. At the top, there is a menu bar with icons for 'Stav systému', 'Prac. list', 'Databáze', 'QC', 'Kalibrace', 'Správa', 'Nastavení', 'Údržba', 'Ukončení', 'Odhlášení', and 'Nápověda (EN)'. Below the menu, there are tabs for 'Viditelná částice', 'Koncentrace', 'Normální rozsah', 'Abnormální rozsah', and 'Mimo rozsah'. The main window displays a large microscopic image of cystine crystals, with a smaller inset image in the top-left corner. A legend on the right side of the window lists various particle types with corresponding colored boxes: Leu., Ery., Sh.leu., Přech. epi., Di.epi., Bakterie, Artefakty, Hyal.válce, Ery.válce, Gran.válce, Leu.válce, Buř.válce, Epi.válce, Vosk.válce, Tuk.válce, and Šr.válce. The bottom of the interface shows navigation buttons like '&lt;&lt;', '&gt;&gt;', 'Předchozí', 'Další', 'Návrat', and 'ZORNĚ'. The status bar at the very bottom indicates 'Standby', 'Administrátor:moc', '29°C', and '2017-03-29 20:48:56'.

Cystine crystals- FUS-2000 big picture

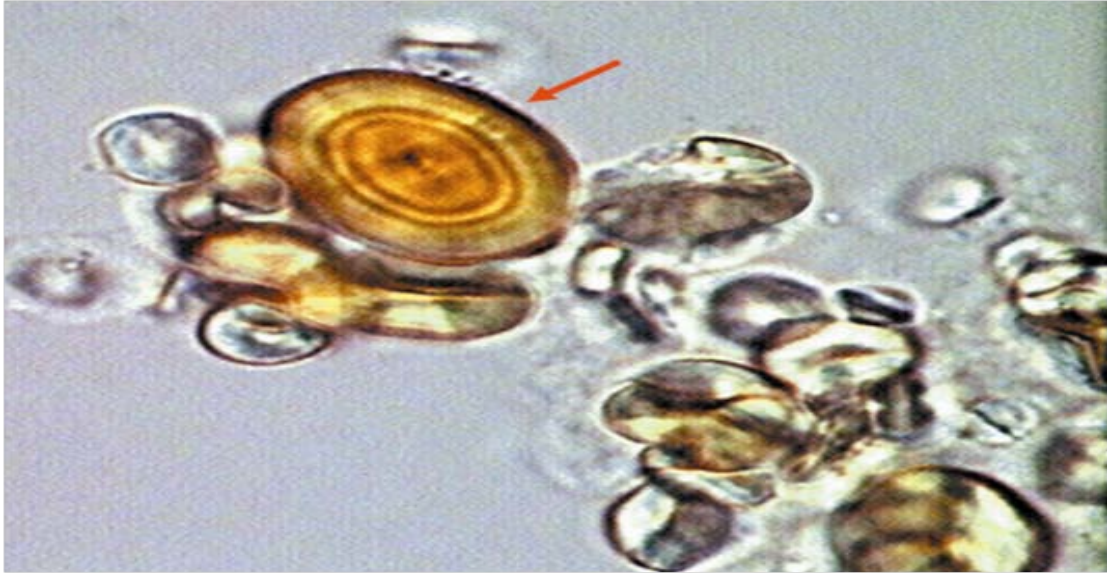

**Cystine crystals- - Microscopic picture of stained sediment**



**Cystine crystals- - Microscopic picture of stained sediment**

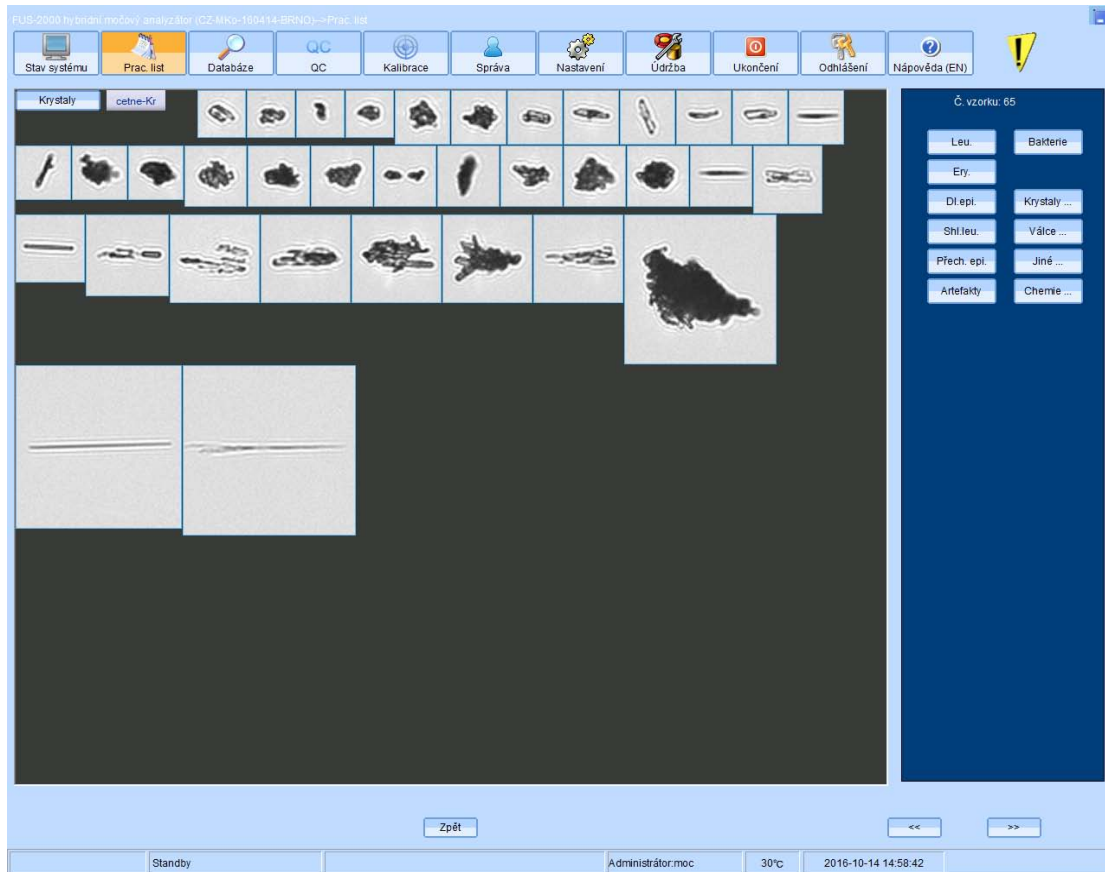
## Leucine Crystals



Leucine crystals- Internet.



## Tyrosine Crystals

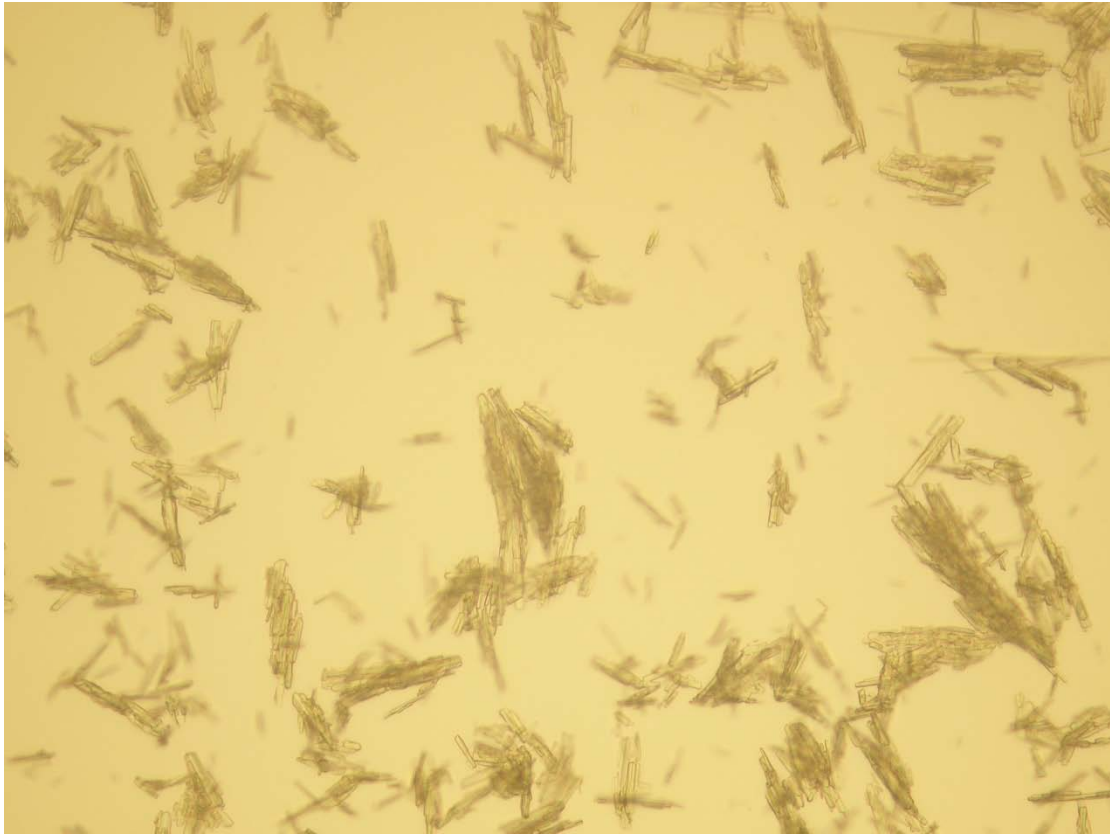


**Tyrosine crystals- FUS-2000 isolated picture**



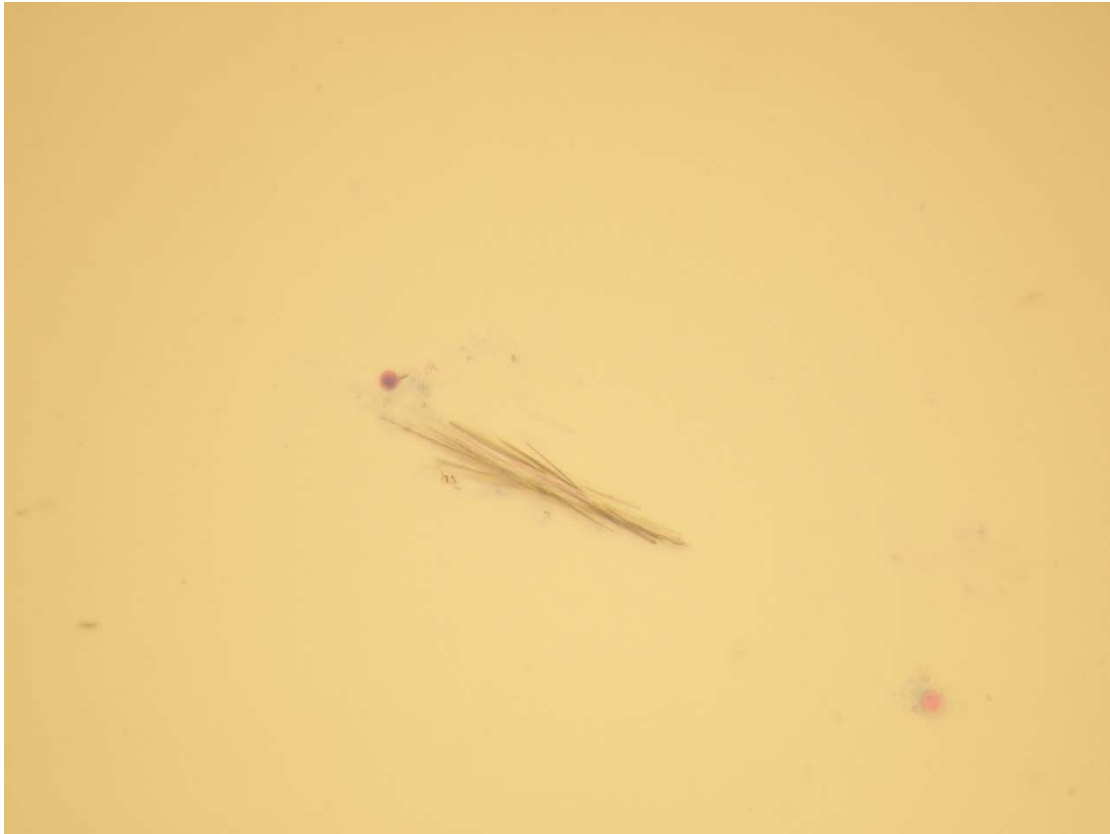**Tyrosine crystals- - Microscopic picture of native sediment**





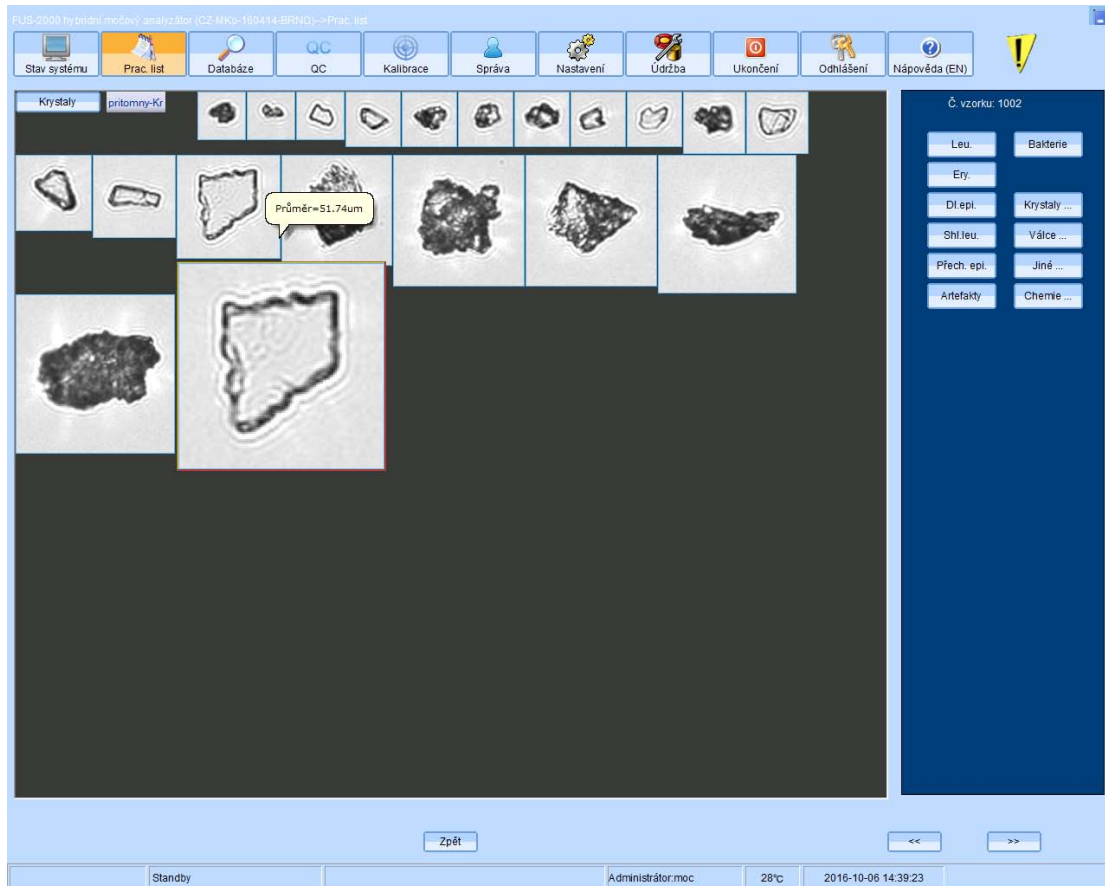
**Tyrosine crystals- - Microscopic picture of native sediment**

**Tyrosine crystals- FUS-2000 big picture**

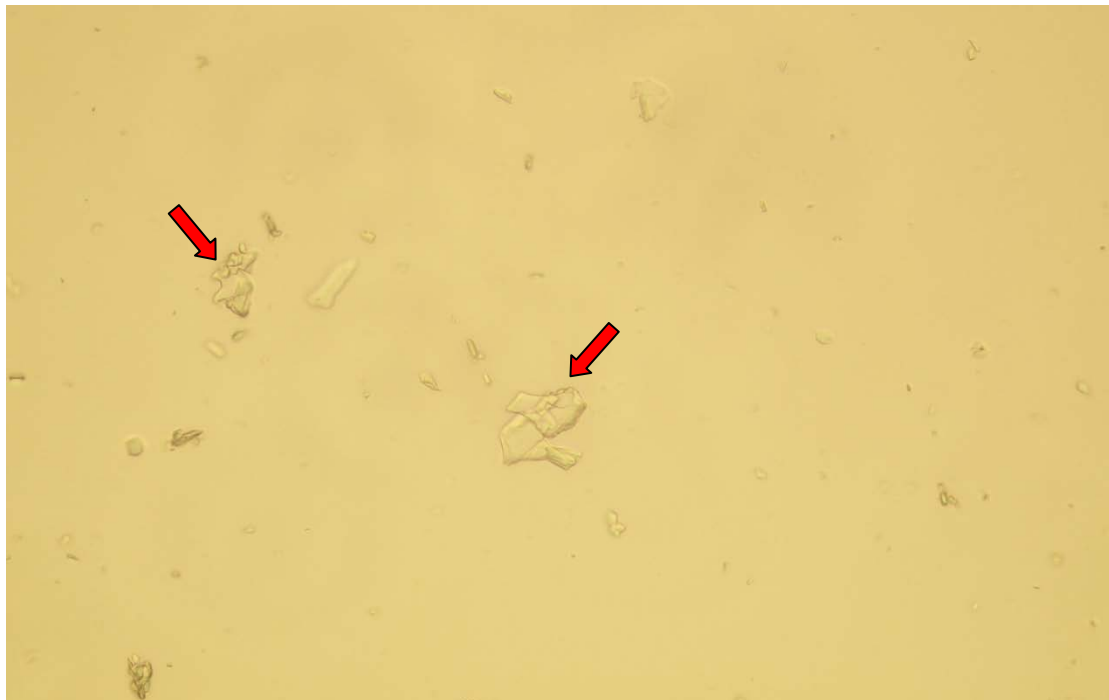


**Tyrosine crystals- - Microscopic picture of stained sediment**

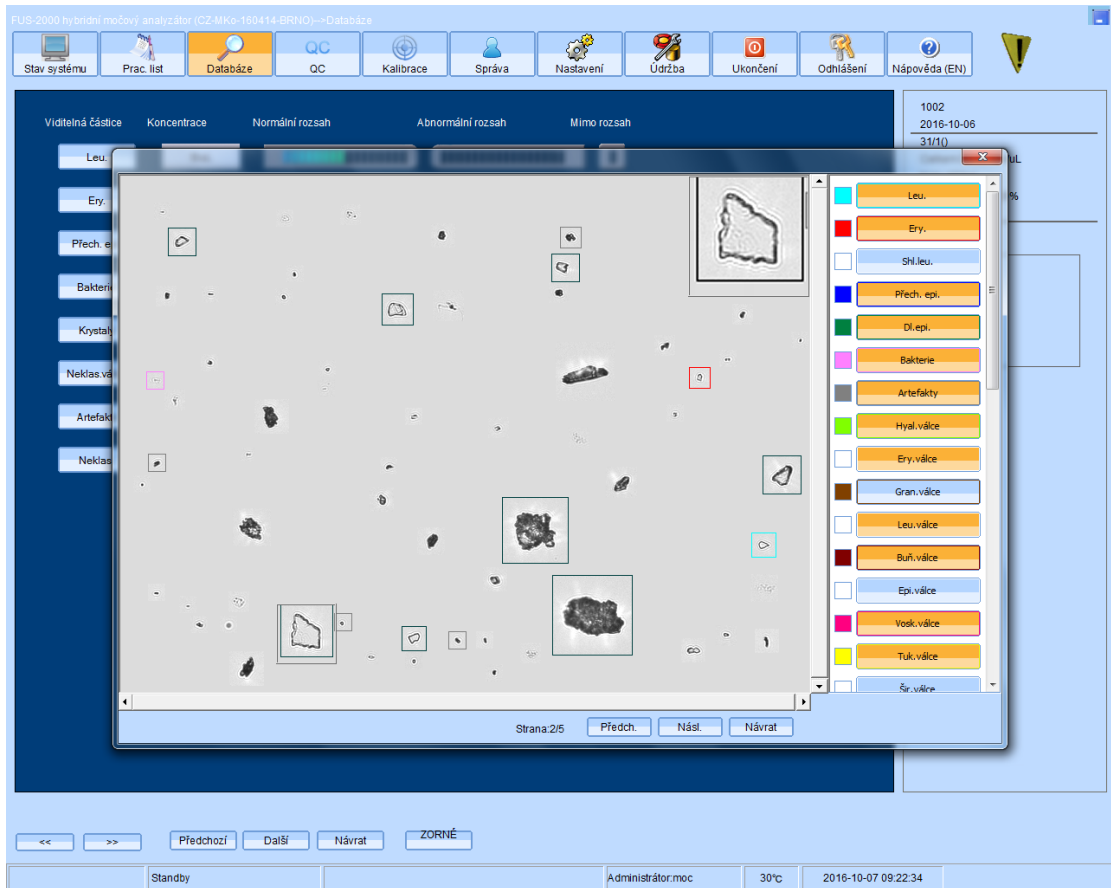
## Cholesterol crystals



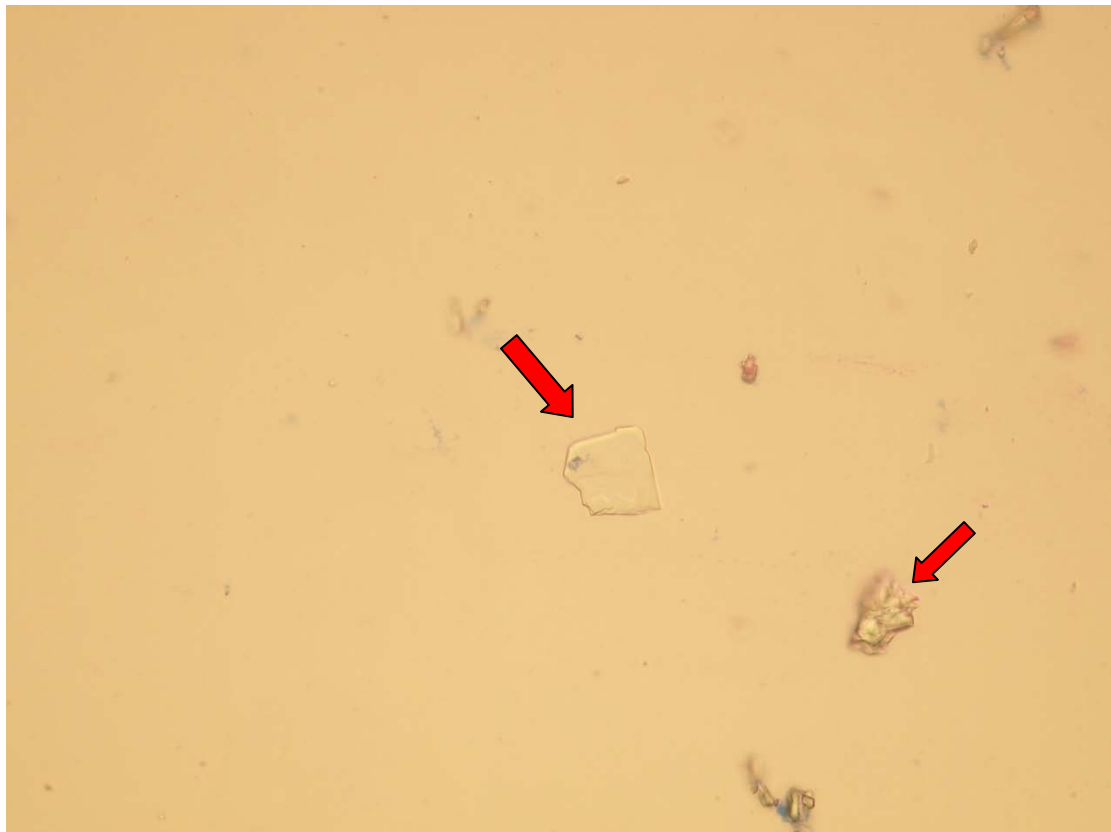
Cholesterol crystals- FUS-2000 isolated picture



Cholesterol crystals- - Microscopic picture of native sediment



**Cholesterol crystals- FUS-2000 big picture**



**Cholesterol crystals- - Microscopic picture of stained sediment**

### C. Features of drug crystals

Besides physiological crystal and pathological crystals, there are also more and more drug crystals found in urine due to a variety of therapeutic drugs used in patients and the development of more and more chemotherapy drugs. There are several common categories drug crystals, radiology contrast agents, sulfa drug and antipyretic and analgesic drugs. Nowadays, some new chemical drugs would lead to the occurrence of crystals.

1. Radiology contrast agents: the use of radiology contrast agents, such as iodine contrast agents, urinary tract contrast agents and so on, can cause the urine to have fasciculate, spherical, polymorphous crystals and the urine SG would raise significantly (greater than 1.050). These crystals are soluble in a solution of sodium hydroxide, but insoluble in organic solvents such as ether and chloroform. They are harmless to human bodies and can be automatically cleared after urinating several times.
2. Sulfa drugs crystals (sulfonamides): patients taking sulfa drugs require frequent urine sediments testing. It is easy to precipitate crystals when drinking little water after taking medicines or when the urine is more acidic. A large amount of sulfa drugs crystals in urine indicates that there are precipitation formed at the ureter and renal pelvis to increase the risk of blocked urinary tract, which can lead to anuria or accompanied by hematuria, kidney lesions or anuresis. As sulfa drugs crystals detected in urine are related to overdose; it should be reported without delay.
3. Antipyretic and analgesic drugs crystals: if crystals of aspirin or sulfosalicylic acid drugs crystals appear, it signifies the drugs overdose.

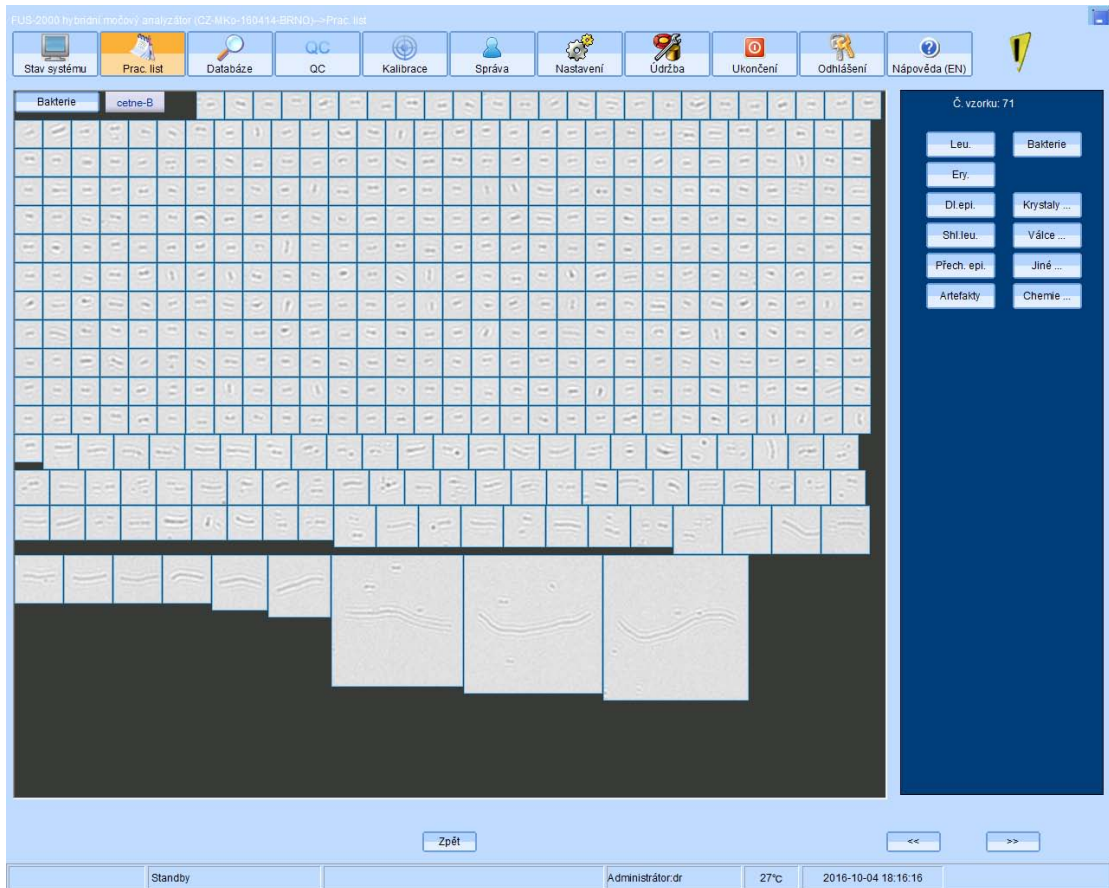
## Bacteria

Bacteria found in urine include Gram-negative bacillus (rods) and Gram-positive cocci, most commonly *Escherichia coli*, *staphylococcus*, *streptococcus*, *proteus*, etc. It cannot be confirmed simply according to the morphological characteristics, so the final result and its clinical significance must be based on the bacterial culture results.

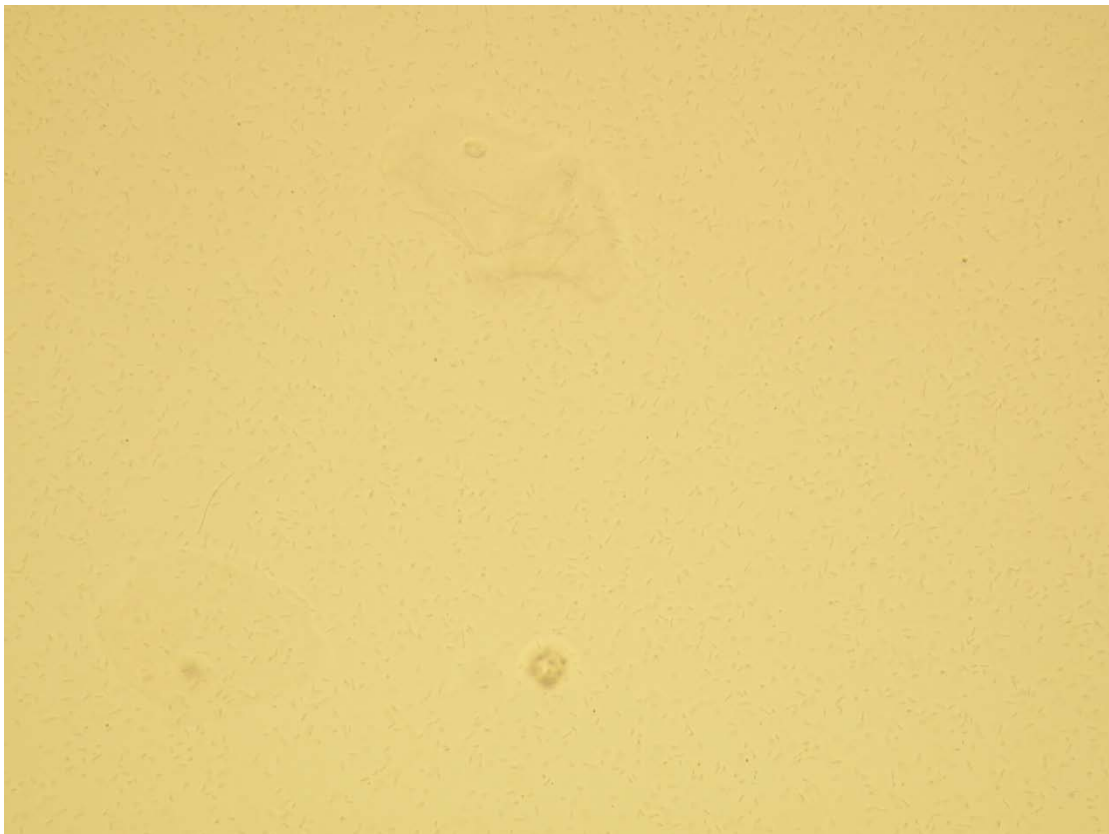
From the formation to the storage in the bladder of healthy people urine, there is no bacterial growth in the process. Detection of small amounts of bacteria is likely that specimens were polluted during collection. There is generally no clinical significance.

If there is a large number of bacteria, and meanwhile accompanied with pus cells and epithelial cells, it suggests urinary tract infection.

Gram negative bacteria colony counting  $\geq 10^5$ /ml suggests urinary system infections. Gram-positive cocci counting  $\geq 10^4$ /ml has diagnostic value. Cystitis and pyelonephritis have mainly gram negative bacilli. In the urine of patients with sexually transmitted diseases can find *Neisseria gonorrhoeae*. In the urine of patients with urinary system tuberculosis can be find acid-fast bacilli.



**Bacteria- FUS-2000 isolated picture**



**Bacteria- - Microscopic picture of native sediment**



FUS-2000 hybridní močavý analyzátor (CZ-MKO-189414-BRNO)->DataBáze

[Stav systému](#)
[Prac. list](#)
[DataBáze](#)
[QC](#)
[Kalibrace](#)
[Správa](#)
[Nastavení](#)
[Údržba](#)
[Ukončení](#)
[Odhlášení](#)
[Nápvěda \(EN\)](#)

Viditelná částice    Koncentrace    Normální rozsah    Abnormální rozsah    Mimo rozsah

71  
 2016-10-04  
 203/9(8406504964)

Leu.  
 Ery.  
 Přech. e.  
 Di.epi.  
 Bakterie  
 Kvasinky  
 Artefakt  
 Neklas.

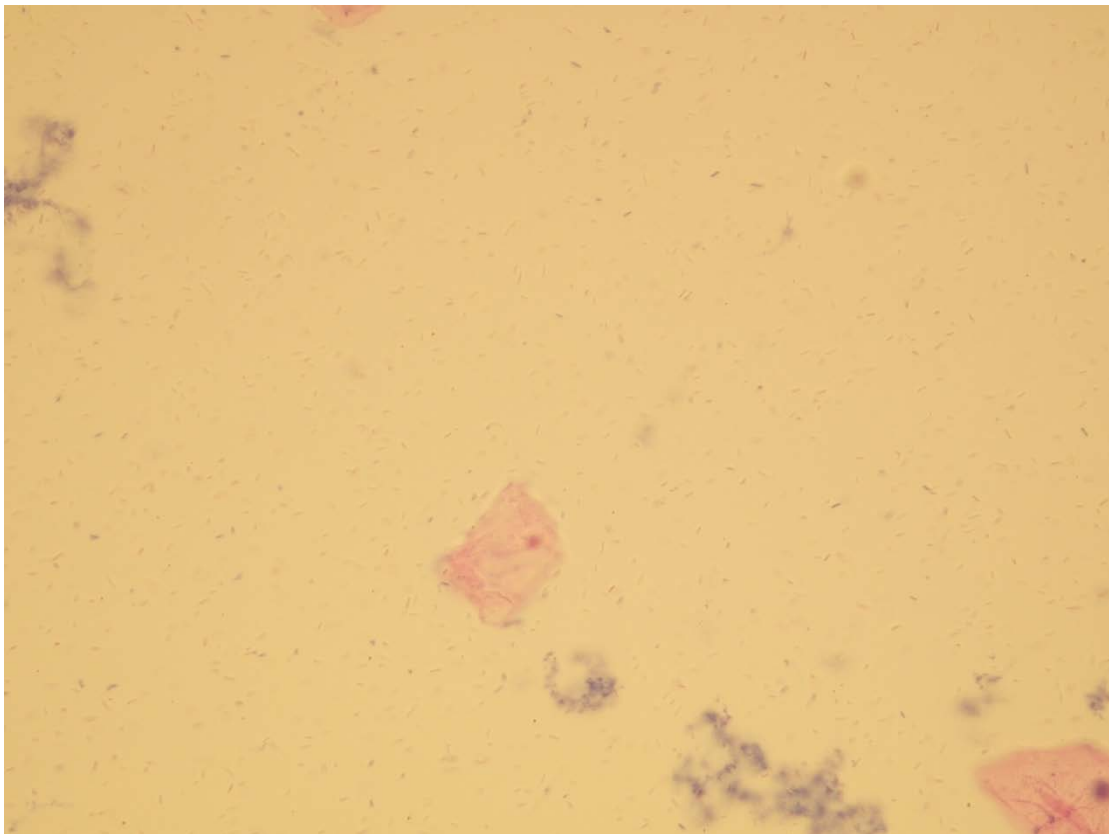
Leu.  
 Ery.  
 SH.Leu.  
 Přech. ep.  
 Di.epi.  
 Bakterie  
 Artefakty  
 Hyal.válce  
 Ery.válce  
 Gran.válce  
 Leu.válce  
 Buň.válce  
 Epi.válce  
 Vosk.válce  
 Tuk.válce  
 Šr.válce

Strana 1/9    Předch.    Násl.    Návrat

<<    >>    Předchozí    Další    Návrat    ZORNĚ

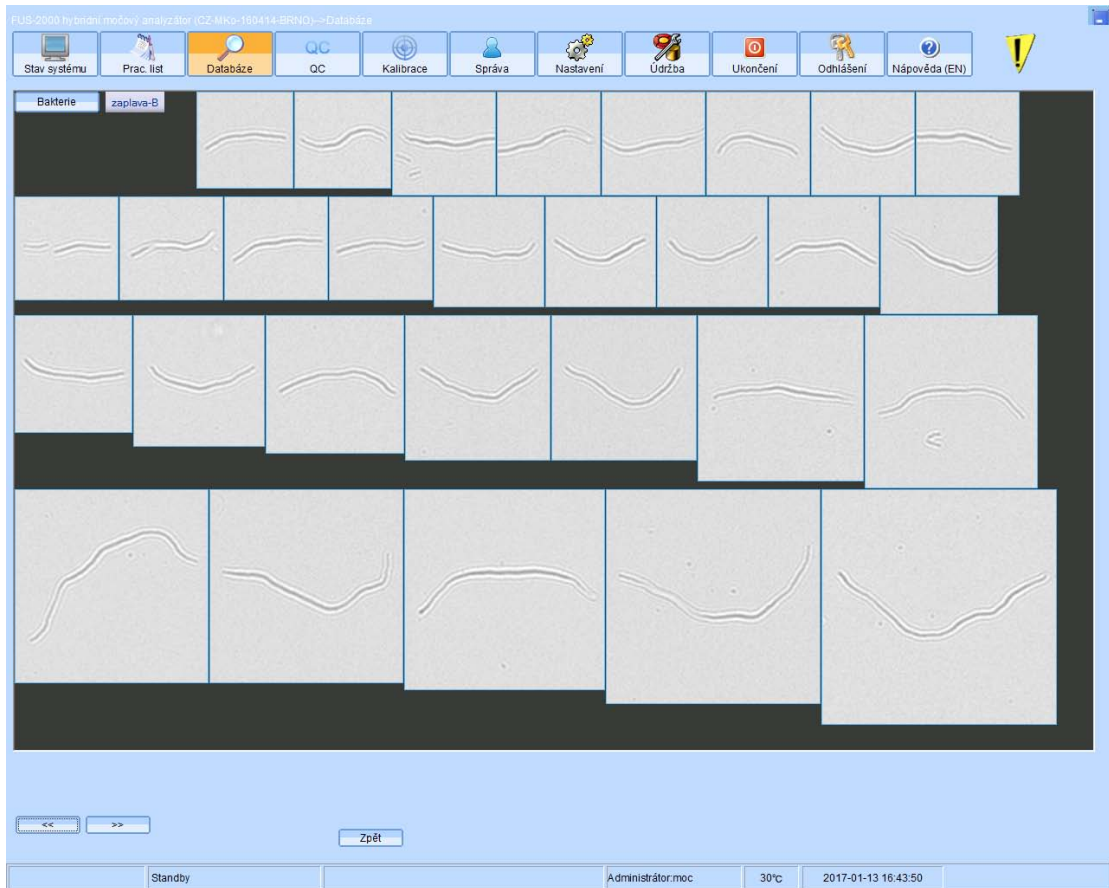
8406515005    Měření vzorku    Analýza vzorku    Administrátor:moc    30°C    2016-10-07 09:16:04

**Bacteria- FUS-2000 big picture**

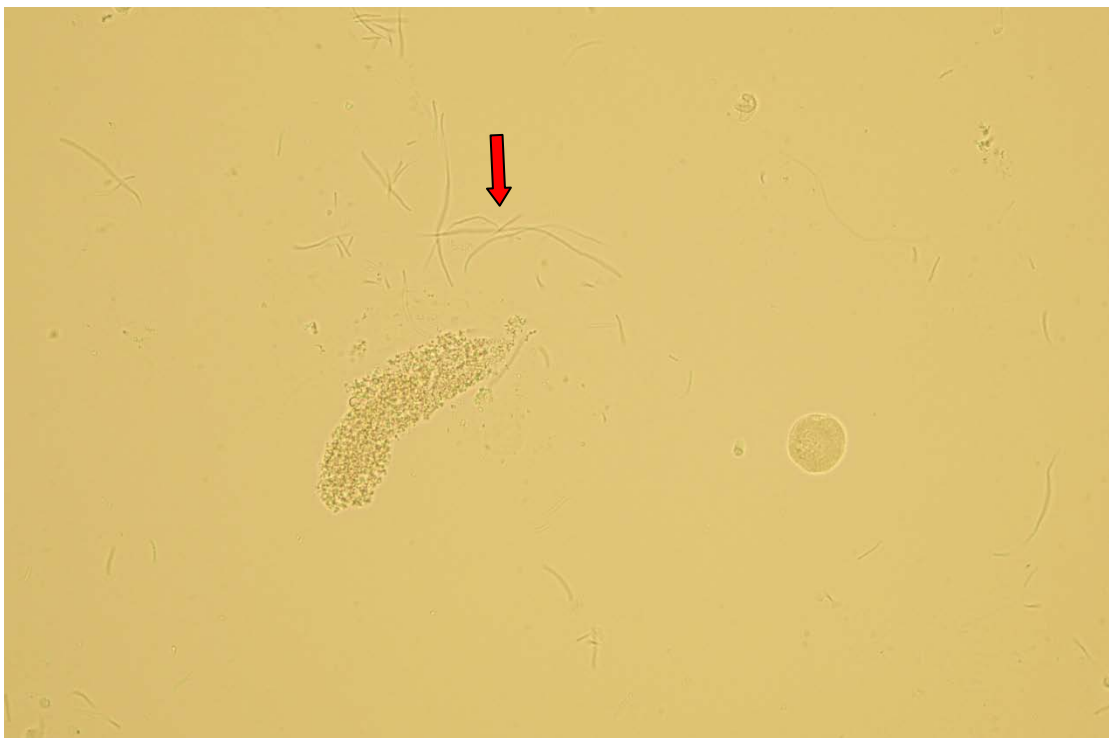

**Bacteria- - Microscopic picture of stained sediment**

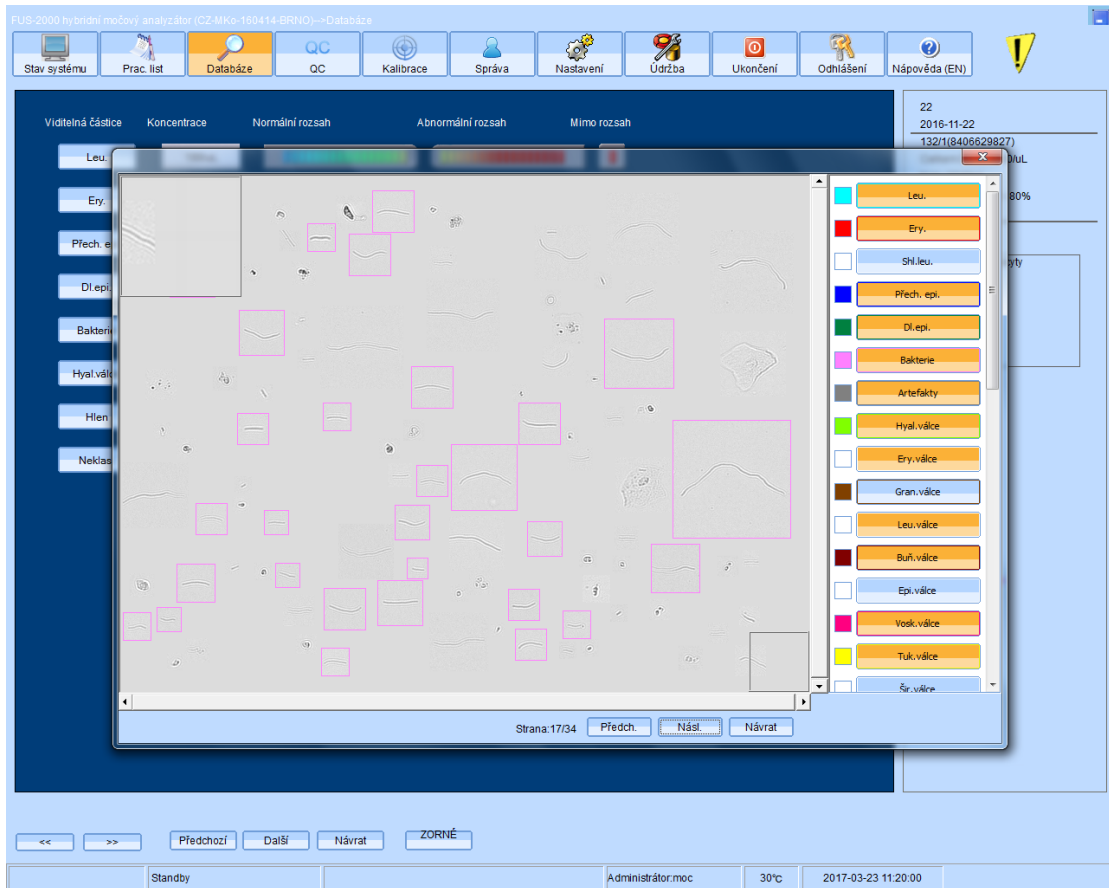
## Long rod bacteria



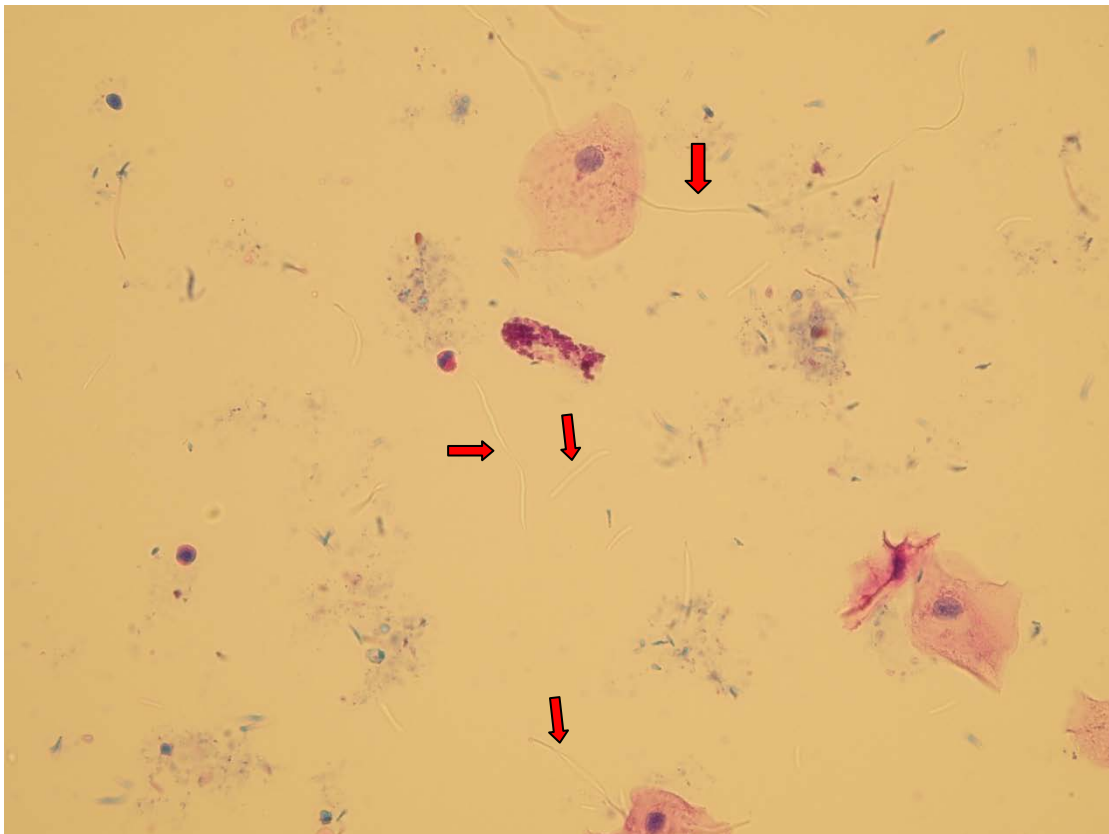
Long rod bacteria- FUS-2000 isolated picture



Long rod bacteria- - Microscopic picture of native sediment



Long rod bacteria- FUS-2000 big picture



Long rod bacteria- - Microscopic picture of stained sediment

## Yeasts

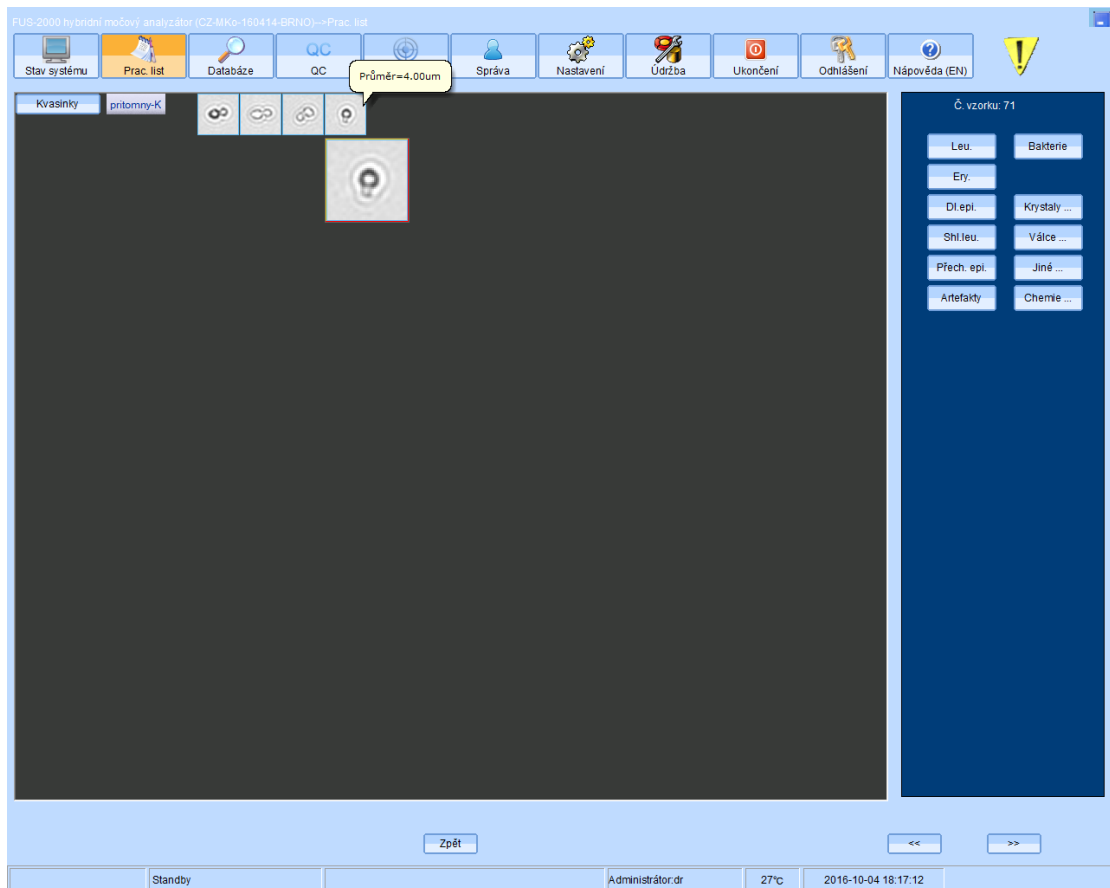
Yeasts are oval, looking like RBCs, with strong refraction. Germs and pseudohyphae can be visible, commonly found in female urine, diabetes patients' urine, or in alkaline urine.

They may occur in urine of immune deficient or immune suppressed patients.


The most common species of yeast in urine is *Candida albicans*.

*Candida albicans* are colorless without staining. They are 2.5-5  $\mu\text{m}$  in size, oval or cylindrical-shaped. Sometimes there are clusters of them caused by blastospore. It is generally pollution from vaginal secretions. Pseudohyphae can be seen in candida. Under oil immersion lens, Gram positive spores or pseudo-mycelium connected with budding cells can be seen after Gram staining.

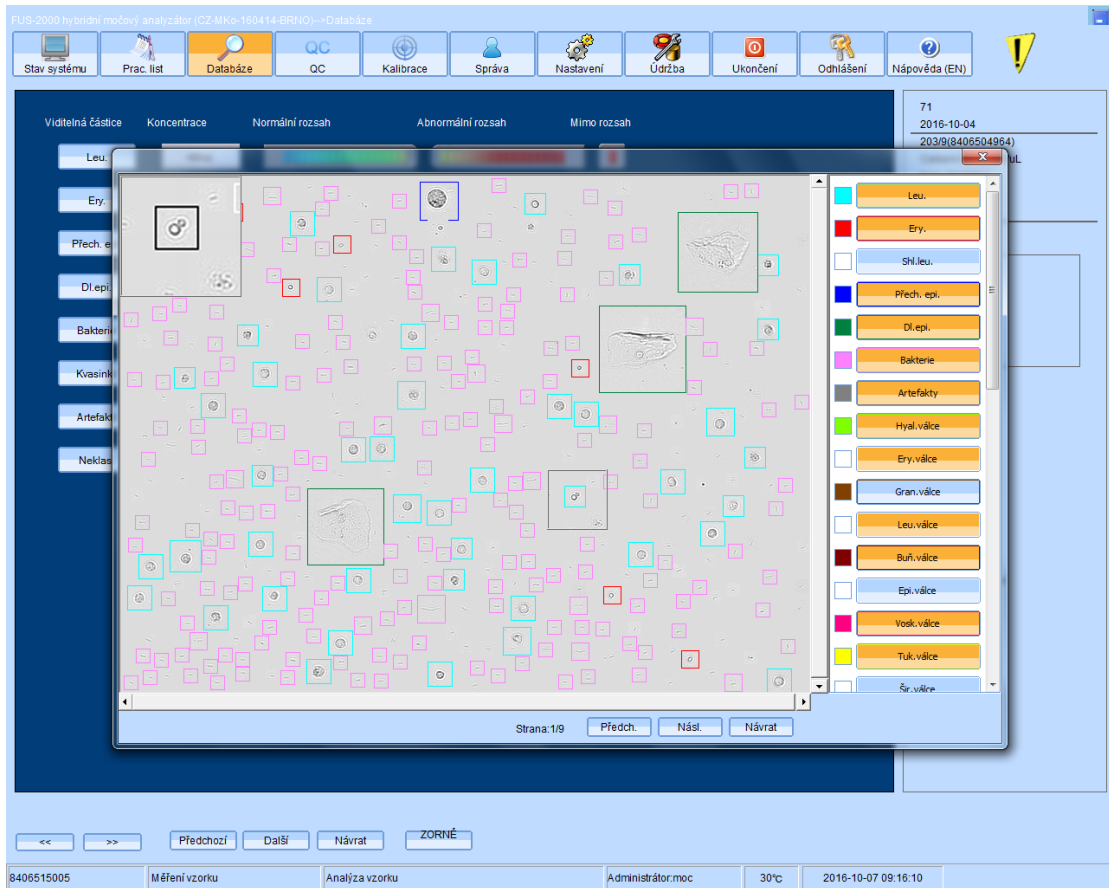
## Yeasts



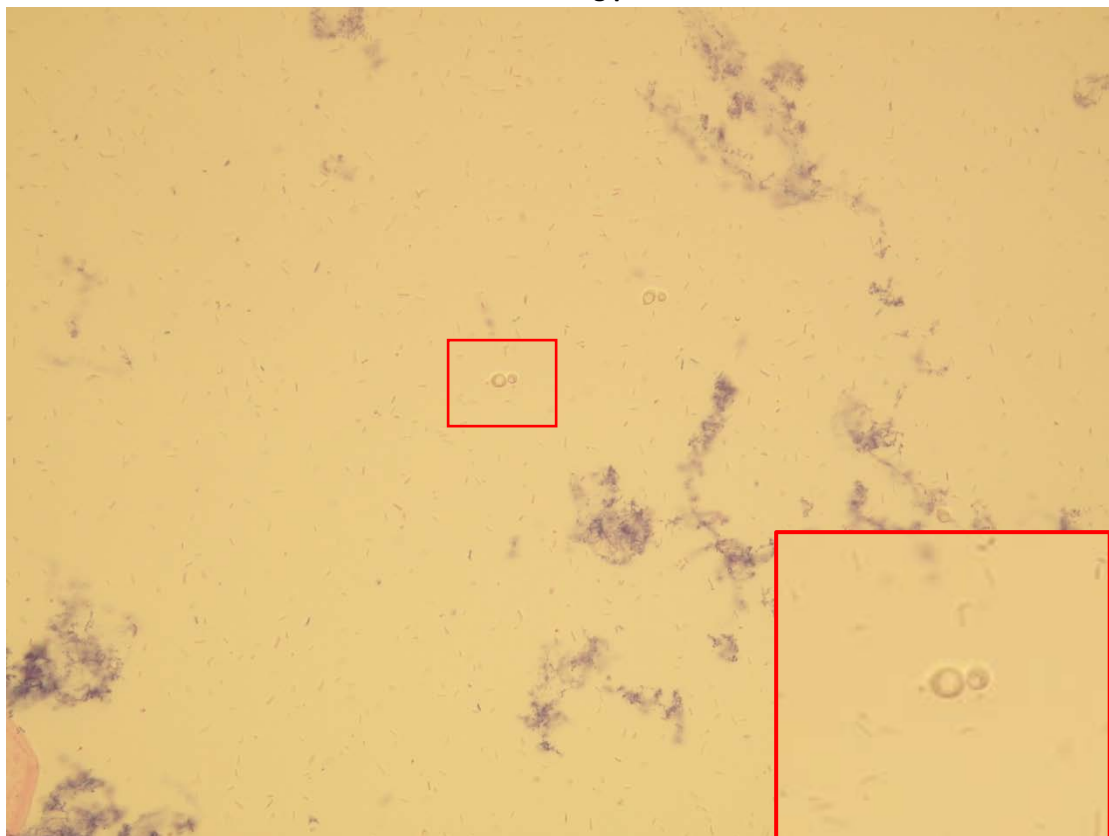
Yeasts- FUS-2000 isolated picture



Yeasts- - Microscopic picture of native sediment

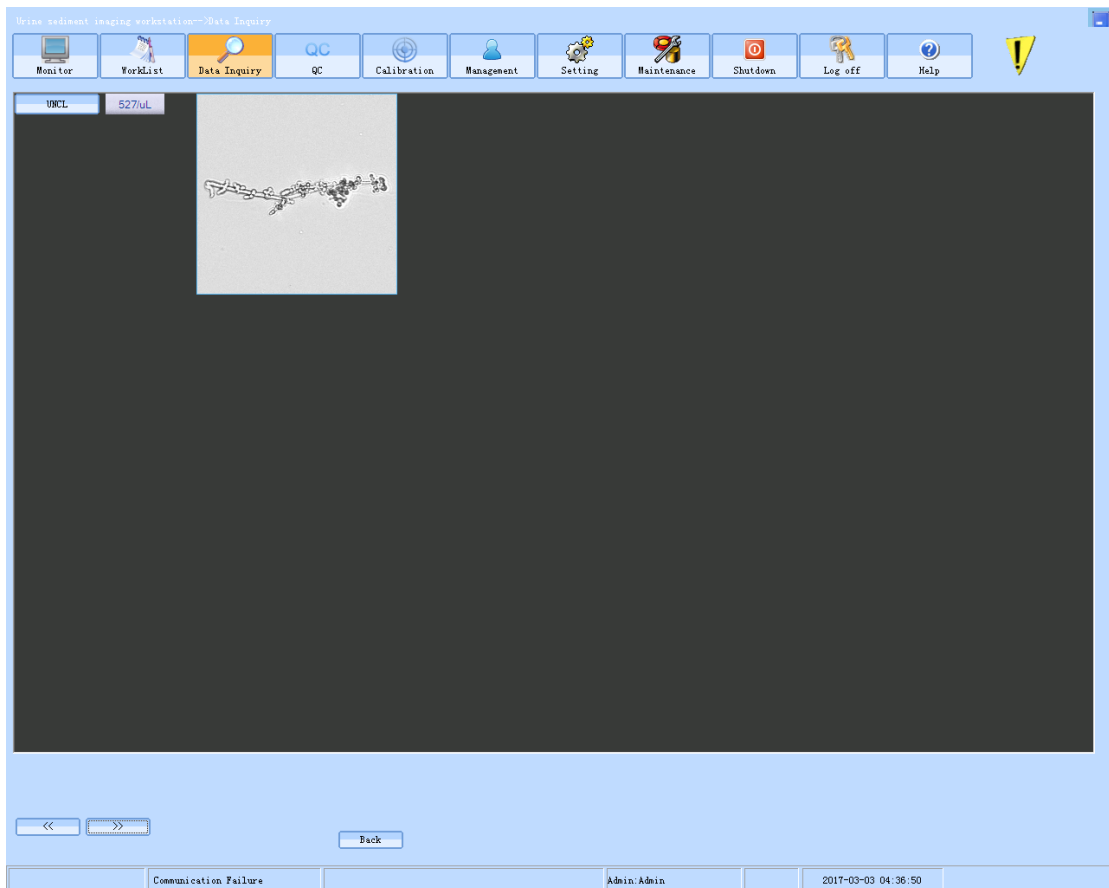


**Yeasts- FUS-2000 big picture**



**Yeasts- - Microscopic picture of stained sediment**

## Candida albicans



**Candida albicans- FUS-2000 isolated picture**



**Candida albicans - - Microscopic picture of native sediment**



Wine sediment imaging workstation - Data Inquiry

Monitor WorkList Data Inquiry QC Calibration Management Setting Maintenance Shutdown Log off Help

Visible Component Concentration Normal Range Abnormal Range Exceed Standard

WBC RBC NSE SQEP BACT CAOX UNCX UNCC MUCS UNCL

95  
2017-02-23  
9/10

29/uL  
118/uL  
ormity RBC  
for causing

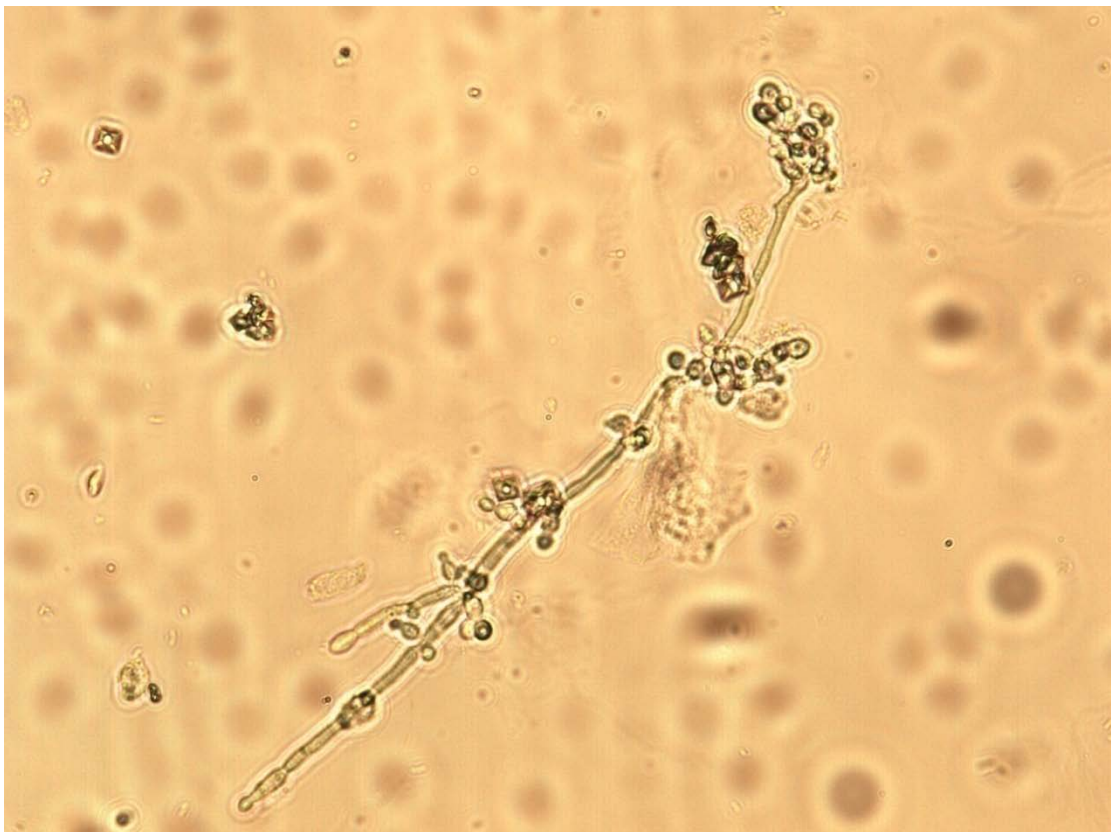WBC  
RBC  
WBCC  
NSE  
SQEP  
BACT  
ART  
HYAL  
RBCT  
GRAN  
WBCT  
CELL  
EPIC  
WAXY  
FATC  
BROAD

Page: 11/13 Previous Next Back

<< >> Previous Next Back Big Picture

Communication Failure Admin: Admin 2017-03-03 04:37:32

**Candida albicans- FUS-2000 big picture**



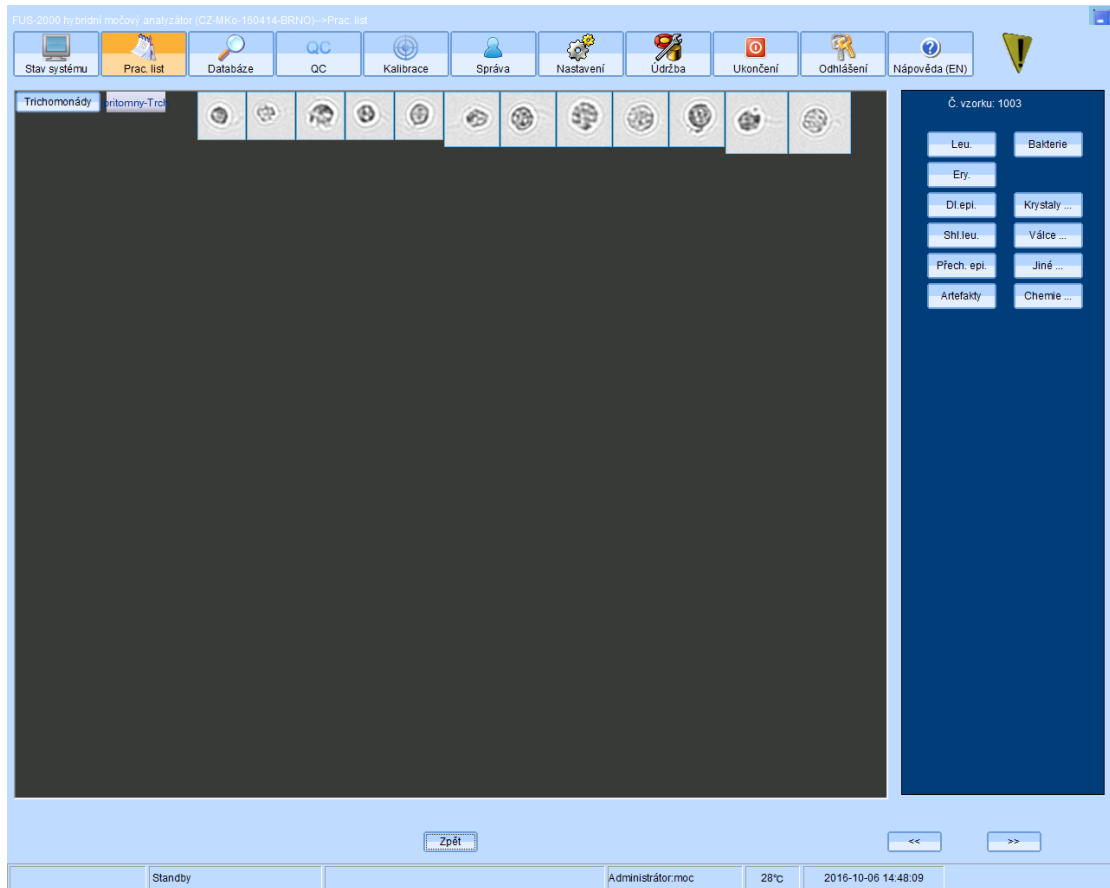
**Candida albicans - - Microscopic picture of stained sediment**

## Parasites and their eggs


Parasites and their eggs in urine specimens were mostly caused by pollution.

- a) *Trichomonads* originate mostly from the female vaginal discharge, commonly found in female urine and occasionally in male.
- b) *Microfilaria* can be detected in the chylolus urine.
- c) Urine contaminated with feces can have intestinal parasites or their eggs detected, such as *amoeba dysenteriae*, *ascarisovas*, *giardia lamblia*blue. *Schistosomeovums* also can enter to urine directly through the bladder mucosa.

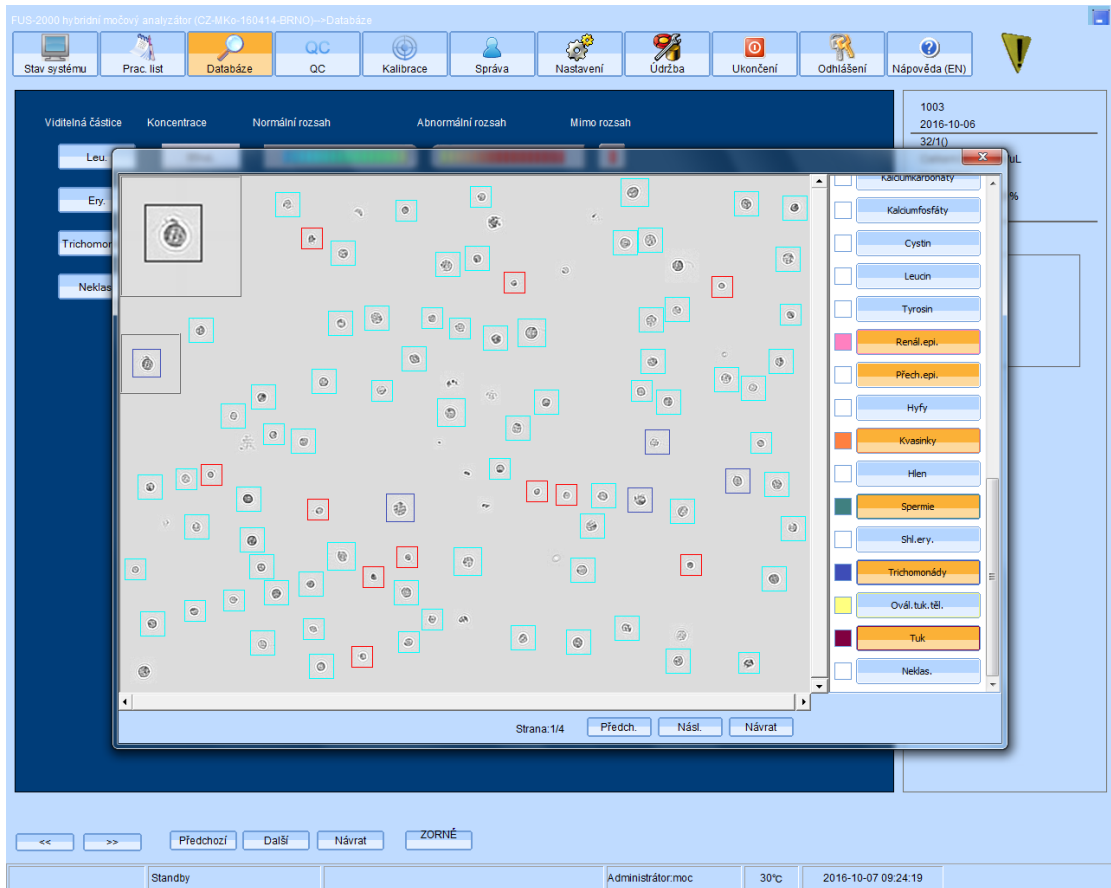
## Trichomonads



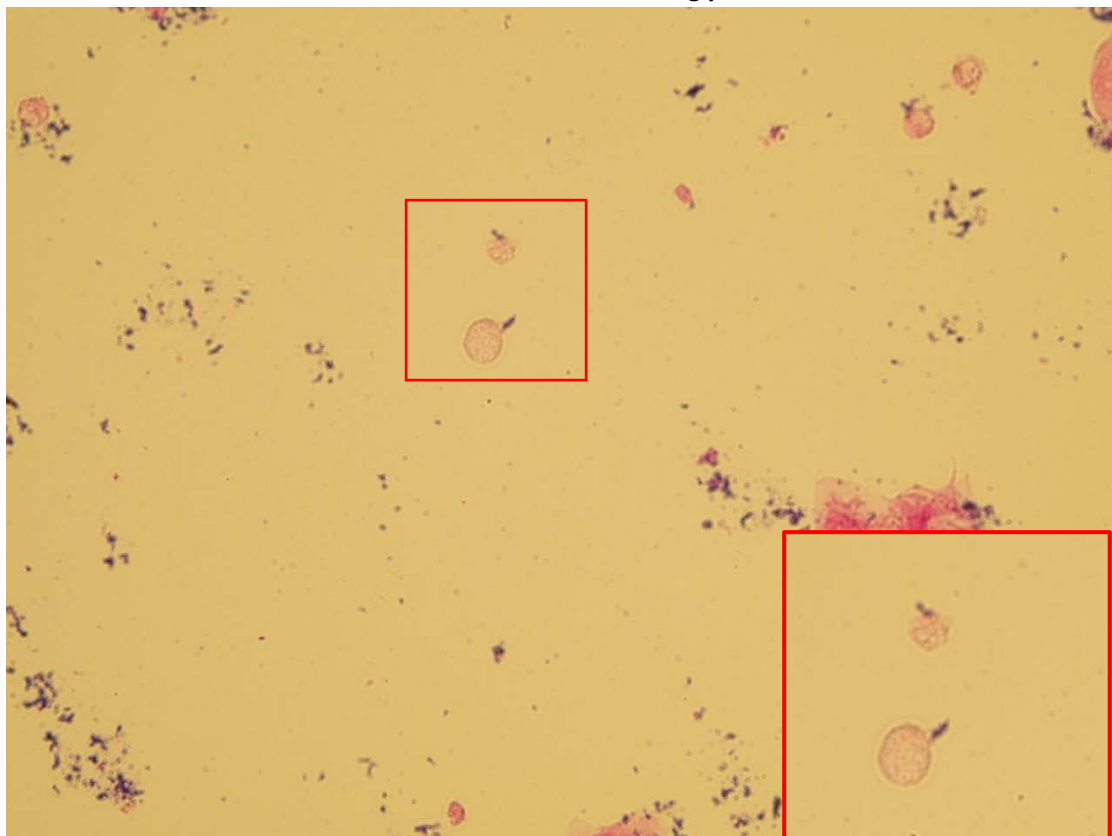
Trichomonads- FUS-2000 isolated picture



Trichomonads - Microscopic picture of native sediment



**Trichomonads- FUS-2000 big picture**

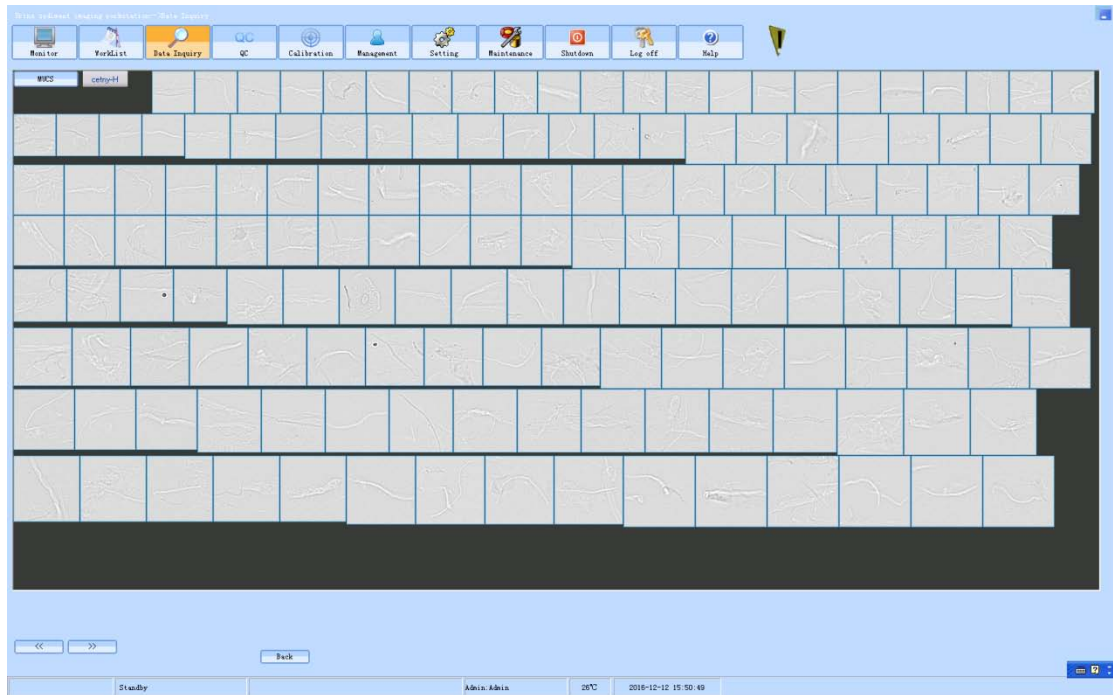


**Trichomonads - Microscopic picture of stained sediment**

## **Mucus**

Mucus is secreted by glands in urinary tract and vagina. Its quantity could be increased with inflammatory conditions. It is common constituent in urine with no diagnostic significance.

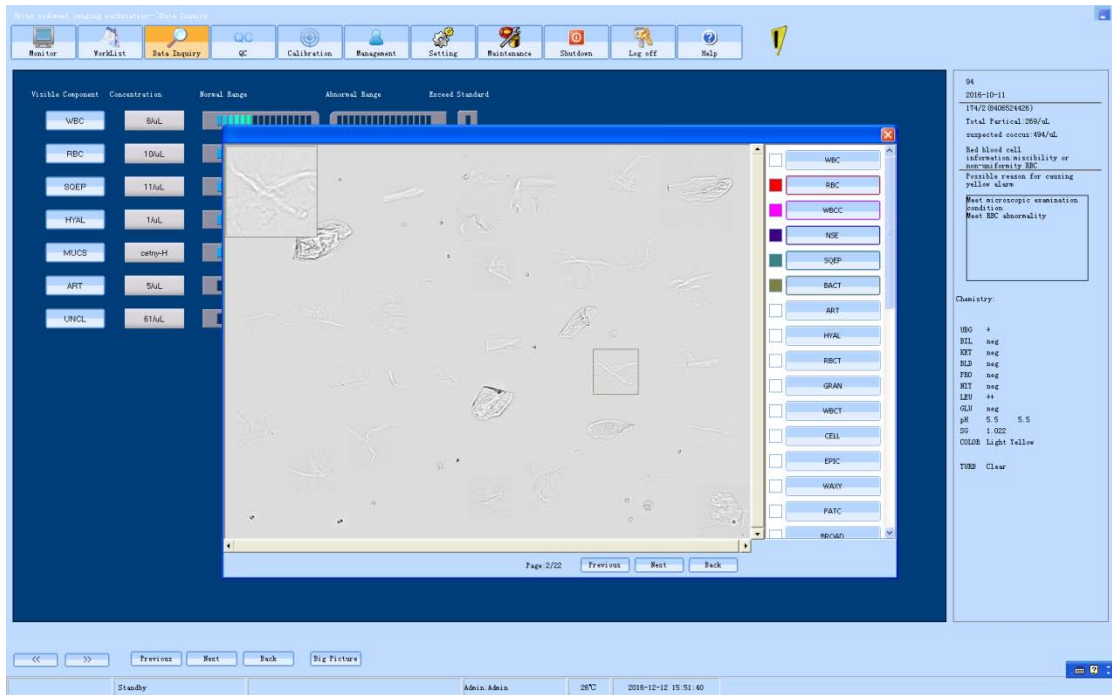
# Mucus



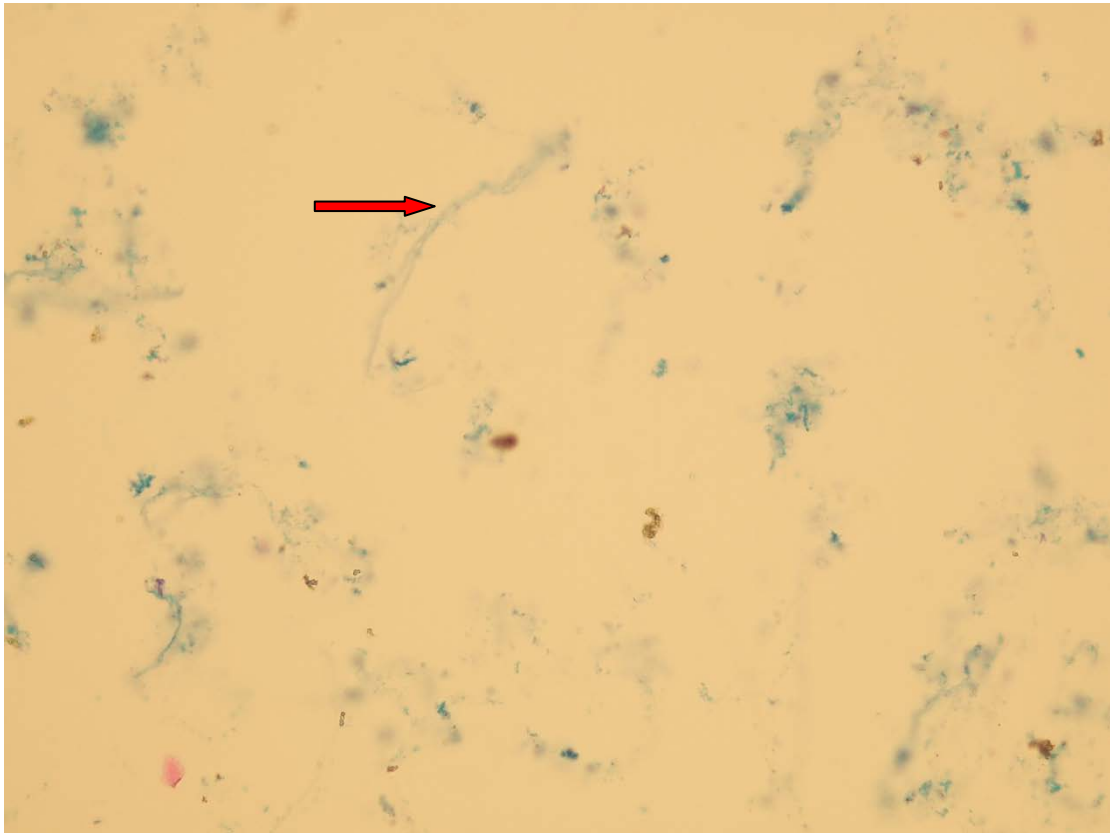
**Mucus- FUS-2000 isolated picture**



**Mucus - Microscopic picture of native sediment**



Mucus- FUS-2000 big picture

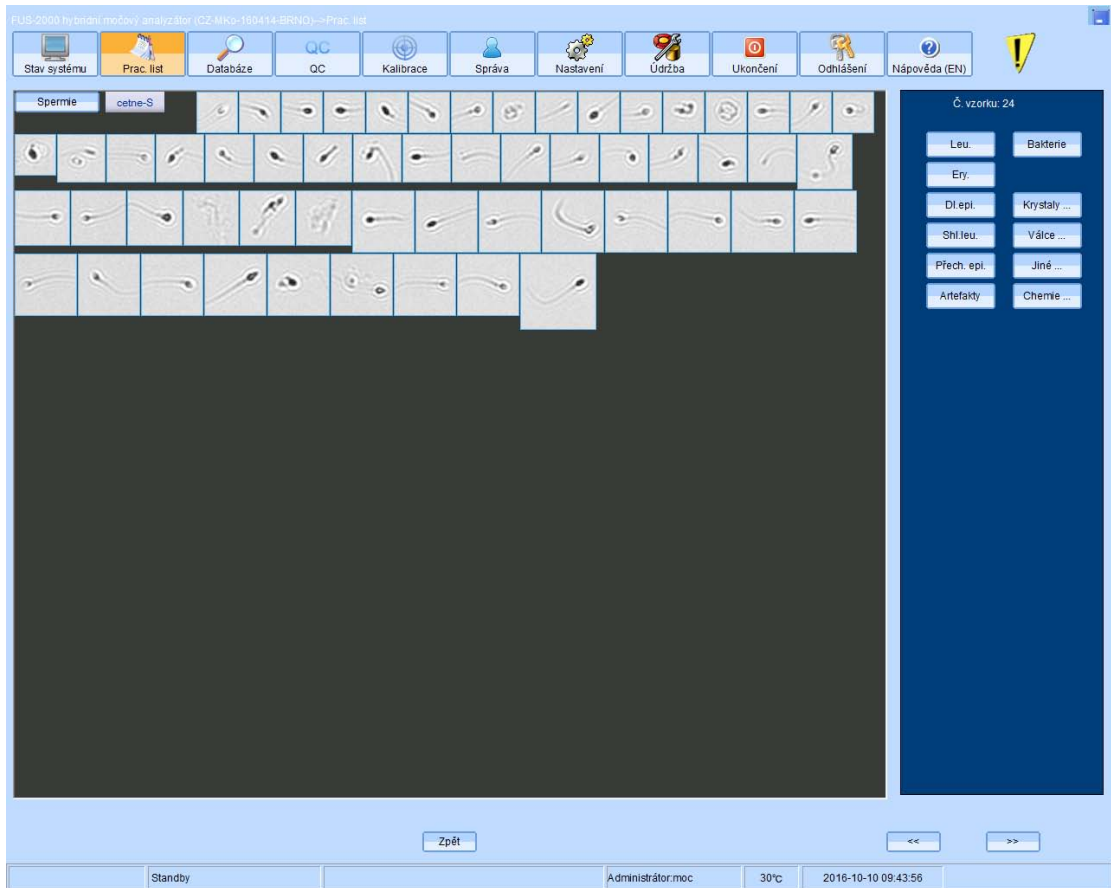


Mucus - Microscopic picture of stained sediment

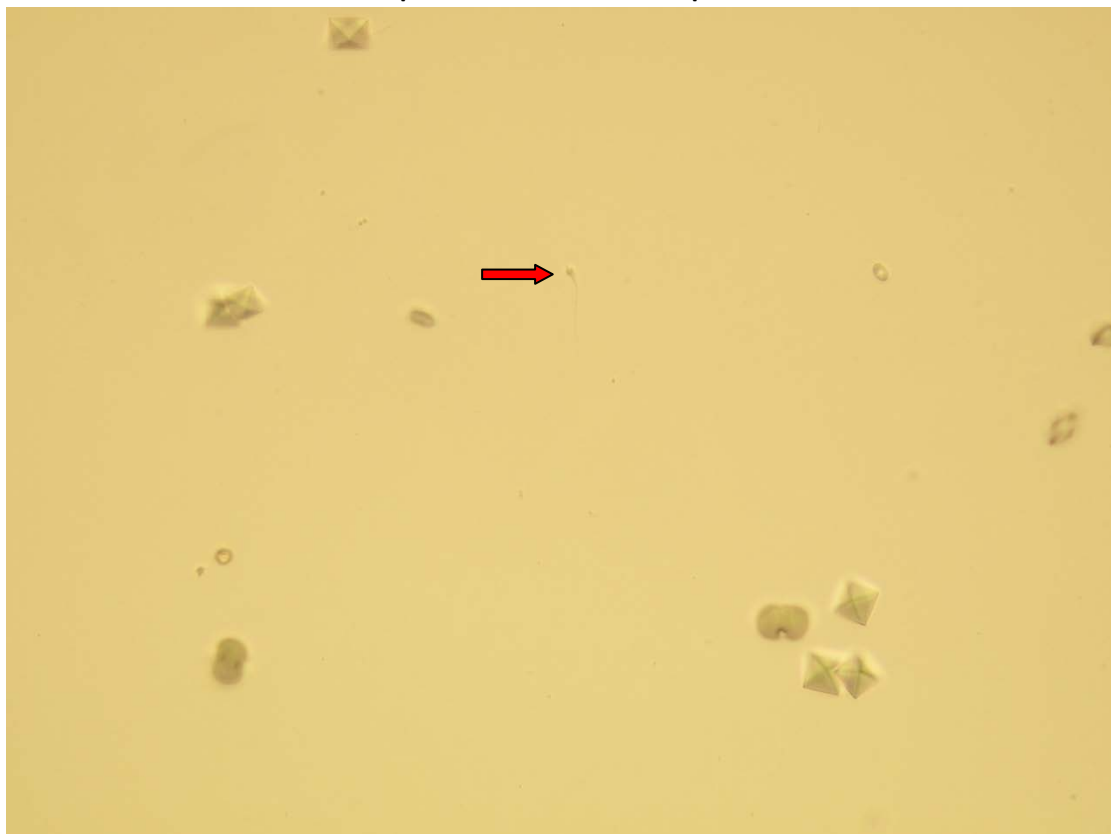

## Sperms

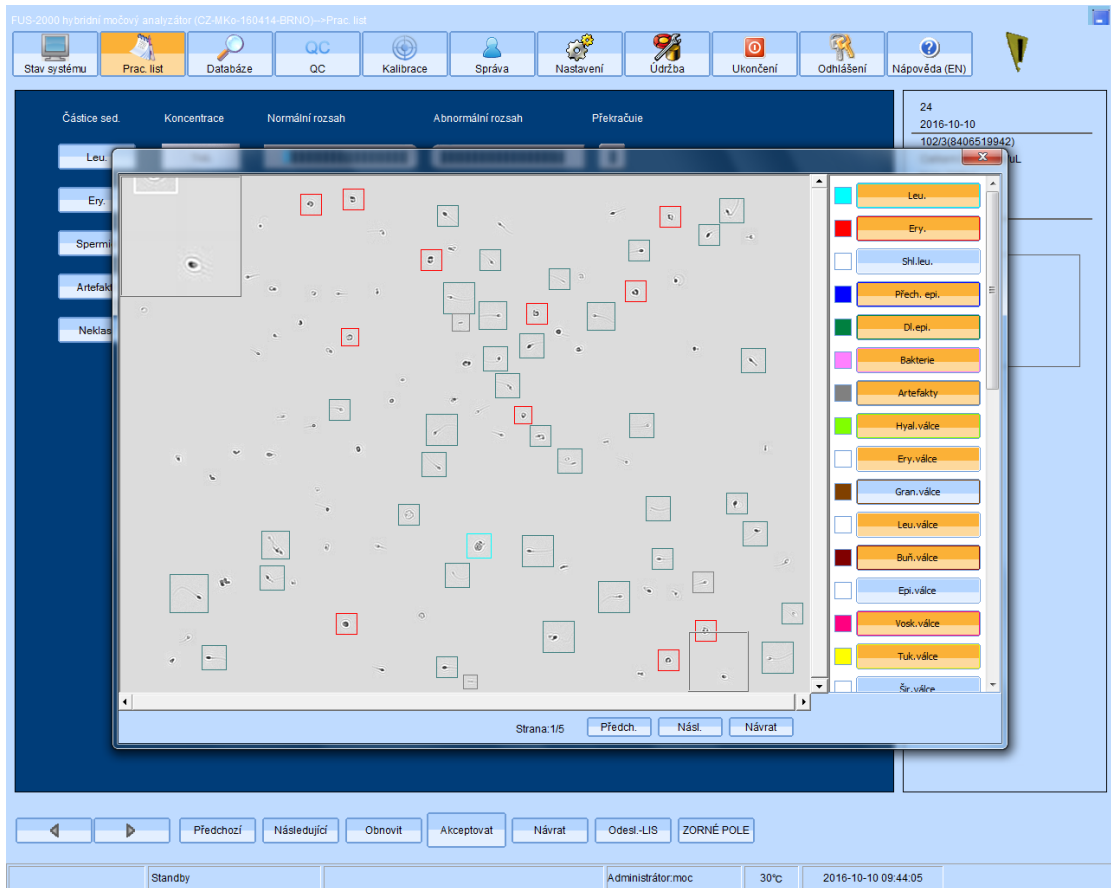
Sperms in the urine are more common in men after spermatorrhea, sexual intercourse or retrograde ejaculation. Sperms contain proteins, so dry chemistry results can be positive.



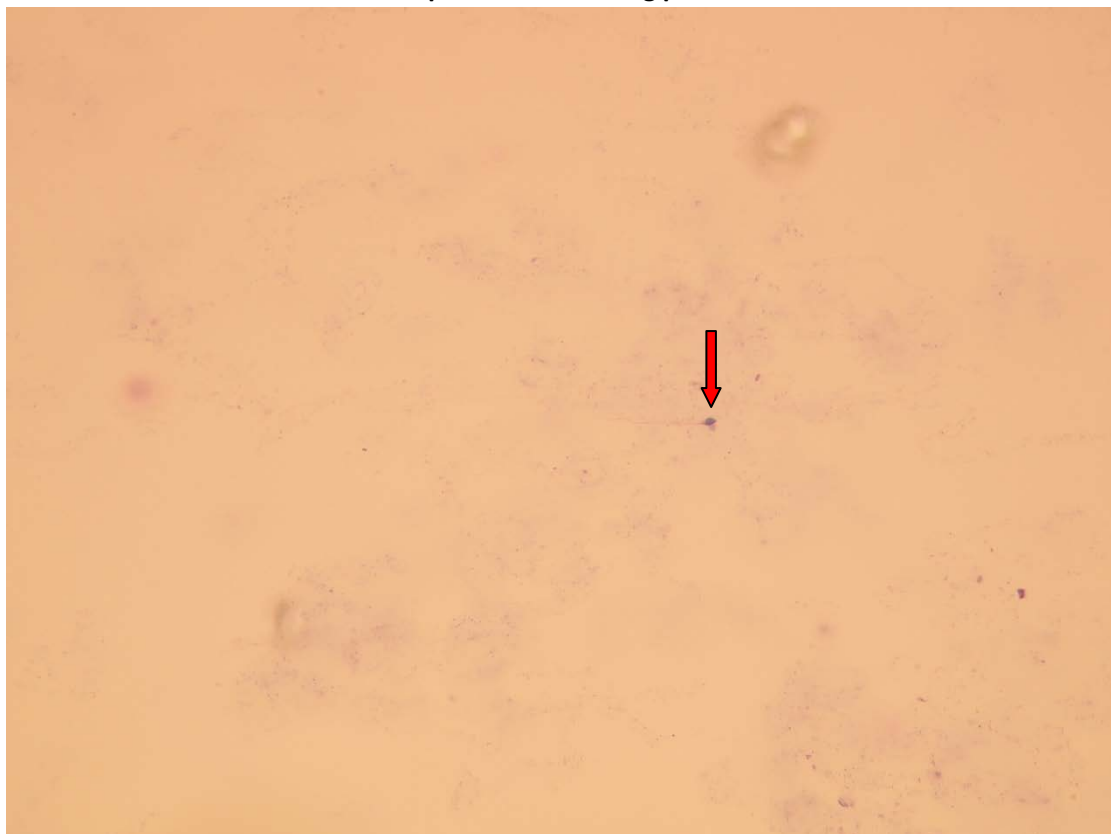**Sperm- FUS-2000 isolated picture**



**Sperm - Microscopic picture of native sediment**



**Sperm- FUS-2000 big picture**

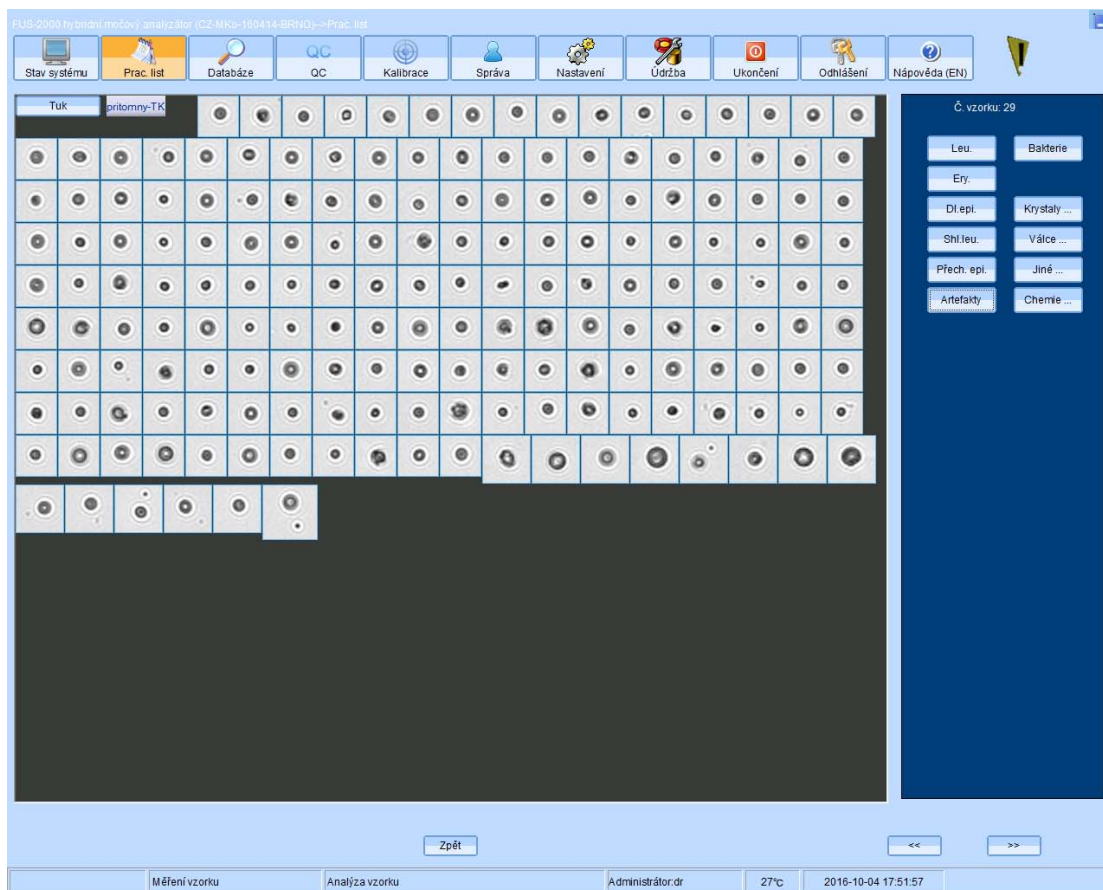


**Sperm - Microscopic picture of stained sediment**

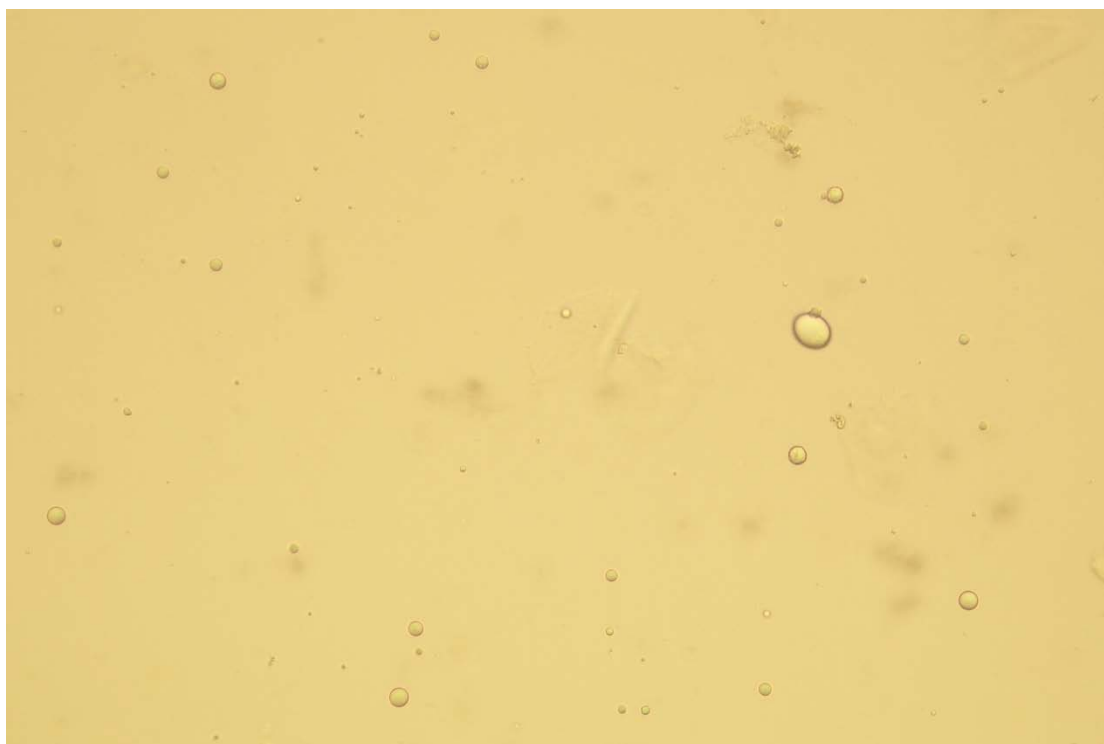
## Other Formed Elements

If mixed with succus prostaticus, the urine can be detected with fat bodies (phosphatidylcholine bodies), granular cells of prostate and starch bodies. If drinking dried flowers or ganoderma spores powder, the urine can be detected with pollen or spore particles.

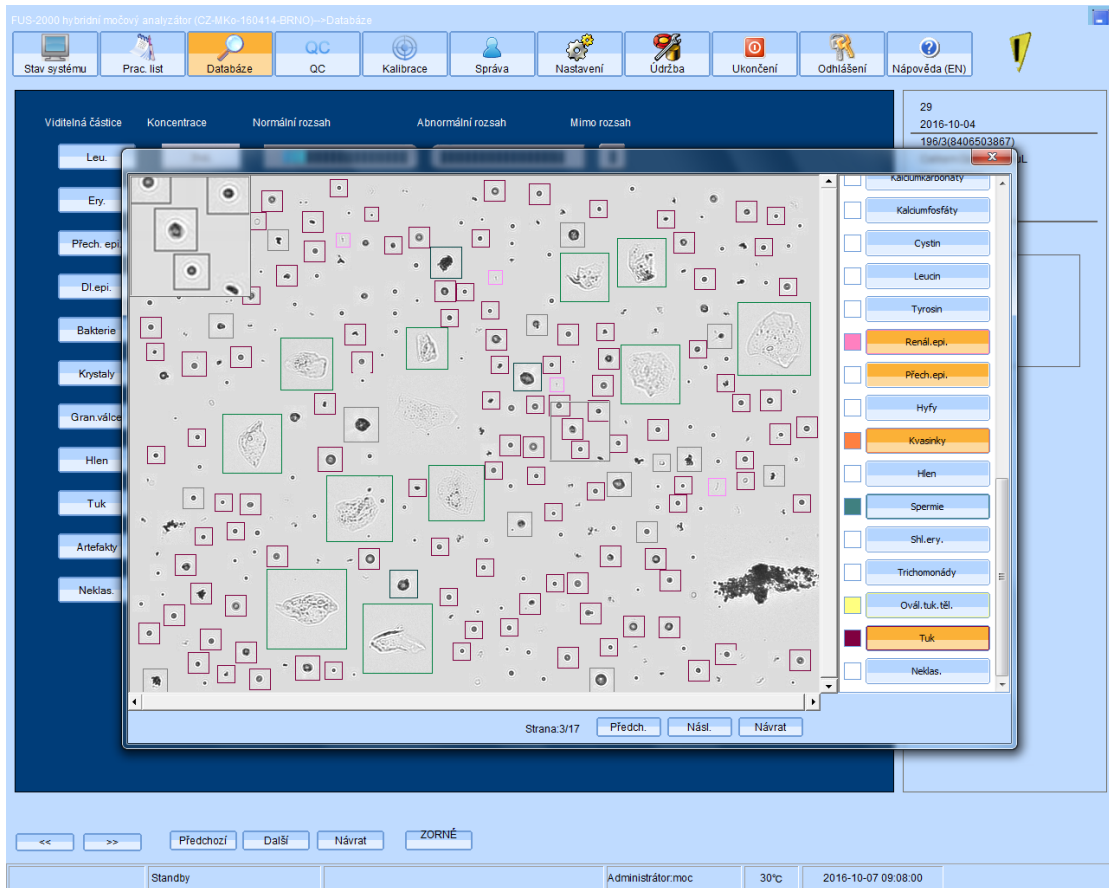
## Fat Droplets



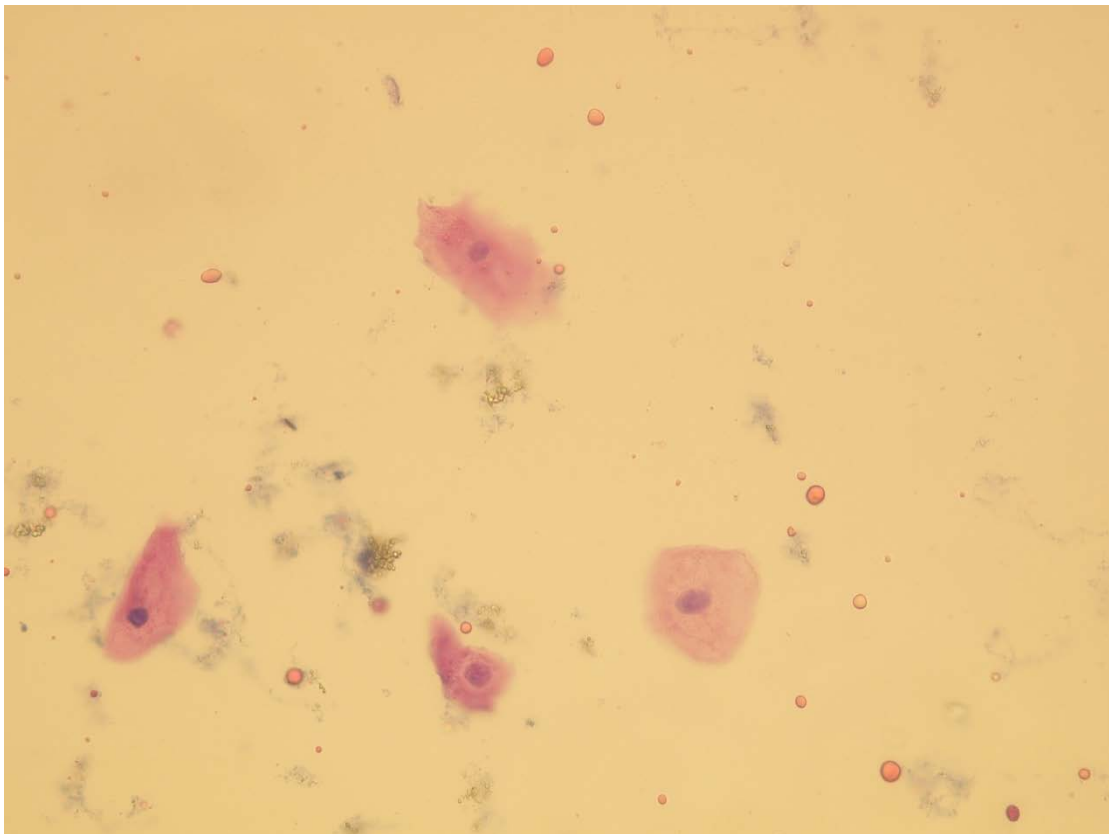
**Fat Droplets- FUS-2000 isolated picture**



**Fat droplets - Microscopic picture of native sediment**

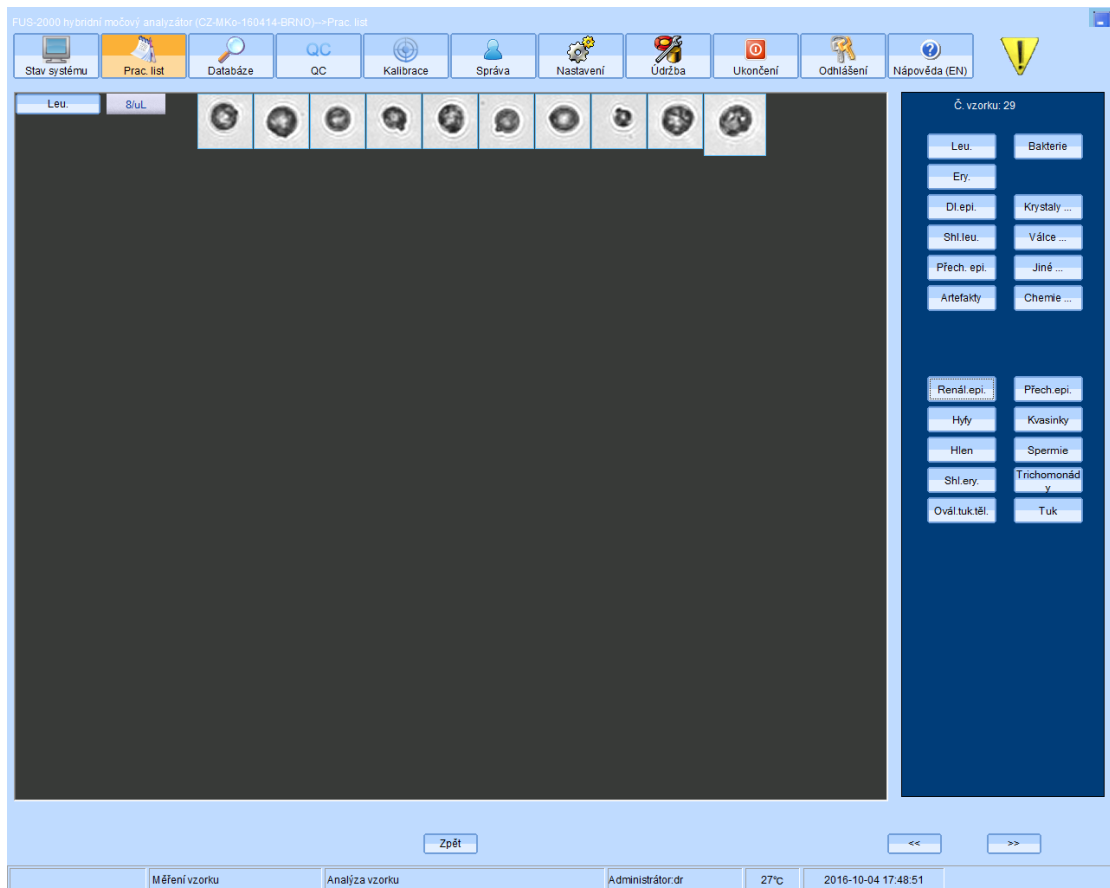


**Fat Droplets- FUS-2000 big picture**

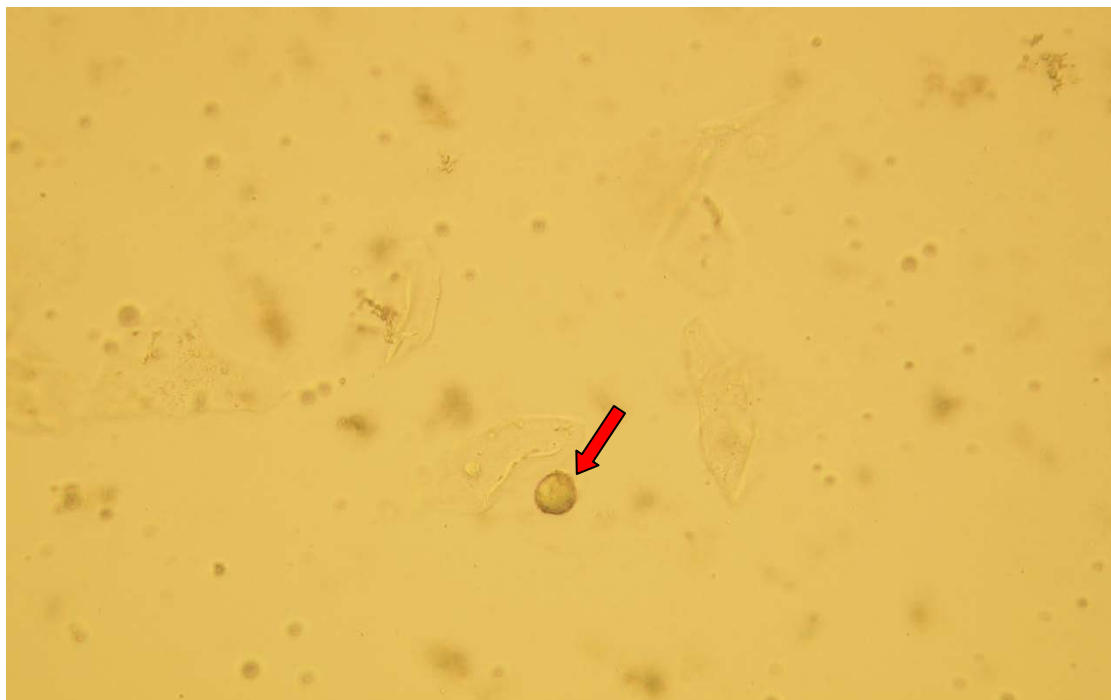

**Fat droplets - Microscopic picture of stained sediment**

## Starch Bodies

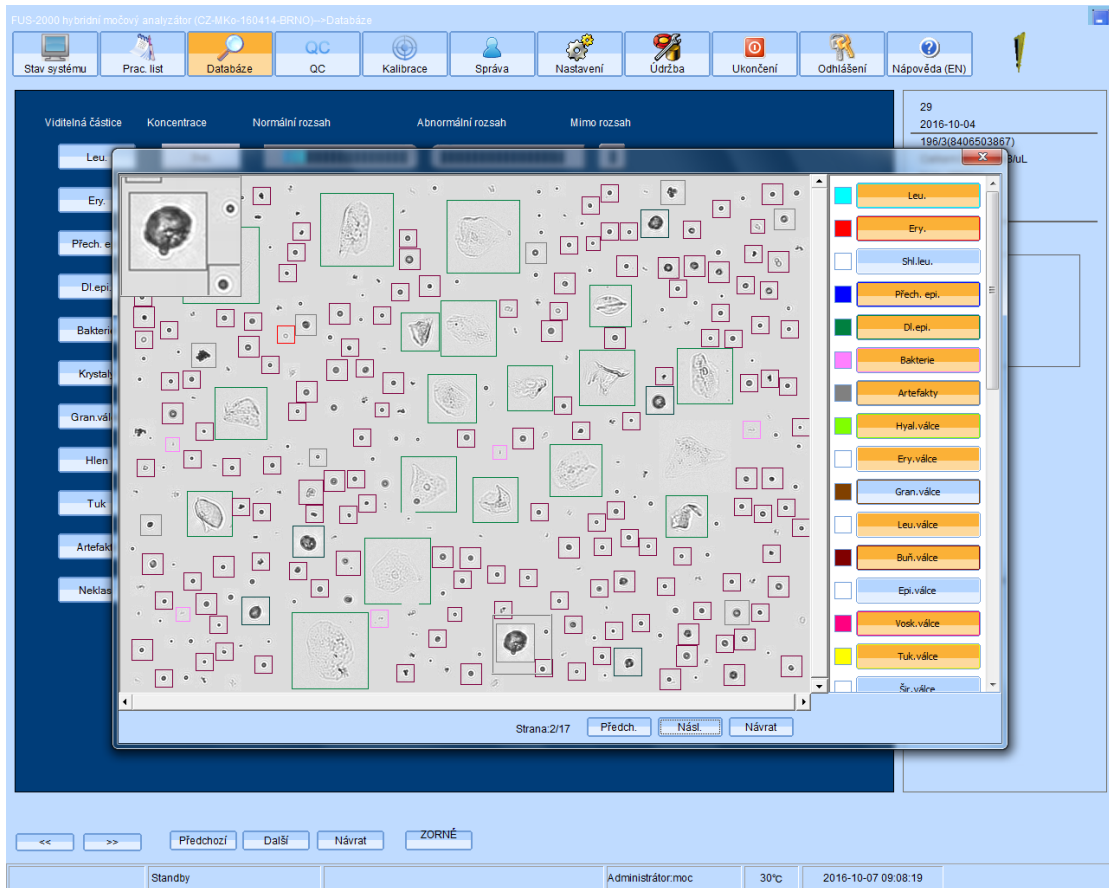


Starch bodies- FUS-2000 isolated picture

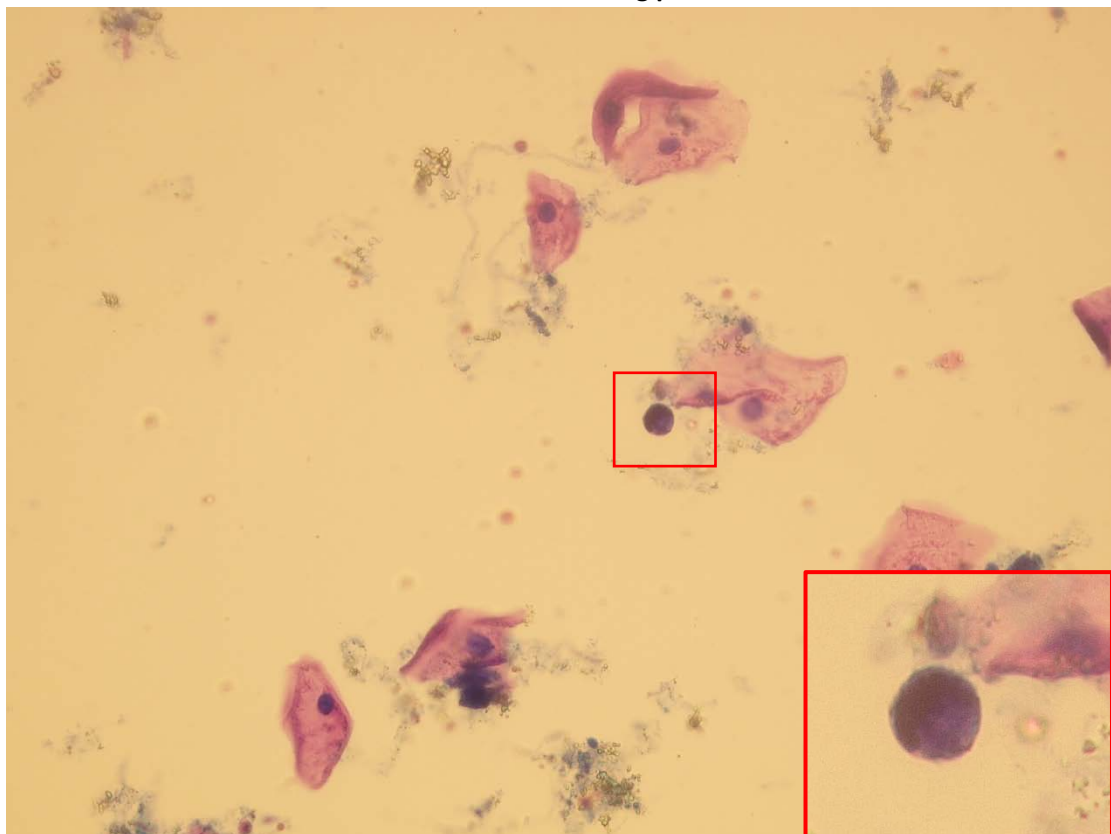


Starch bodies - Microscopic picture of native sediment





**Starch bodies- FUS-2000 big picture**

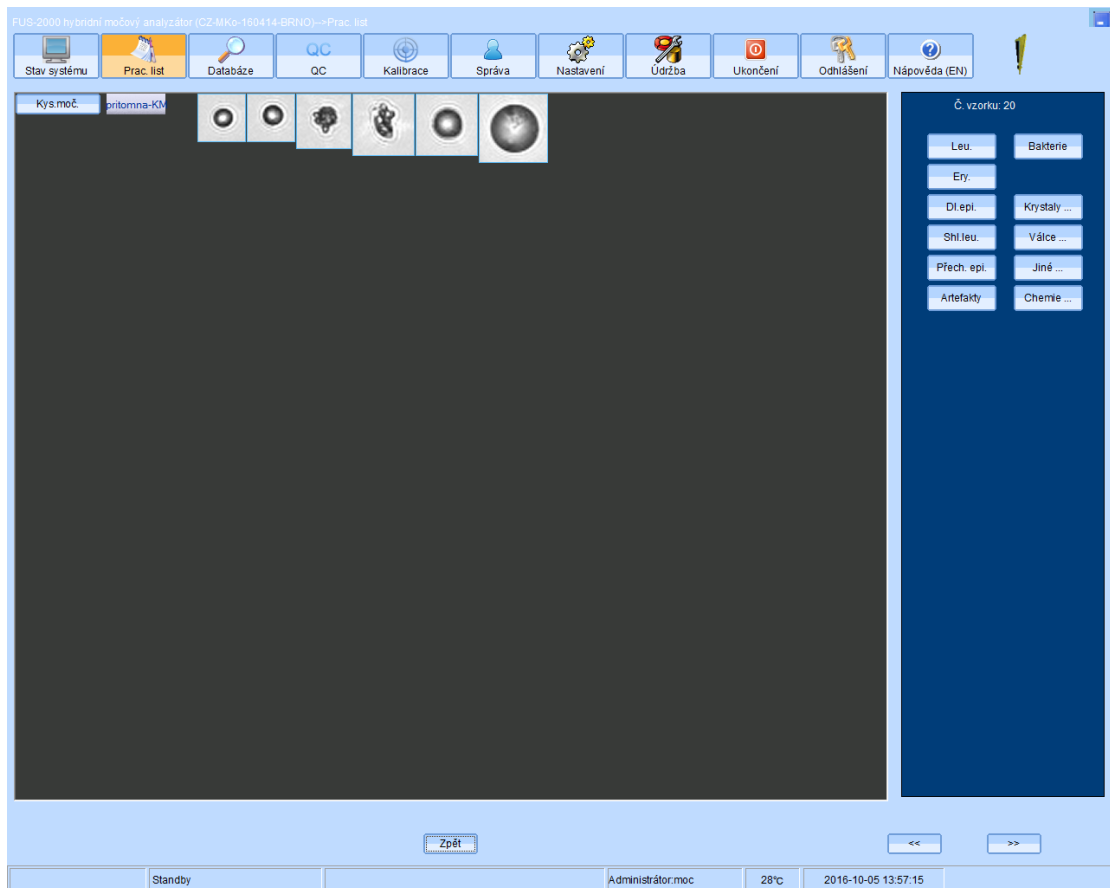


**Starch bodies - Microscopic picture of stained sediment**


## Artifacts

We can find some elements in urine that don't come from patient's body. Fibrous materials such as hair, cotton and chemical fabrics fiber can be present. It has big volume, moderate or high degree of refraction, dark and thick edge.

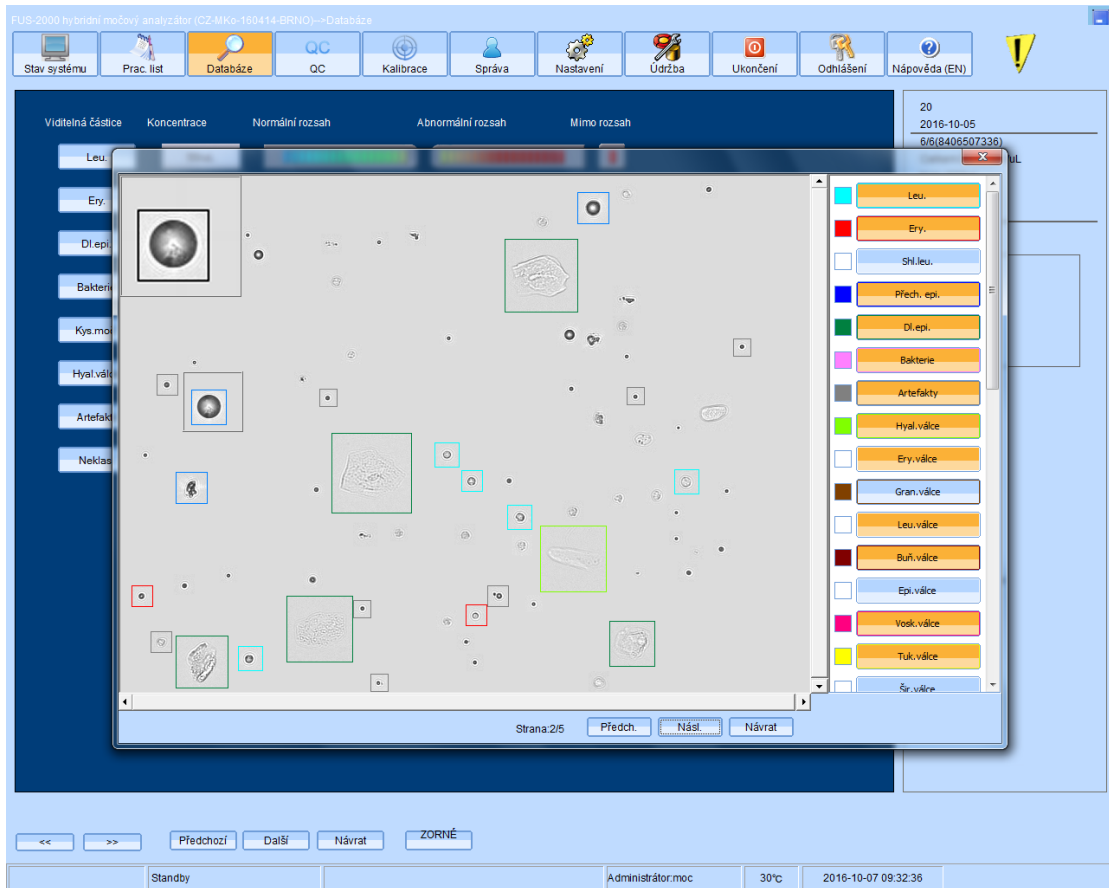
## Artificial Oil



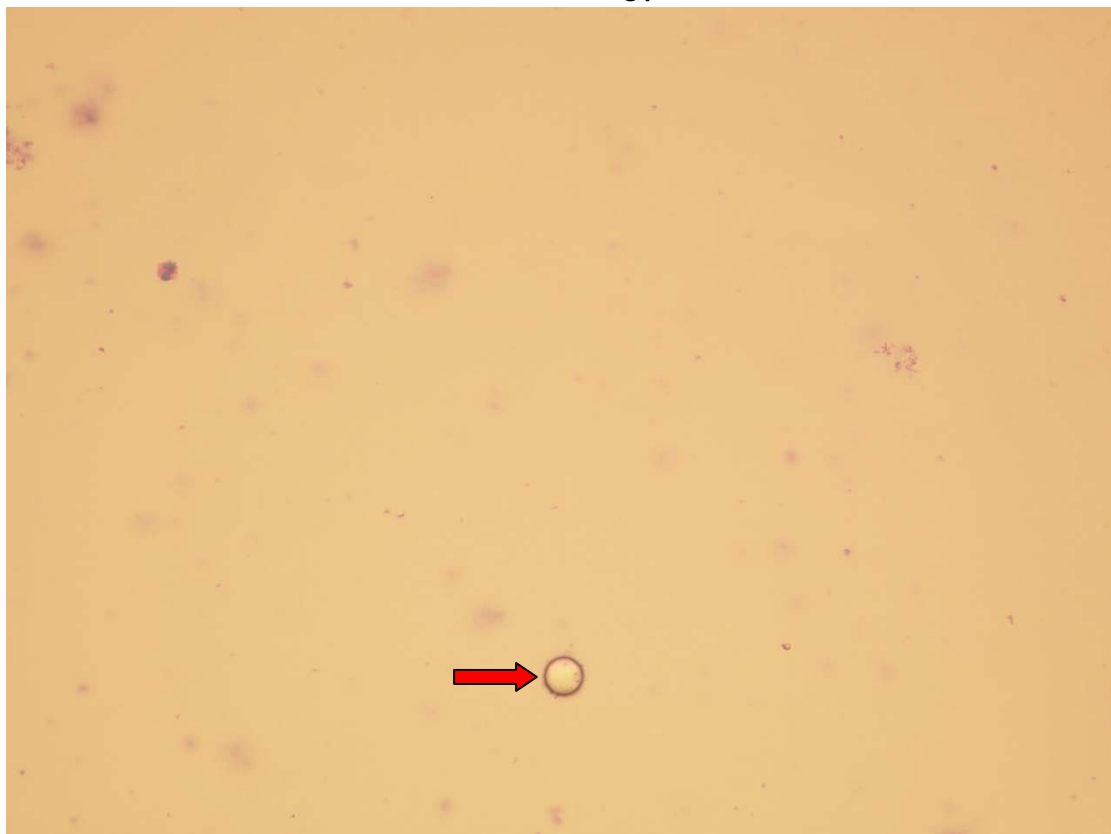
Artificial oil- FUS-2000 isolated picture



Artificial oil - Microscopic picture of native sediment

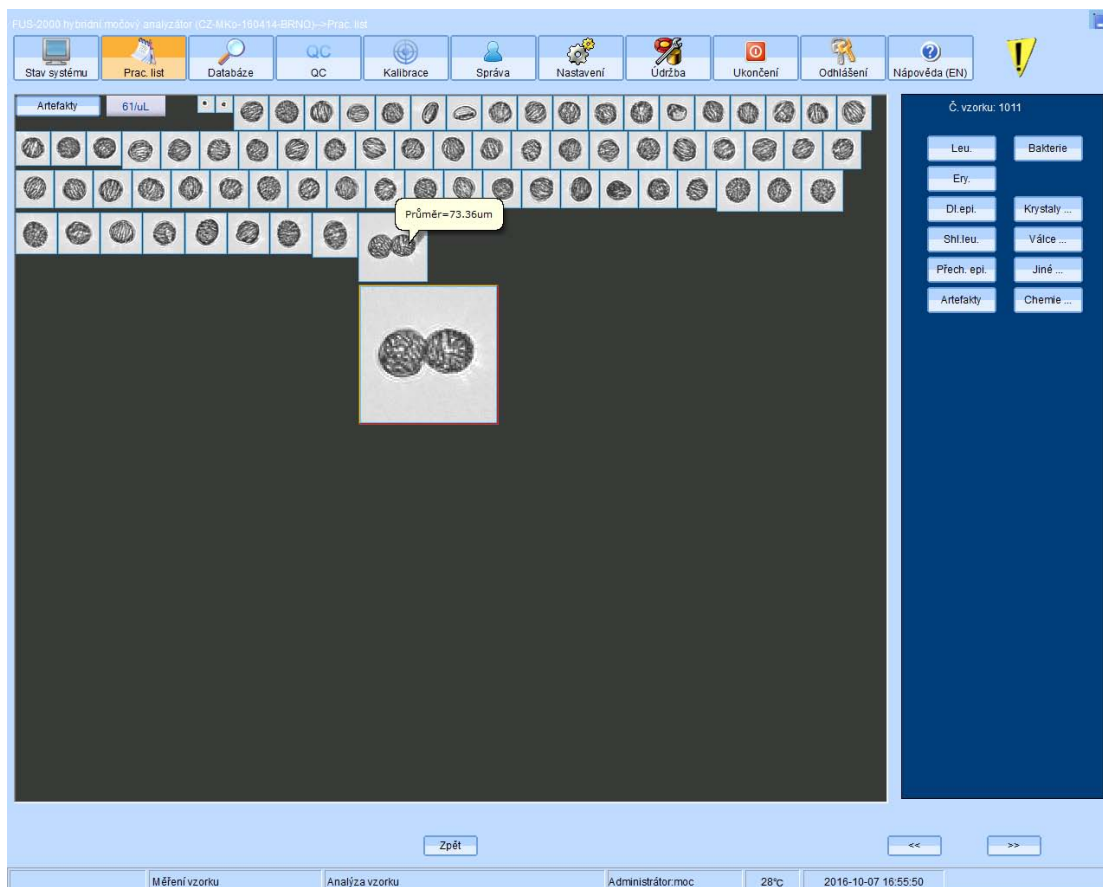


**Artificial oil- FUS-2000 big picture**

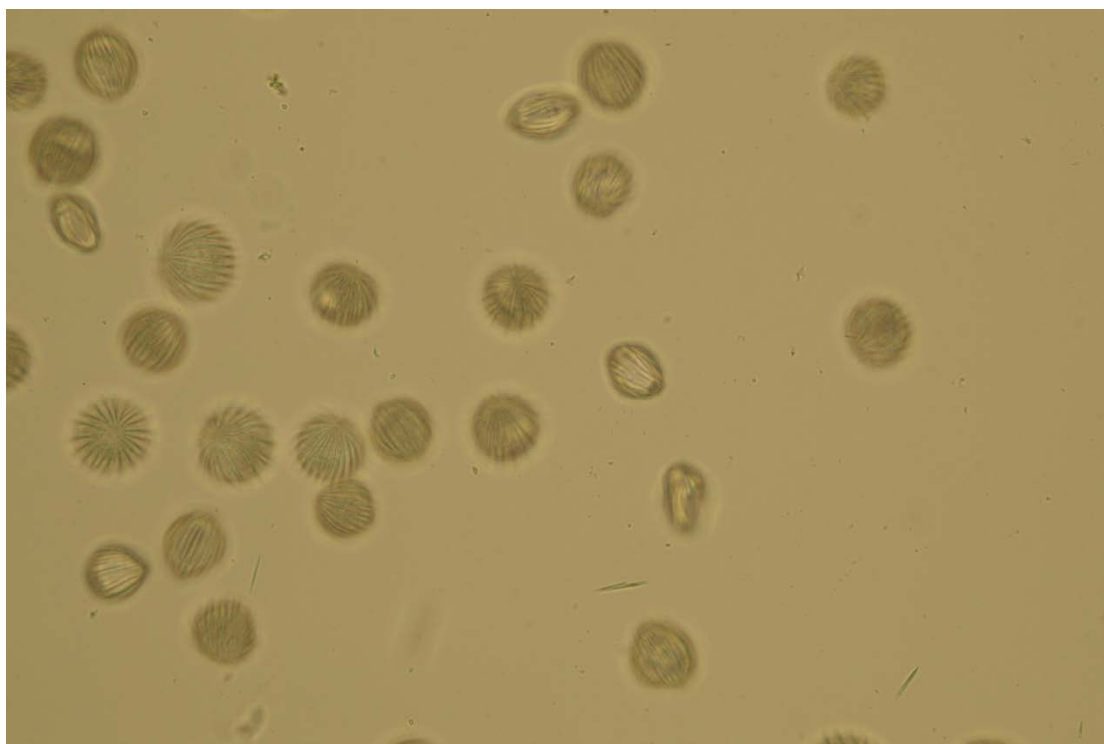

**Artificial oil - Microscopic picture of stained sediment**

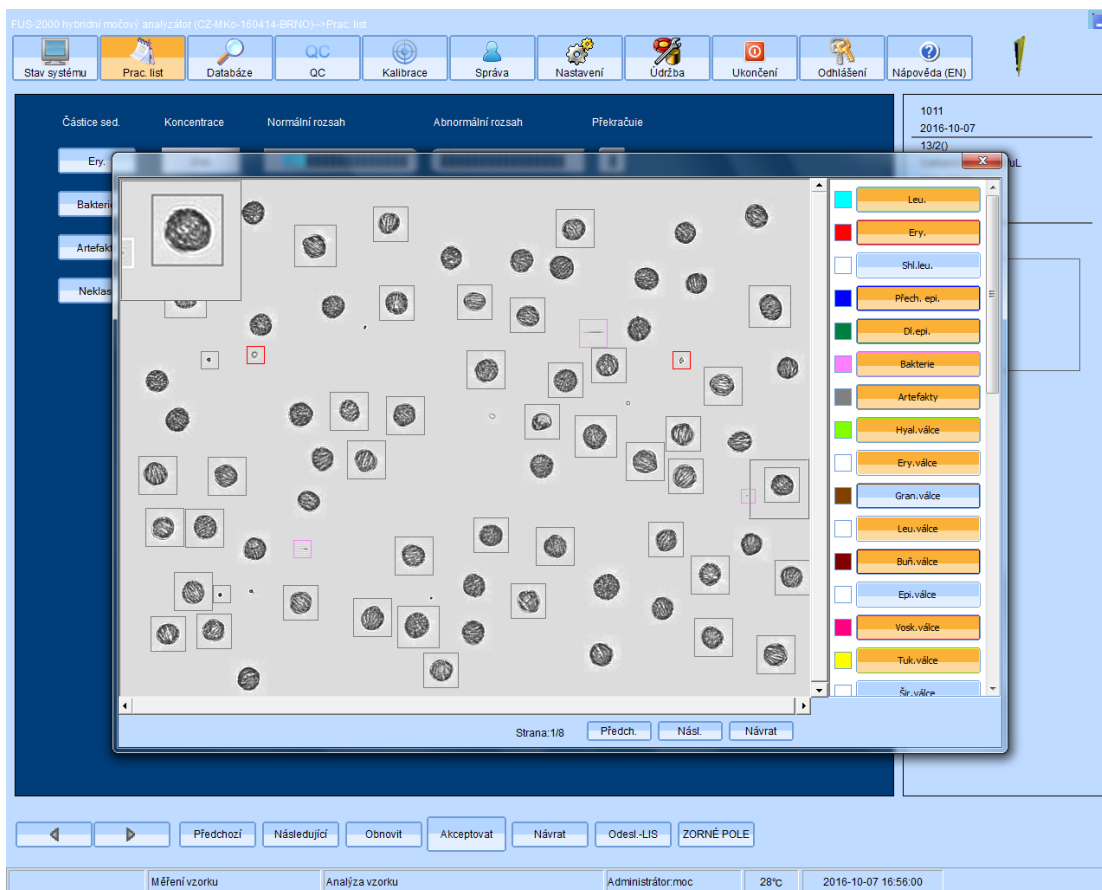
## Pollen



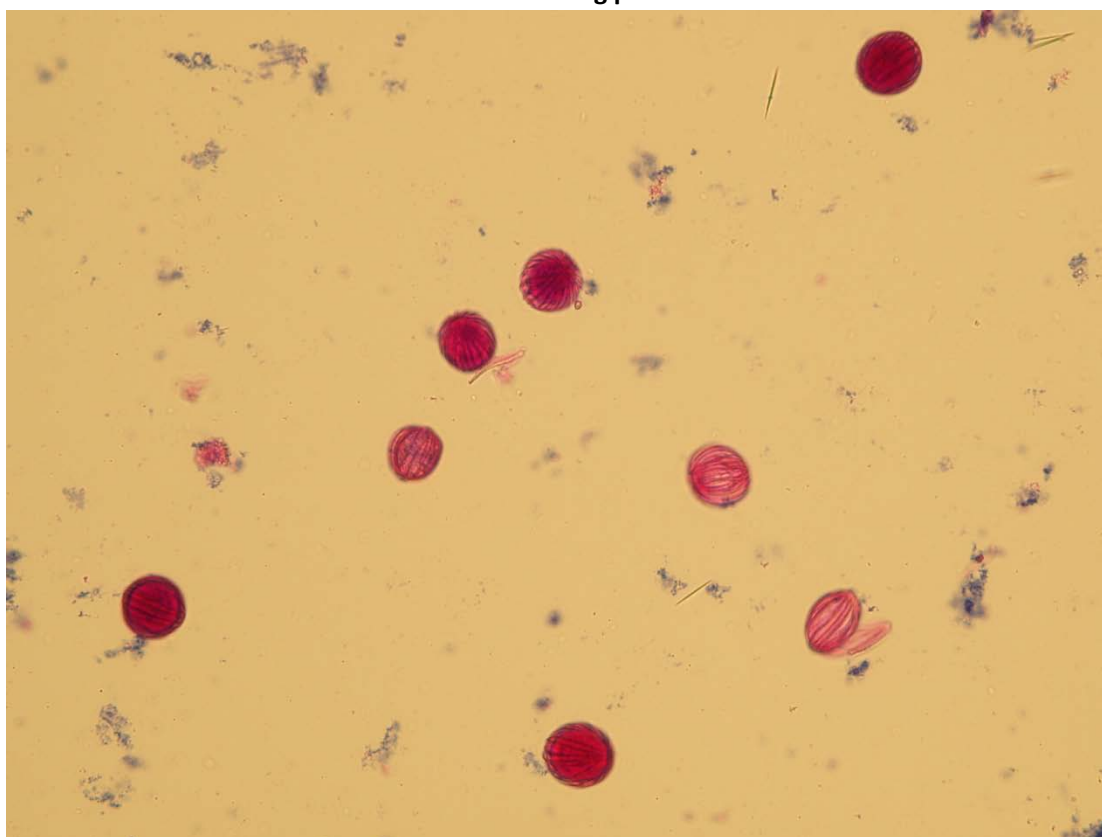
Pollen- FUS-2000 isolated picture



Pollen - Microscopic picture of native sediment



**Pollen- FUS-2000 big picture**

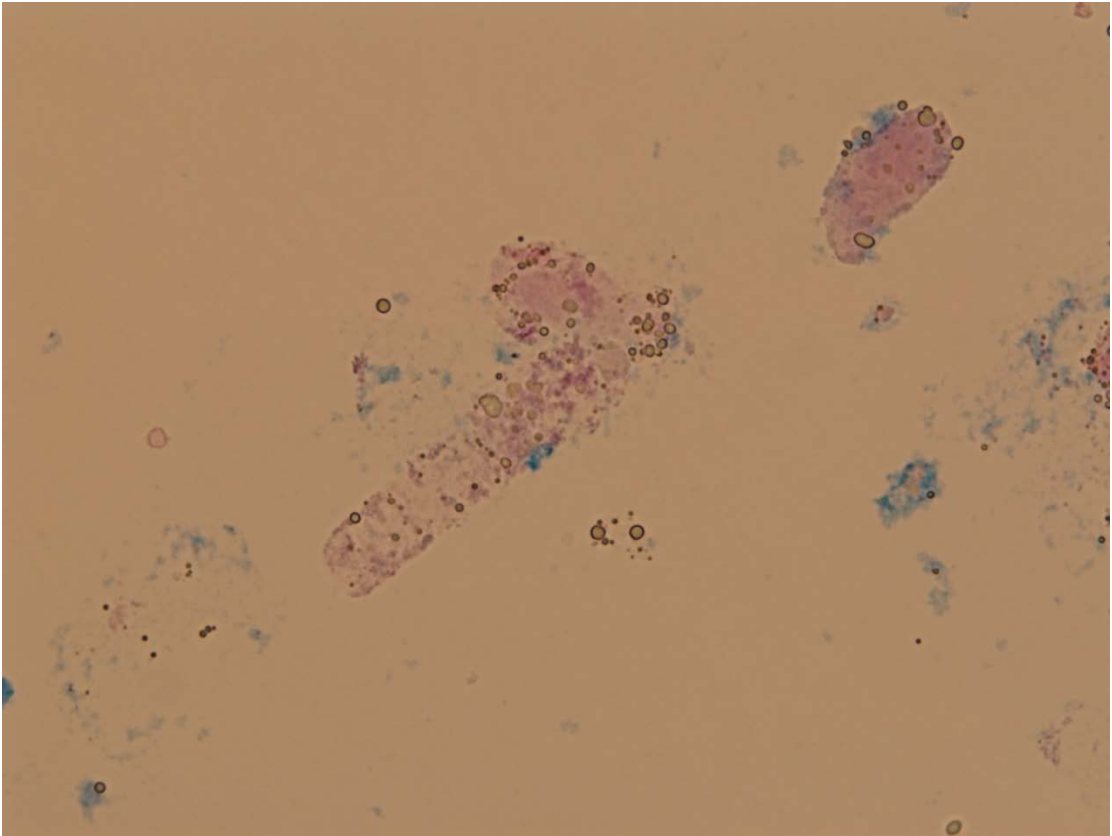


**Pollen - Microscopic picture of stained sediment**

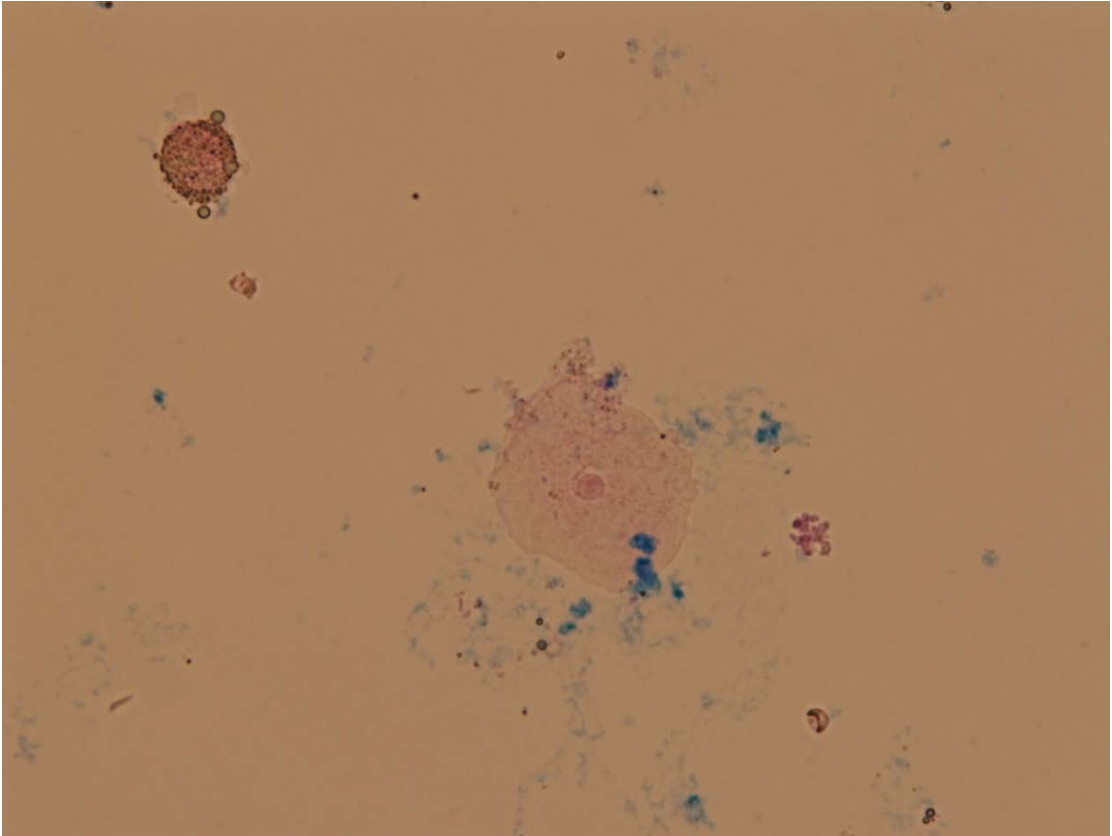
## Case Studies

### 1. The finding of fat particles in patients with nephritic syndrome

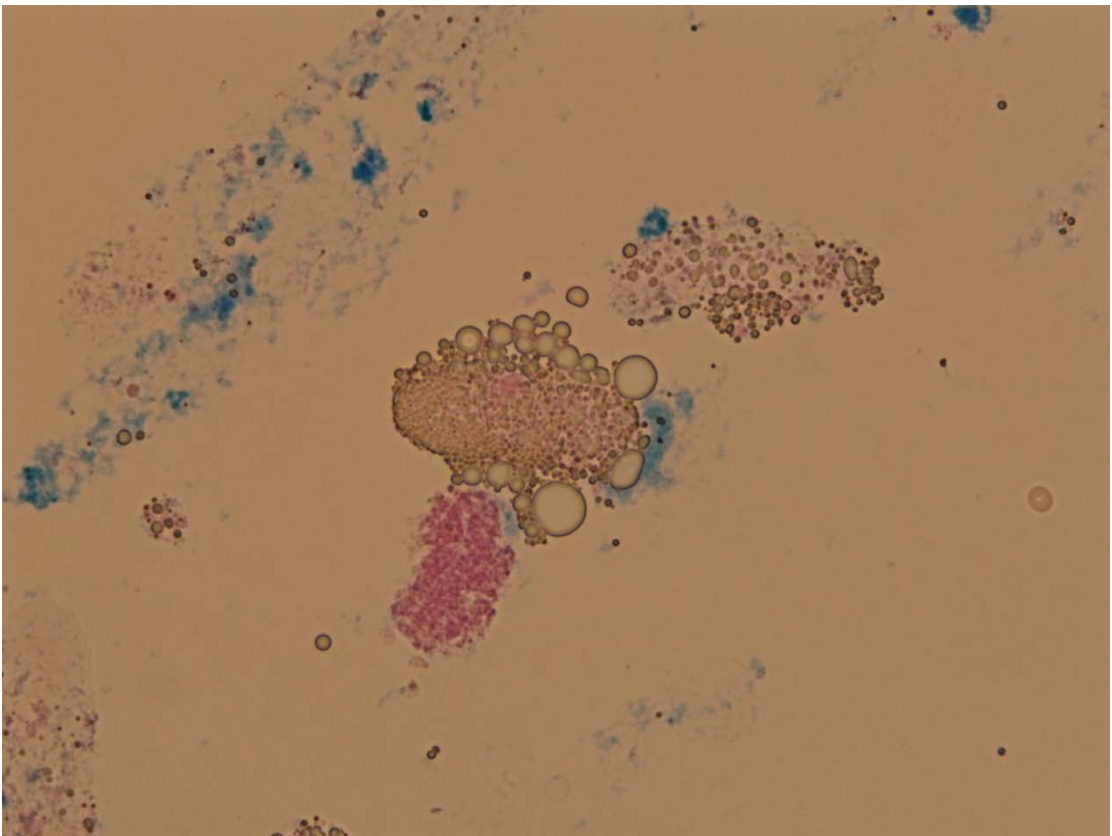
The elements listed below were found in urine of patient with nephrotic syndrome.



*Hyaline cast with fat inclusions of fat droplets*



*Squamous epithelial cell and oval fat body*

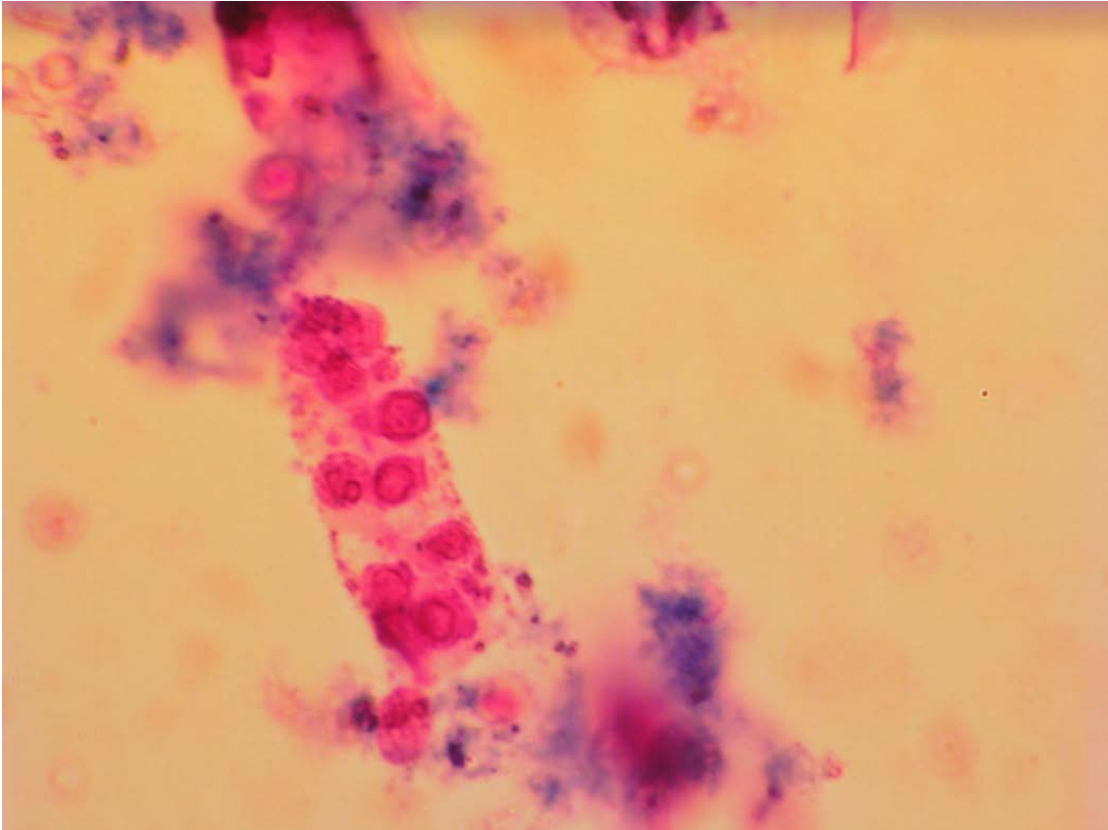


*Fatty cast and free fat droplets*

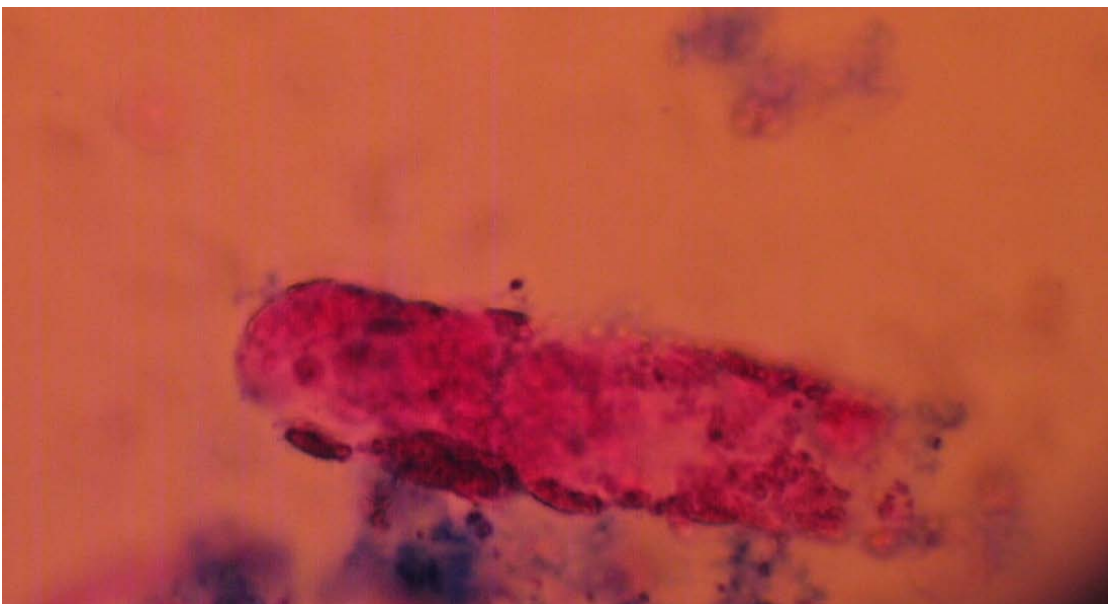


## 2. The gradual transformation of pathological casts

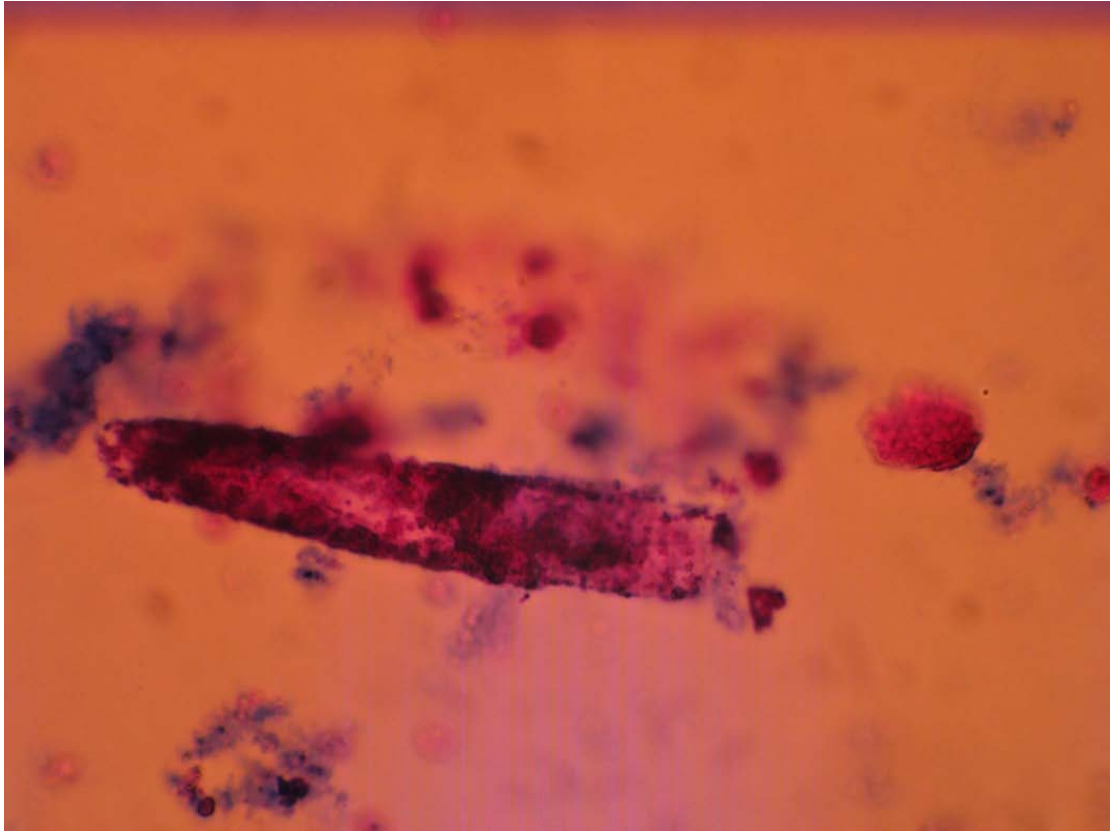
Exceptionally, all stages of cast transformations could be observed in one sample



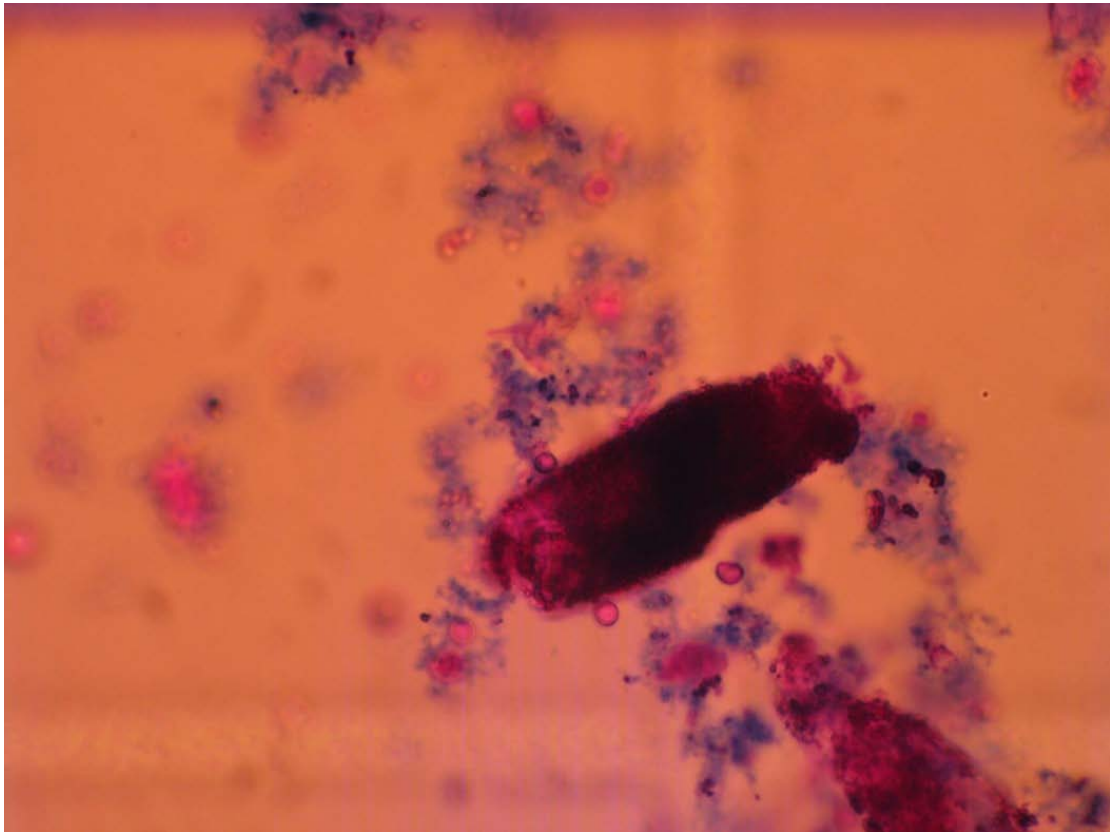
*Cellular cast*



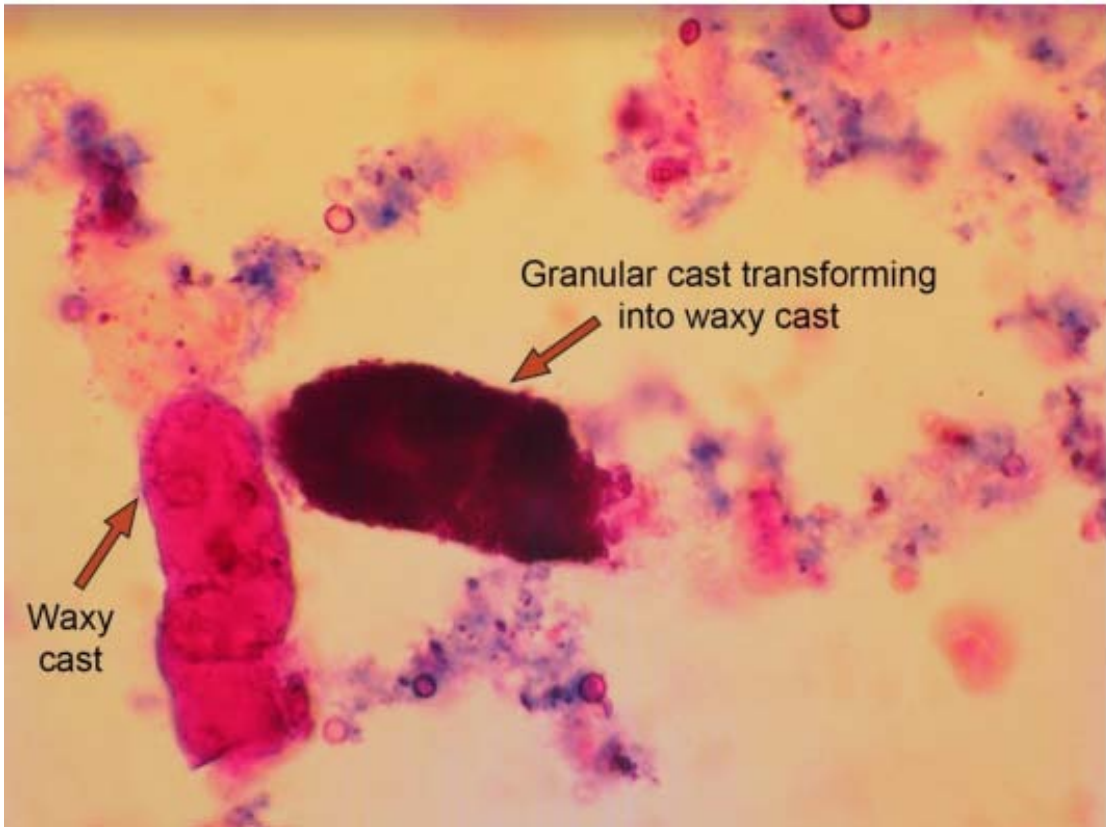
*Transition phase of cast from cellular to granular (enlargement  $\times 600$ )*



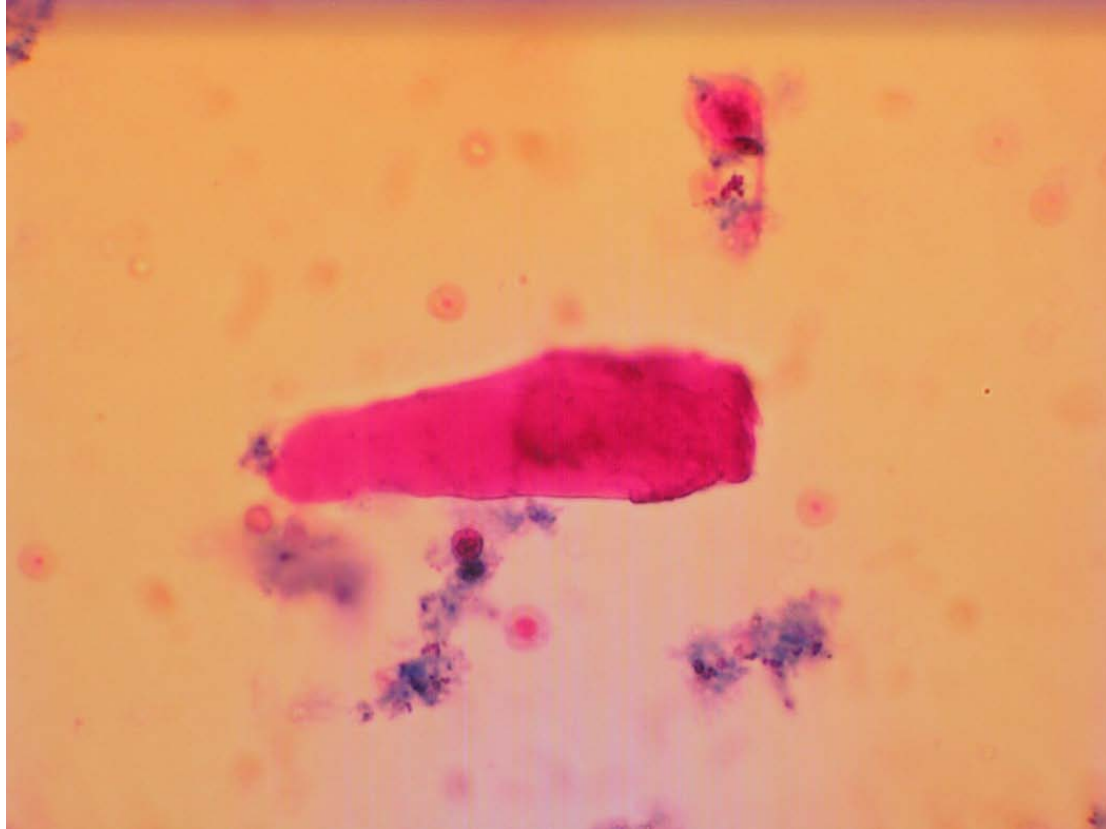*Transition phase of cast from cellular to granular*



*Granular cast*



*Transition phase of cast from granular to waxy and waxy cast*



*Waxy cast*

## Company Profile

Located in Changchun, the heart of North Eastern China, DIRUI Industrial Co., Ltd is a publicly traded supplier of world class laboratory solutions. Dirui is currently listed on the Shenzhen Stock Exchange GEM symbol (300396)

Since its establishment in 1992, DIRUI has been dedicated to the R&D, manufacturing, and sales of high quality diagnostic products including laboratory equipment and clinical diagnostic reagents. Dirui's collective product portfolio represents complete laboratory solutions for the in-vitro diagnostic areas of hematology, clinical chemistry, and urinalysis.

As a pioneer in the mainland China market of in-vitro diagnostics, Dirui has established itself as a leader in the technological development and production of leading edge diagnostic equipment and reagents. Beginning with Dirui's rise as the first domestic manufacturer of urinalysis reagent strips in the early 90's, over the past 20 plus years Dirui has grown and matured into a professional supplier of highly sophisticated diagnostic products

Dirui's product development growth has been marked by the collective success of 158 national patents. Following the success of becoming the first China mainland manufacturer of Anti-VC interference urinalysis diagnostic strips, Dirui's pioneering research and development accelerated into the field of complex and sophisticated machinery. This acceleration has been defined by the breakthrough production of; China's first fully automated urine dry chemistry analyzers, the H-800, and China's first high speed clinical chemistry analyzers, the CS-800. Dirui continues to be on the leading edge of product development and production with the recent launch of China's first and the world's only urine dry chemistry and urine flow cytometry sediment analyzer hybrid, the game changing FUS-2000.

Our product's result reliability and quality are the core values of Dirui's development and manufacturing systems. As an ISO 13485 and ISO 9001 certified manufacturer, Dirui continuously strives to streamline and improve our internal manufacturing systems in order to provide our partners and users the best products available. As a testament to our dedication to quality manufacturing, in April 2014 Dirui underwent and successfully passed a US FDA factory inspection. All of Dirui's products are CE certified, with select products such as our H series urinalysis strip and CS-6400 module clinical chemistry analyzer holding FDA certification.

With the coming launch of Dirui'schemoluminescence immunology analysis systems, Dirui will take one more step towards becoming a complete laboratory solution supplier. Whether you are a user, partner, or patient, Dirui's dedication to cutting edge products and impeccable quality will ensure effective products with reliable results. At Dirui we are dedicated innovators, we are quality manufacturers, we are reliable long-term partners. Dirui, a partner for life.



**DIRUI**

**DIRUI INDUSTRIAL CO.,LTD.**

3333 Yiju Street, New&High Tech. Development Zone Changchun, Jilin 130103, P.R.China

Tel: +86(431)81935331 85100409 Fax: +86(431)85172581 85083741

E-mail: [dirui@dirui.com.cn](mailto:dirui@dirui.com.cn) Http://[www.dirui.com.cn](http://www.dirui.com.cn)